

## SYNDERMATOTIC CATARACT IN PATIENTS WITH PSORIASIS

B. Wanscher and E. Vesterdal

*From the Department of Dermatology and Ophthalmology, The Finsen Institute, Copenhagen, Denmark*

**Abstract.** 266 consecutive in-patients, more than 10 years of age (mean age 24.7) and suffering from psoriasis have been examined with slit lamp and ophthalmoscope to determine the incidence of cataract among such patients. 188 (70%) had clear lenses. 66 (26%) presented some minute punctate opacities considered as physiological variations. Four had blue-dot cataract, and 6 had congenital or evolutionary small opacities at various sites in the lenses but without blurring of vision. Only one patient, aged 72, had crystalline cataract with slightly impaired vision. The conclusion is drawn that the incidence of cataract among patients with psoriasis does not exceed that in the normal population. Consequently, routine eye examinations for cataract are unnecessary in these patients.

**Key words:** Psoriasis; Cataract

Psoriasis is one of the most common of skin diseases. Associated eye manifestations in the form of blepharitis, conjunctivitis, and keratitis have often been noted (3, 6), whereas reports on complicating cataract are rarer (1, 5). Collier (1) observed eye lens anomalies in 9 out of 13 patients with psoriasis, a finding which motivated an investigation into such changes, in particular syndermatotic cataract, in a fairly large prospective series of consecutive in-patients.

Syndermatotic or dermatogenous cataract in patients with a skin disease is usually described as circumscribed, shield-shaped, often star-shaped opacities located in a thin subcapsular zone in the anterior cortex of the lens (4).

### MATERIAL AND METHODS

Within the period October 1963 to January 1972 all patients more than 10 years of age admitted with psoriasis to the dermatological unit were subjected to slit lamp examination and ophthalmoscopy in mydriasis for cataract by the same examiner in the eye clinic.

The material comprised 266 patients, whose age and sex

incidences are shown in Fig. 1. A total of 340 examinations were performed, 74 patients having been examined more than once within the period concerned or at follow-up in the autumn of 1974.

### RESULTS

Clear lenses were found in 188 of the 266 patients (70%). In 66 (26%) some minute punctate opacities were seen scattered in the lenses, though no shadows were revealed by transillumination. Some were located in the Y-shaped figure. In those patients seen more than once, no change was found in any case.

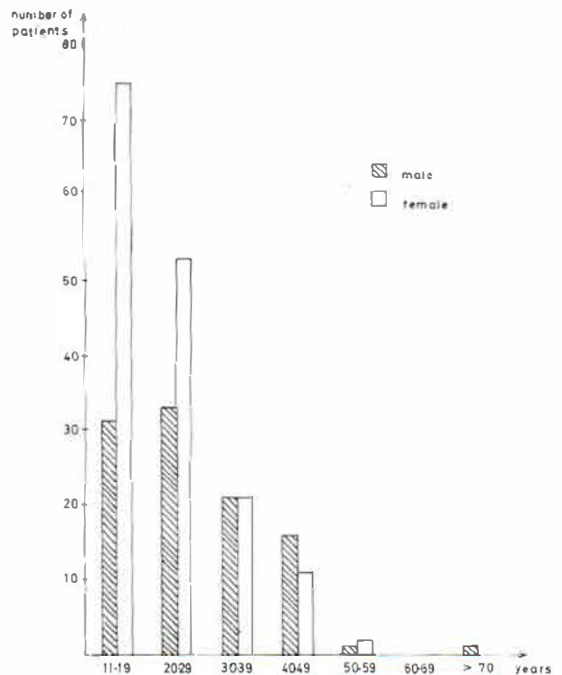


Fig. 1. Age and sex distribution of the 266 patients with psoriasis at their first examination.

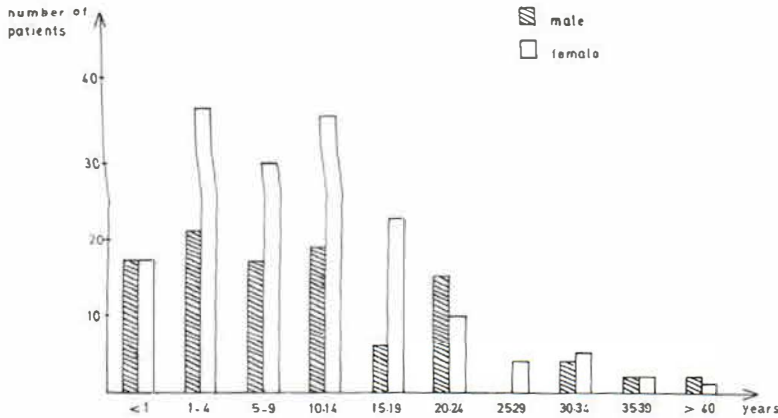


Fig. 2. Duration of psoriasis of the 266 patients at their first examination.

Four patients presented juvenile coerulean cataract (blue-dot cataract), and other forms of cataract were seen in 7 patients (Table 1). Six of these had congenital or evolutionary cataract, which was found unaltered at the follow-up examination. The opacity did not interfere with vision, which was 6/6 in all cases. Crystalline, needle-shaped cataract was located in all layers of the lenses in the seventh—and oldest—patient, but caused only mild impairment of vision (6/12).

To elucidate whether the development of syndermatotic cataract might be more closely related to the duration of the psoriasis disease than to the age of the patient, the duration of psoriasis at the first eye examination is shown in Fig. 2. It is seen that 175 patients had had psoriasis for more than 5

years, 128 for more than 10 years, and 3 for more than 40 years, giving an average duration of psoriasis of 10 years, ranging from a few months to 46 years. Nevertheless, no cases of syndermatotic cataract were found. Those patients examined more than once showed no alterations in the lenses. Observation covered periods of 1 year up to as much as 9 years.

#### DISCUSSION

The object of the present investigation was to confirm Collier's (1) observation of a high incidence of cataract among psoriasis patients. Other investigators, such as Manna & Jankowski (5), found no higher incidence of cataract among 100 psoriasis patients between the ages of 15 and 35 than among

Table 1. Lens opacities of the 266 patients with psoriasis

Pat. no.	Sex	Age	Psoriasis duration (years)	Diagnosis	Vision	Control	Years after 1st exam.	Comments
1	♀	43	23	Blue-dot cataract	6/6	—		
2	♂	19	3/4	Blue-dot cataract	6/6	—		
3	♀	22	10	Blue-dot cataract	6/6	—		
4	♀	41	31	Blue-dot cataract	6/6	+	3	Unchanged
5	♀	11	3	Posterior polar cataract (cong.) o.u.	6/6	—		
6	♀	19	14	Posterior polar cataract (cong.) o.u.	6/6	+	2	Unchanged
7	♂	26	10	Posterior polar cataract (cong.) o.d.	6/6	+	9	Unchanged
8	♂	47	22	Sutural cataract (cong.) o.u.	6/6	+	8	Unchanged
9	♂	13	2	Nuclear punctate cataract (cong.) o.d.	6/6	+	6	Unchanged
10	♀	28	13	Nuclear punctate cataract (cong.) o.u.	6/6	+	9	Unchanged
11	♂	72	3	Crystalline cataract needle shaped o.u.	6/12	—		Died 1 year later

100 controls aged between 19 and 27. Duke-Elder (2), in his *Textbook of Ophthalmology* from 1969, remarks that the occurrence of cataract in psoriasis patients is presumably incidental. A higher incidence of syndermatotic cataract among these patients is hardly to be expected, the finding being most often described as a complication of atopic dermatitis (*Prurigo Besnier*, *eczema allergicum*). The skin and lens manifestations are thought to be parallel and have the same pathogenesis.

Similarly, we did not find in our material a single case of cataract morphologically resembling the syndermatotic form.

Our findings are classifiable as physiological or mild congenital or evolutionary lens varieties, except, perhaps, for the case of crystalline cataract observed in the man aged 72, who had suffered from psoriasis for only 3 years.

The minute punctate lens opacities, which gave no shadows by transillumination, are to be considered as physiological varieties of no importance from a pathological aspect (8). Such varieties have most often come on at the foetal stage (2) and, as might be expected, were seen to have remained unchanged in the cases followed-up.

Four of our patients had blue-dot cataract, which is likewise regarded as a physiological variety (2). Our observations gave a lower incidence of this phenomenon than that stated in the literature, where Stöcklin (7) mentions up to 23% among children.

The other forms of cataract, found in 6 patients as posterior, polar and nuclear opacities, were all unchanged at follow-up examination, a fact which argues in favour of congenital or evolutionary cataract, characterized as being a stationary, non-progressive type (2, 8).

The fact that Collier (1) found cataract, diagnosed by him as syndermatotic or dermatogenous cataract, in 9 out of 13 patients with psoriasis is readily explainable by his having included the above-mentioned opacities in the lenses, which are not considered pathological.

### CONCLUSION

The series of patients under review must be considered large enough to be suitable for an estima-

tion of the incidence of cataract among psoriasis patients. No instance was found of cataract of syndermatotic morphology. 70% had clear lenses. In 26% we found scattered, minute, punctate opacities, giving no shadows by transillumination. These must be characterized as physiological variations. Of the remaining 11 patients (4%), 4 had blue-dot cataract, 3 posterior polar cataract, 1 sutural punctate cataract, 2 nuclear punctate cataract, and 1 crystalline needle-shaped cataract. Only the last-mentioned patient's vision was impaired. Follow-up examinations from 1 to 9 years later showed unaltered conditions in the patients examined.

The conclusions to be drawn on this basis are that the incidence of cataract is no higher among patients suffering from psoriasis than in a normal population, and that, accordingly, routine eye examination of psoriasis patients with a view to detecting cataract is unnecessary.

### REFERENCES

1. Collier, M. M.: Les modifications du cristallin chez les porteurs de psoriasis. *Bull Soc Ophtal (Paris)* 62: 59, 1962.
2. Duke-Elder, W. S.: Psoriasis. *Textbook of Ophthalmology*, vol. III, pp. 732, 744-745; vol. XI, pp. 148-149, 1969.
3. Kaldeck, R.: Ocular psoriasis. *Arch Derm Syph* 68: 44, 1953.
4. Kugelberg, I.: Juvenile Katarakt bei Dermosen. *Cataracta syndermatotica*. *Klin Mbl Augenheilk* 92: 484, 1934.
5. Manna, F. & Jankowski, W.: Biomicroscopic examination of the lens in psoriasis. *Klin Oczna* 36: 375, 1966.
6. Rook, A., Wilkinson, D. S. & Ebling, F. J. G.: *Textbook of Dermatology*, p. 1207. Blackwell Scientific Publications, Oxford, 1972.
7. Stöcklin, P.: Normvarianten der Morphologie der kindlichen Linse. v. Graefes *Arch Ophthalmol* 158: 346, 1957.
8. Vogt, A.: *Atlas der Spaltlampenmikroskopie des lebenden Auges*. Springer, Berlin, 1972.

Received June 11, 1975

B. Wanscher, M.D.  
Department of Dermatology  
Rigshospital  
Blegdamsvej 9  
DK-2100 Copenhagen  
Denmark