

## A CASE OF PIGMENTARY HAIR NAEVUS (BECKER)

*With a Specific Granulomatous Tissue Reaction of Possible Aetiological Significance*

Hans B. Svindland and Per Wetteland

*From the Bureau of Public Health, Department for Skin and Venereal Diseases, and the Department of Pathology, Trondheim Regional Hospital, Trondheim, Norway*

**Abstract.** A healthy 14-year-old Norwegian male developed a typical Becker's naevus on the left shoulder and upper scapular region, about six months after an intracutaneous BCG-vaccination in the homolateral junction of the shoulder and upper arm. The evolution of the lesion had been modified by exposure to sunlight during the following six years, with partial fading of the hyperpigmentation. Biopsies taken from the centre and from the edge of the lesion at the age of 19 years showed the usual histological picture seen in cases of Becker's naevus, but focal areas within the periphery showed a chronic granulomatous infiltrate of lupoid pattern in the dermis, mainly follicular and perifollicular in distribution. Acid-fast bacilli were not demonstrable in the sections, and in culture no tubercle bacilli were isolated from a central and histologically non-specific site. The implications of the histological findings are discussed, stressing the possibility that Becker's naevus may be a form of cutaneous tuberculosis caused by BCG or other mycobacteria of low virulence, precipitated by ultraviolet light and possibly modified by immunological factors.

**Key words:** Pigmentation disorders; Hypersensitivity, delayed

In 1949, Becker (1) described two cases of what was then believed to be an unusual combination of acquired melanosis and hypertrichosis. Both patients were young men, who had been exposed to severe sunburn, and the skin changes were confined to the right shoulder region. Histological examinations showed no naevus cells. Frain-Bell & Rook (3) reported 10 cases in 1957; all were strikingly similar to those seen by Becker. Copeman & Jones (2) reported on 24 patients in 1965; only 2 were females.

The clinical finding in Becker's naevus is a pigmented and hairy lesion. The condition occurs mainly in young men, and has been reported in all races (2). It is first noticed in adolescence and usually becomes conspicuous after exposure to sunlight. The initial change is an irregular macular pigmentation characteristically localized unilaterally on a shoulder or scapular region. The lesion extends irregularly

and attains the size of at least a palm. A coarse growth of hair occurs, not always corresponding to the pigmented area, but always appearing after the hyperpigmentation (1, 2, 3).

Lever (5) has classified this pigmentary hair naevus as an organic hamartoma characterized by differentiation of mature hair structures. The aetiology and the pathogenesis of Becker's naevus are, however, still obscure. We wish to present a clinically typical case, which revealed histological findings with possible implications for the aetiology of this peculiar dermatological disorder.

### CASE REPORT

A healthy 13-year-old Norwegian male was vaccinated intracutaneously with BCG (Swedish substrain) on his left shoulder in December 1964. Six months later he noticed marked pigmentation around the faded scar, and shortly afterwards a locally increased growth of hair. The Pirquet reaction became positive in February 1965, and still remains positive. The patient has never presented any pathological pulmonary findings. He is an athlete training usually with bare chest during the summer, and has noted local exacerbations with extension of the process following exposure to sunlight.

The patient was first seen by us in November 1970; he was then 19 years old, and presented a patch of hypertrichosis on the left shoulder, where the skin was smooth and hyperpigmented. The area of hyperpigmentation was more extensive than the hypertrichosis, and of markedly irregular outline (Figs. 1 and 2).

In May 1971, histological examination of a tissue specimen taken from the periphery of the lesion revealed the characteristic morphology of a chronic granulomatous dermatitis of lupoid pattern in focal areas. About 3 weeks later, another excised specimen, from the centre of the lesion, was examined histologically and bacteriologically.

*Histologically*, the first biopsy from the edge of the lesion (P-1934/71) revealed a somewhat hyperplastic epidermis, with slight to moderate acanthosis mostly characterized by

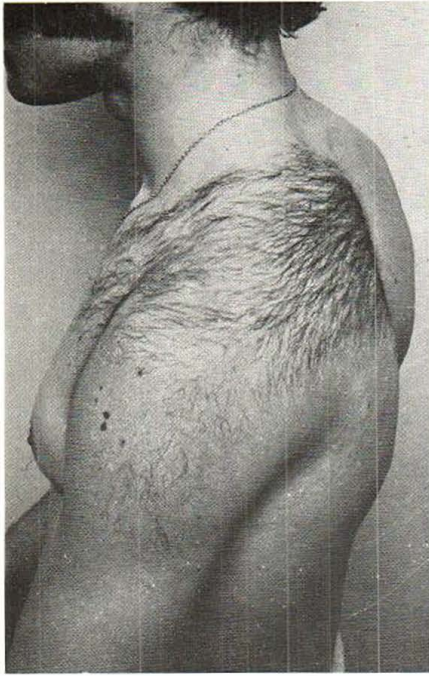


Fig. 1

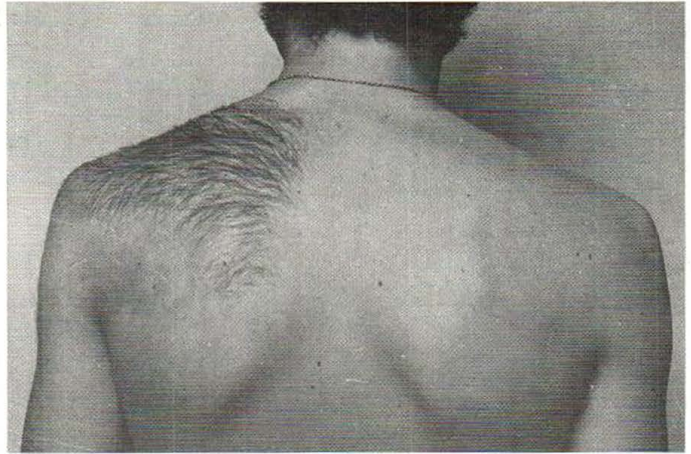


Fig. 2

*Figs. 1 and 2.* A Becker naevus with faded pigmentation but otherwise of typical clinical morphology and localization, present in a 19-year-old tuberculin-positive, healthy white male 6½ years after local BCG-vaccination in the left lower shoulder region. (1) Left lateral aspect. (2) Dorsal view.

regular elongation of the rete ridges (Fig. 3). There was slight focal hyperkeratosis, but there were no inclusion cysts within the epidermis. The basal layer presented numerous larger cells with clear cytoplasm, but hyperpigmentation was not conspicuous in any field and was largely absent. The upper dermis revealed a slight to moderate but widely distributed perivascular infiltrate of chronic inflammatory cells, mostly lymphocytes with some histiocytes.

There were no demonstrable naevus cells, intraepidermally or in the corium, and only very few melanophages were present in the upper dermis. The collagen bundles in the upper and notably the middle zone were swollen and somewhat hyalinized, but not to any marked extent (Fig. 3).

The hairs were largely devoid of any conspicuous degenerative or other pathological changes, but several follicular and perifollicular areas presented well demarcated and partly confluent chronic inflammatory infiltrates, with a definite granulomatous pattern (Fig. 4). These aggregates consisted of epithelioid cells, moderate numbers of lymphocytes and fairly numerous giant cells, some of foreign-body type (Fig. 5), though mainly of Langhans type with peripheral arrangement of the nuclei. Caseation necrosis was conspicuously absent, and the infiltrates consistently revealed a productive pattern with many fibroblasts in central and peripheral areas (Figs. 5–6).

Some perifollicular infiltrates within the upper dermis were accompanied by epidermal acanthosis with broad rete pegs. These granulomas caused slight elevation of the surface, giving the appearance of small papules, which were often seen in conjunction with local parakeratosis. The granulomas were mostly observed in relation to the hair follicles. Some

small ones were found interstitially, but not around the sweat glands or subcutaneously. They were not present in all sections of the tissue examined and were entirely lacking in the second specimen, removed from the centre of the lesion nearly 3 weeks later (P-2163/71).

All observed granulomas were without demonstrable acid-fast bacilli on Ziehl–Neelsen staining, and culture of the second biopsy specimen on Löwenstein–Jensen's medium did not reveal any growth of tubercle bacilli.

Tuberculostatic therapy in the form of INH and PAS was prescribed, but the patient did not complete treatment owing to dyspeptic side effects.

## DISCUSSION

We have presented a case of Becker's naevus on the left scapular region of a 19-year-old Caucasian male, and extending from near the midline to the shoulder and down the upper left arm. Histological examination revealed a chronic, granulomatous inflammation of definite lupoid pattern in peripheral areas, but not found in a biopsy from the centre of the lesion. The patient had been vaccinated in the left shoulder with BCG intracutaneously 6½ years previously, and about 6 months after the inoculation had noted marked local pigmentation of the skin, followed by hypertrichosis of the same area. The development of the lesion had been

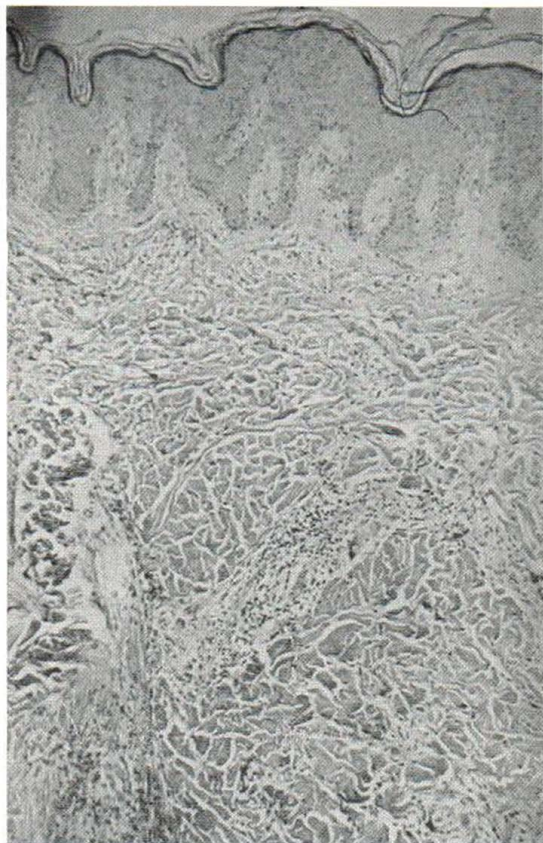


Fig. 3

*Figs. 3-6.* Photomicrographs of tissue specimen removed from a borderline area of the lesion 6½ years after BCG-vaccination (haematoxylin and erythrosin-safranin). (3) Slight to moderate acanthosis with comparatively slender rete ridges; no hyperpigmentation. Swollen and somewhat hyalinized collagen bundles in the middle dermal zone, with a patchy and largely non-specific infiltration of mainly lymphocytes ( $\times 80$ ). (4) Follicular and perifollicular granulomas of varying size and

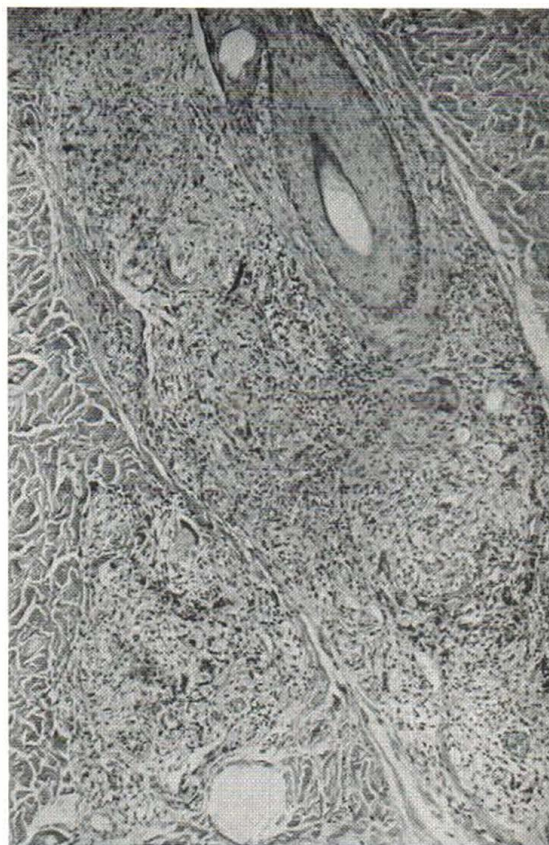

Fig. 4

partly confluent, of lupoid character with epithelioid cells, lymphocytes and giant cells of Langhan's and foreign-body type. No necrosis ( $\times 120$ ). (5) Detail from Fig. 4, revealing the predominant cell types. Productive tuberculoid pattern, with fibroblasts ( $\times 280$ ). (6) High-power view from another dermal area, showing an abundance of large fibroblasts, and a giant cell of Langhan's type in the upper middle field ( $\times 320$ ).

precipitated and later worsened by exposure to sunlight, and the patient thus presented a clinical picture characteristic of the pigmentary hair naevus (Becker).

When first seen by us, the pigmentation was fading but the hypertrichosis persisted, as in one of Becker's original cases (1) and in 3 of the 24 seen by Copeman & Jones (2); it was not observed in the series of Frain-Bell & Rook (3).

Histologically, some granulomata present in the upper dermis caused some elevation of the surface, and these infiltrates may well have presented as small papules, clinically. It is interesting in this connection that Frain-Bell & Rook (3) specifically mention the

presence of small perifollicular papules in 3 of their 10 cases, and it should also be recalled that the granulomatous tissue reaction was found mainly in relation to hair follicles in our patient. Histological examinations were performed in 5 of the 10 cases reported by Frain-Bell & Rook (3), but the authors did not subject the small papular lesions to histological investigation.

It is a possibility that the chronic granulomatous tissue reaction observed in our patient could have a non-infectious aetiology and represent some type of foreign-body reaction; there were, however, no doubly refractile particles on examination with polarized light.

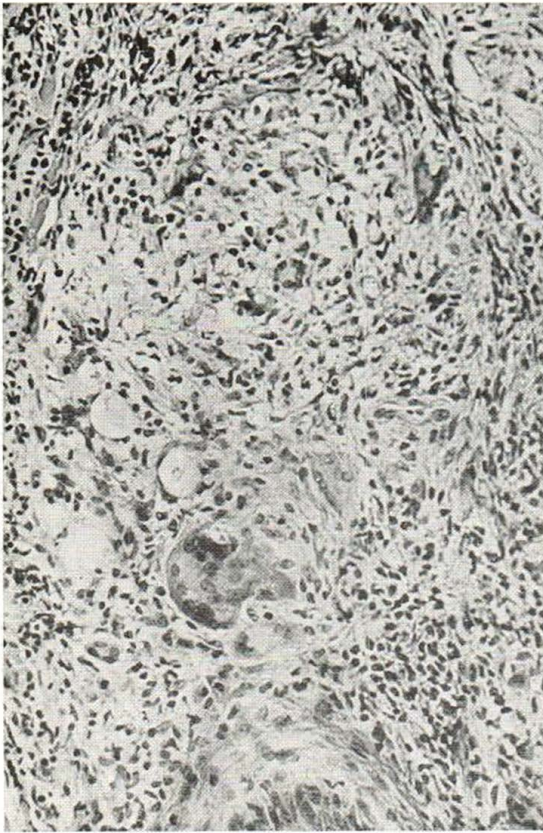


Fig. 5

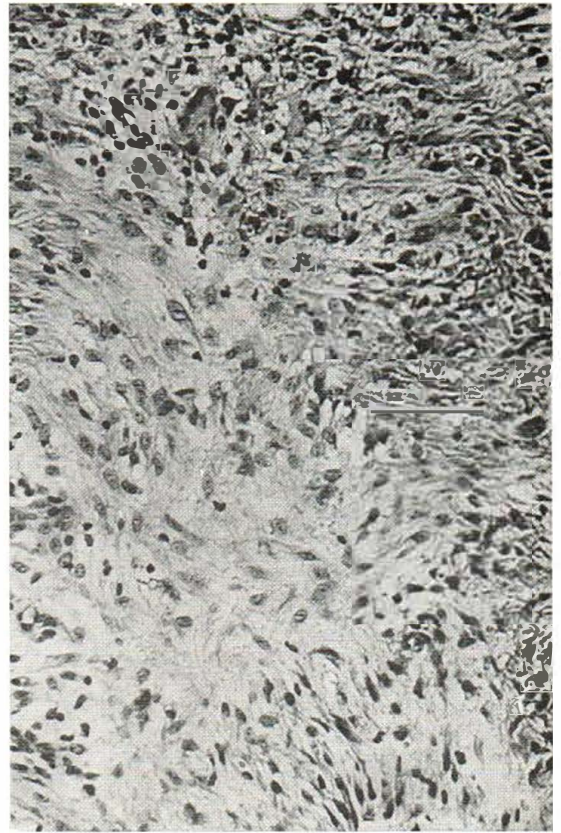


Fig. 6

It seems difficult in our case to exclude a causal relationship of the BCG-vaccination to the development of this peculiar cutaneous disorder. The initial changes occurred during the first summer after the vaccination. Tubercle bacilli were not demonstrable 6 years later, either in sections or on culture. This is, however, no argument against a tuberculous aetiology, as the present case was that of a lupoid histological pattern. It is well known that tubercle bacilli in lupus lesions can rarely be demonstrated by staining methods, and even culture and guinea pig inoculation are not always successful (5).

It is known that a prophylactic injection of BCG may be complicated by the regional development of lupus vulgaris, and a patient inoculated in the left shoulder and reported by Høvdig & Wetteland (4) presented a localization of this complication that was very similar to the usual distribution of Becker's naevus to the scapular region, shoulder and upper arm. This patient also revealed an extension of the tuberculous process near the interscapular midline (4); the lesion was slowly spreading and the central

part was atrophic, somewhat pigmented; numerous papules were seen, notably within the extending border.

It is also interesting in this connection that a BCG-vaccinated girl reported by Nagy et al. (6) developed lichen scrophulosorum with numerous papular lesions after 6 months. These papules first became evident around the vaccination site on the upper arm, with subsequent generalization. The histological pattern was very similar to that of the present case, with perifollicular arrangement of epithelioid granulomas with Langhans giant cells and no necrosis.

To the best of our knowledge, an epithelioid granulomatous reaction has not previously been demonstrated in a clinically typical case of Becker's naevus, and a tuberculous aetiology not even suspected. No mention is found in the literature of BCG-vaccination having been performed before the development of this pigmented hair naevus. However, the common unilateral localization of the disorder to shoulder and scapular regions, as well as the age distribution

of the patients, tend to suggest a connection with BCG-vaccination.

The present case as well as the naevi in the 2 original patients of Becker (1), the 10 reported by Frain-Bell & Rook (3), and 12 of the 24 seen by Copeman & Jones (2) were strikingly similar; being localized around the shoulder, anterior chest or scapular region. All were solitary lesions and at least the size of a palm (2). All these sites are compatible with the assumption of a local spread of BCG following immunization, although no mention is found of such vaccination having been performed in any of the previously reported cases.

Copeman & Jones (2) have, however, observed that the naevi in 12 of their cases were localized to the forearm or wrist, lower chest, forehead, cheek, neck, supraclavicular region, abdomen, buttock or shin. Moreover, the lesions were in some instances multiple and bilateral (2). It is obvious that these cases do not fit well with our hypothesis. However, accidental introduction into the skin of BCG or other mycobacteria of low virulence cannot be excluded as a possible cause.

Exposure to ultraviolet light seems to be a factor of obvious pathogenetic significance in the evolution of Becker's naevus, and the possibility cannot be excluded that the disorder might be due to a skin infection of low-virulent mycobacteria, precipitated

by actinic stimuli and probably modified by immunological factors.

Such a hypothesis would place Becker's naevus as another morphological variant among the many clinical forms of skin tuberculosis and tuberculids.

#### REFERENCES

1. Becker, S. W.: Concurrent melanosis and hypertrichosis in distribution of nevus unius lateris. *Arch Derm Syph* 60: 155, 1949.
2. Copeman, P. W. M. & Jones, E. W.: Pigmented hairy epidermal nevus (Becker). *Arch Dermatol* 92: 249, 1965.
3. Frain-Bell, W. & Rook, A.: Pigmented and hypertrichotic epidermal naevus. *Trans St John Hosp Derm Soc* 39: 51, 1957.
4. Høvdning, G. & Wetteland, P.: Lupus vulgaris efter vaksinasjon med BCG. (Lupus vulgaris following BCG-vaccination.) *Nord Med* 56: 948, 1956.
5. Lever, W. F.: *Histopathology of the Skin*, 4th ed., pp. 296-298, 534-537. J. B. Lippincott Co., Philadelphia-Toronto, 1967.
6. Nagy, E., Mészáros, C. & Somlyó, I.: Nach BCG-Vaccination aufgetretener Lichen scrophulosorum. *Z Haut Geschlechtskr* 47: 859, 1972.

*Received April 1, 1974*

H. B. Svindland, M.D.  
Department for Skin and Venereal Diseases  
Bureau of Public Health  
N-7000 Trondheim  
Norway