

SURGICAL TREATMENT OF PARONYCHIA GRANULOMATOSA HALLUCIS

B. Jemec and J. E. Andersson

From Department of Surgery D, University Hospital, Gentofte/Hellerup, Denmark

Abstract. Paronychia granulomatosa is a complication incident to unguis incarnatus; surgery for this complaint was performed on 26 patients with 52 granulomas. The operation was first described by Bartlett in 1937. The postoperative hospitalization was 3 days and the patients returned a week later to have the sutures removed. After the operation, ten remaining granulomas were observed of which 6 were cured by operation and 2 conservatively, leaving 2 under continuing conservative treatment (5 months and 1 month, respectively).

Key words: Caro luxurians hallucis; Pyogenic granuloma hallucis; Paronychia chronica hallucis; Unguis incarnatus complications; Granuloma paraungualis hallucis

Paronychia granulomatosa is a complication incident to unguis incarnatus, but it may also appear independently.

In the literature this complication is characterized as a rarity, but at the University Hospital in Gentofte 26 patients have been treated during the years 1971/1973.

In connection with the use of too-small shoes and after injudicious clipping of the nails, the pressure from below will push the soft part of the toe around the nail and cause ulceration, inflammation, and granuloma in persons who are so predisposed (5).

The treatment of unguis incarnatus can be divided into the operative and non-operative methods.

The non-operative methods are all based on the theory that unguis incarnatus is caused by the fact that the nail in these cases is more than normally curved. Consequently, all the non-operative methods force the nail edge upwards by using steel braces (10), by thinning of the central part of the nail and lifting the free edge by means of linen cloths (12) or elastic bandages (13).

The operative methods concentrate on (i) the matrix and the nail (4, 7, 11, 14, 15, 17, 18), or on (ii) the soft tissue around the nail (1, 2, 3, 6, 8, 9, 16,

19). In this group the method chosen is Bartlett's, which has been used in our material and will be described later.

MATERIAL

The material includes 26 patients in the age range 13 to 29 years. A total of 52 granulomas have been operated on. None of the patients had other deformities of the feet. All the patients had been treated unsuccessfully at least once before, almost without effect. Recurrence of 10 granulomas was treated in 6 cases by operation and 4 cases conservatively. After that there remained 2 granulomas, which are currently under treatment, for 1 and 4 months respectively.

TREATMENT

Before the operation the patients were treated with antibiotics and foot-baths. The operation was performed under conductive-anesthesia in sterile conditions, the skin being excised on the side of the toe as shown in Figs. 1 and 2 and sutured with silk. The granuloma was removed with a sharp spoon. We chose to hospitalize the patients for 3 days. On the first day the patient remained in bed with elevated feet. After the second day he was allowed to walk in slippers. On the third day the patient was discharged, and the sutures were removed ambulatorily after 7 days.

DISCUSSION

The fact that there are so many methods of treatment would seem to indicate that none of them is quite perfect, though Bartlett maintained that he had not observed any recurrences. In our material of 52 granulomas, there were 10 recurrences and after a second operation on 6 and 4 conservative treatments, only 2 granulomas remain, which result must be considered quite satisfactory. The method is a simple one; it can be carried out ambulatorily, requires a brief confinement to bed, and the cosmetic result is perfect, compared with the results of the




Fig. 1. Skin excision on the toe side.

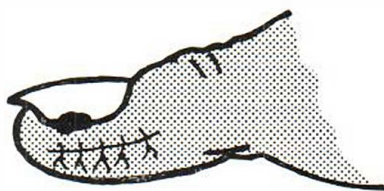


Fig. 2. Suturing and removing of granulation tissue with curette.

other operative methods, after which the patients are hampered by a deformed nail.

ACKNOWLEDGEMENT

My special thanks for linguistic advice are proffered to Hans Tang, M.A.

REFERENCES

1. Bartlett, R. W.: A conservative operation for the cure of the so-called ingrown toenail. *JAMA* 108: 2, 1257, 1937.
2. Bose, B.: A technique for excision of nail fold for ingrowing toenail. *Surg Gynecol Obstet* 132: 2, 511, 1971.
3. De Vries, H. L.: *Surgery of the Foot*. 2nd ed., pp. 211-215, 1965.
4. Fowler, A. W.: Excision of the germinal matrix: a unified treatment for embedded toenail and onychogryphosis. *Br J Surg* 45: 382, 1958.
5. Heifetz, C. J.: Ingrown toenail. *Am J Surg* 38: 298, 1937.
6. Herold, H. Z. & Daniel, D.: Radical wedge resection in the treatment of ingrowing toenail. *Int Surg* 49: 558, 1968.
7. Mogensen, P.: Ingrowing toenail. *Act Orth Scand* 42: 94, 1971.
8. Newman, R. W.: A simplified treatment of ingrown toenail. *Surg Gynecol Obstet* 89: 638, 1949.
9. Ney, G. C.: An operation for ingrowing toenails. *JAMA* 80: 374, 1923.
10. Rading, D.: Ortonyxi. *Läkartidn* 64-11: 1352, 1967.
11. Ross, W. R.: Treatment of the ingrown toenail and a new anesthetic method. *Surg Clin N Am* 49: 1499, 1969.
12. Strauch, G. D.: Toward the understanding of ingrown toenail. *Conn Med* 32: 743, 1968.
13. Søndergård, T. *Unguis incarnatus hallucis*. *Ugeskr Læg* 114: 1184, 1952.
14. Thompson, T. C. & Terwilliger, C.: The terminal syme operation for ingrown toenail. *Surg Clin N Am* 31: 575, 1951.
15. Townsend, A. C. & Scott, P. J.: Ingrowing toenail and onychogryphosis. *J Bone Joint Surg* 48: 354, 1966.
16. Vandebos, K. Q. & Bowers, W. F.: Ingrown toenail: A result of weight bearing on soft tissue. *U.S. Arm. Forc Med J* 10: 1168, 1959.
17. Winograd, A. M.: A modification in the technic of operation for ingrown toenail. *JAMA* 92: 229, 1929.
18. Zadik, F. R.: Obliteration of the nailbed of the great toe without shortening the terminal phalanx. *J Bone Joint Surg* 32: 66, 1950.
19. Zechek, G.: The fallacy of the ingrown nail. *Surg Gynecol Obstet* 131: 117, 1970.

Received October 22, 1974

B. Jemec, M.D.
Emilievej 10
DK-2920 Charlottenlund
Denmark