

EXTRAMAMMARY PAGET'S DISEASE

A case report

KNUT B. JACOBSEN AND ODD I. HAAVELSRUD

Extramammary Paget's disease is a dermatosis which pathologically and clinically resembles Paget's disease of the breast.

The disease occurs in regions with apocrine glands; most often in the anogenital area, seldom in the axilla. A few cases of the disease are described in the umbilicus, the mucous membrane of the mouth, in the nose, ear and in the gland of Moll, of the eyelid (15).

Women get the disease twice as often as men. Most of the patients are older persons, the average age being about 60 years. The youngest patient we have found in the literature was a 24-year-old woman with the lesion in the vulva (4).

Until 10 years ago extramammary Paget's disease was looked upon as a rare entity (7). During the past few years it has been reported in increasing numbers, including several cases reported by Scandinavian authors (4, 12, 13, 16, 17).

Since this condition still is of interest due to both clinical and pathological problems the following case is presented.

Case report: A 72-year-old man was admitted to the hospital with a genito-femoral lesion of the skin. The lesion started in the right groin and increased slowly in size for 10 years. It was oozing intermittently. In the last 1 1/2 years he had observed a papillary growth on the right thigh adjacent to the inguinal fold. There

had been considerable pain but no itching. The lesion had been treated for years as "eczema" or mycotic infection with a great number of topical agents. Except for chronic bronchitis he recalled no other illness. The patient was well nourished and in good general condition. Clinical examination showed the skin in the right inguinal fold and adjacent areas on the scrotum and the thigh to be "beefy-red" in colour. The surface was denuded, granular, and was partly covered with mucopurulent secretions. On the right thigh, just below the inguinal fold there was a red, papillary, soft, easy-bleeding vegetation, 0.7 cm elevated above the adjacent skin about 2×2 cm in size (Fig. 1). The skin in the pubic area and in the left inguinal fold with adjacent areas on thigh and scrotum was brown-red in colour. The surface was dry with moderate scaling. The total lesion measured 20×10 cm. It was regular in contour and the margins were sharply demarcated, but not thread-like. Blood cell count, urinalysis and blood sedimentation rates were within normal limits. Serologic tests for syphilis were negative. Radiographic examinations of chest and colon showed no tumor suspect abnormalities, and no blood was present in the stool. The *diagnosis*, extramammary Paget's disease, was first given on the third biopsy, and the lesion was removed surgically in two sessions.¹

Histology: The different parts varied in appearance. Figure 2 a and b showed the characteristic Paget cells in the epidermis; great cells with a bright, or light basophilic and finely granulated, vacuolated cytoplasm. The nuclei were partly hyperchromatic, partly poor in

¹ Department of Plastic and Reconstructive Surgery, Bergen, Norway. (Head: H. Schjelderup, M.D.)

chromatin. Many of them had one or two distinct nucleoli. Most of the nuclei were centrally located, a few seemed compressed to the periphery by the cytoplasm. Discernible prickles were not seen, and there were relatively few mitoses. Paget cells were also seen in the hair follicles, and possibly in the sweat gland ducts. Especially in the basic layer of the epidermis the cells had a tendency to cluster or "float" together.

In some places the cells formed nests, partly giving the impression of resting directly on the corium, and could readily be confused with naevus or melanoma cells (Fig. 3). Suprabasal spaces, occasionally with acantholytic cells, were a frequent phenomenon (Fig. 4). Figure 5 demonstrates papillary growth. Figure 6 shows a "psoriasislike" picture with downgrowth of the rete pegs, prolongation and broadening of dermal papillae covered by a thin epidermis. A varying degree of hyperkeratosis, partly follicular in type, and acanthosis was found in almost every specimen. A cellular infiltrate of plasma cells, lymphocytes and histiocytes was usually present in the dermis. In some areas the epidermis was infiltrated too, partly with polymorphonuclear leukocytes. In the skin removed from the left groin the specimen revealed a firm tumor, about 1 cm in diameter. The cut surface was grey-white in colour. There were macroscopic signs of infiltration of the dermis. Microscopically there was a diffuse infiltrating adenocarcinoma (Fig. 7), partly with distinct acini. The cells were cubical or cylindrical, with a few of the signet-ring type. Some areas with a more anaplastic appearance, exhibiting diffuse infiltration of single cells or clusters of cells, were found. In some of the sections apocrine glands were seen close to the tumor. However, at no point could the tumor be seen to arise from these glands. In all the sections from the epidermis as well as from the carcinoma a strong reaction for intraepithelial mucin was found (Alcian Blue-PAS).

Discussion

There is a variety of theories regarding the pathogenesis of Paget's disease of the skin. These theories may be classified in three groups.

1. The alteration in the epidermis represents a migration or metastasis from an underlying carcinoma.
2. The Paget cells arise primary in the epidermis.

3. The epidermis and the underlying adnexal structures may be involved together or separately.

Those favouring the first theory are of the opinion that there always has to be a carcinoma or a carcinomatous alteration of the underlying glandular tissue. But, contrary to what seems to be true for Paget's disease of the mammary glands (3), many authors claim that there are well defined cases of extramammary Paget's disease with localization to the epidermis only (8, 14). One of us has recently seen such a case in the anal region.

However, cases of extramammary Paget's disease localized to the anogenital region with involvement of the epidermis concomitant with adenocarcinoma of the rectum or mucinous carcinoma of the urethra or carcinoma of the breast have led some authors to assume a multicentric and autochthonous origin of the disease (8).

Extramammary Paget's disease is only described in locations with apocrine glands. These glands develop from the same epithelial germ as do the hair follicles and the sebaceous glands. They open to the hair follicle or on the free surface of the epidermis. There are therefore obvious reasons to presume that apocrine cells or their precursors normally located in the epidermis can be affected in the same manner as the apocrine glands themselves.

The same authors (8) call attention to the fact that part of the skin of anus, perineum and genitalia is of entodermal origin. Histochemically they found mucinous material in cells of the transitional epithelium of the anorectal junction and cells lining anal ducts and glands similar to that found in apocrine glands of the genital region. Ontogenetically and histochemically we may have to deal with the same sort of cells. An unknown carcinogenic stimulus may therefore affect the apocrine structures, the dermis, the glands of the rectum and urethra with an autochthonous and multicentric effect.

Like mammary glands, the apocrine glands are under influence of hormones. They begin functioning at puberty, with

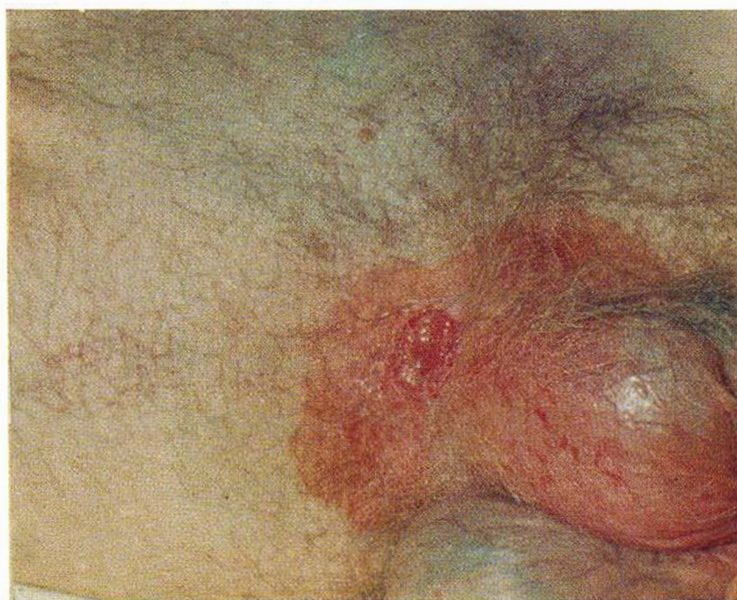

Fig. 1. Picture from the right groin and scrotum showing Paget's disease with a papillary growth, just below the inguinal fold.

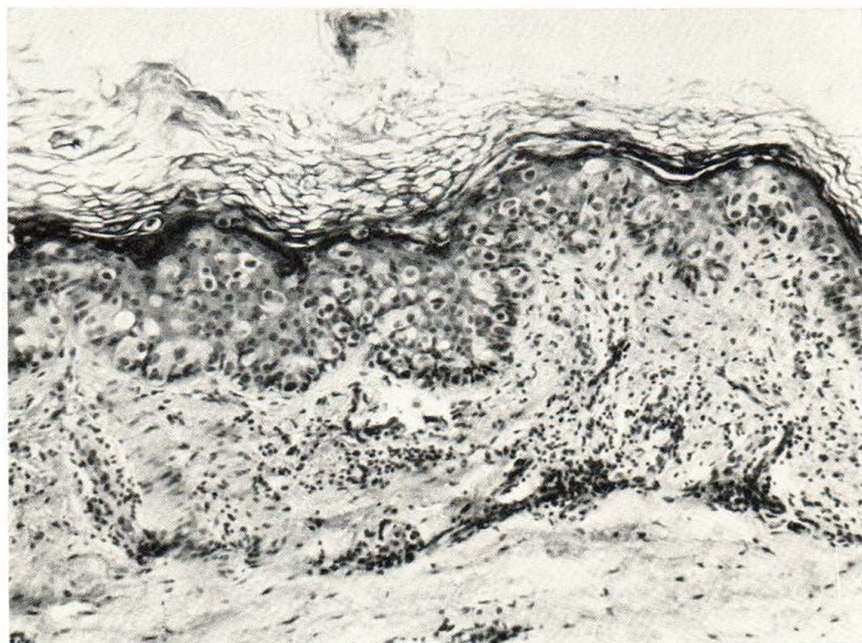


Fig. 2 a. Section from the lesion in fig. 1 with typical Paget cells. (H+E \times 150)

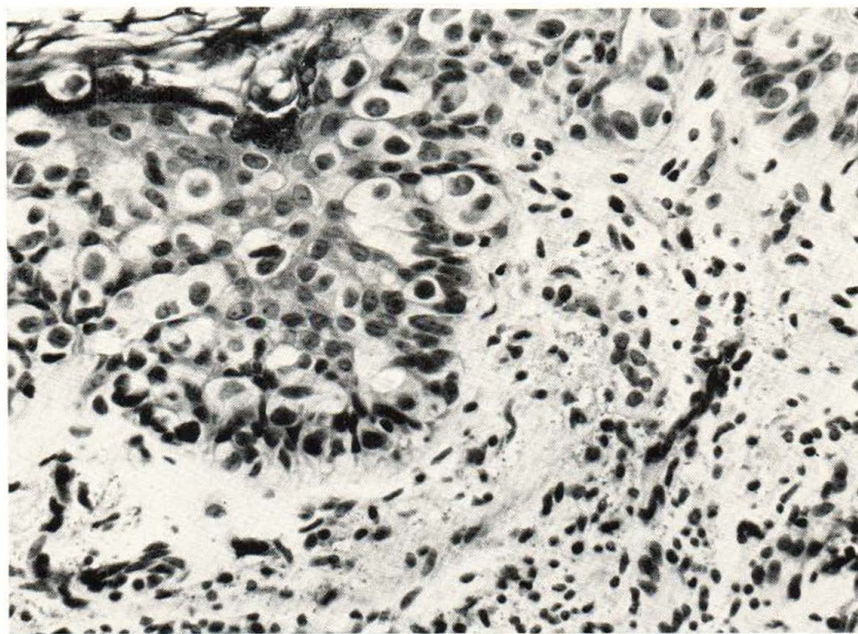


Fig. 2 b. Higher power view from the same lesion as in fig. 2 a. (H+E \times 370)

decreasing or ceasing activity at the end of the reproductive life (1).

In our case the disease was at first observed in the right groin, far away from

the adnexal tumor which was found 10 years later in the left groin. According to the first theory, the first manifestation should represent a metastasis from the

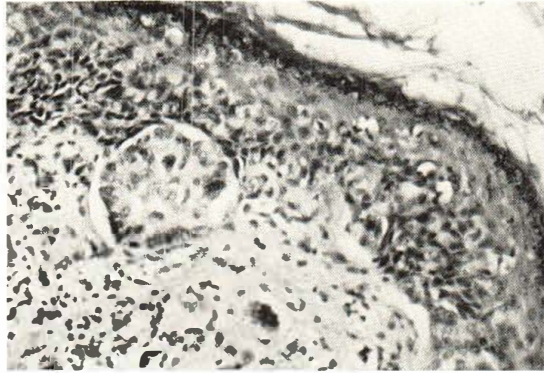


Fig. 3. Section of area with Paget cells forming nests of cells resting directly on the corium. (H+E×150)

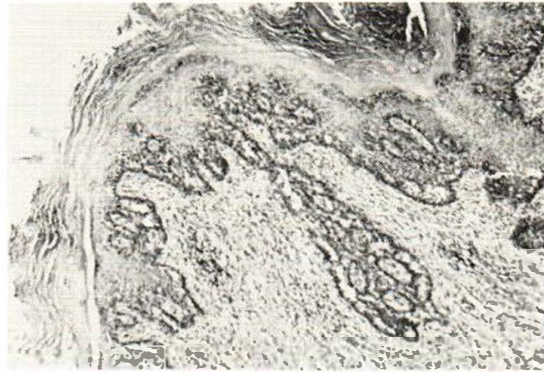

Fig. 4. Section from the lesion in fig. 1 showing formation of suprabasal spaces in Paget's disease. (H+E×35)

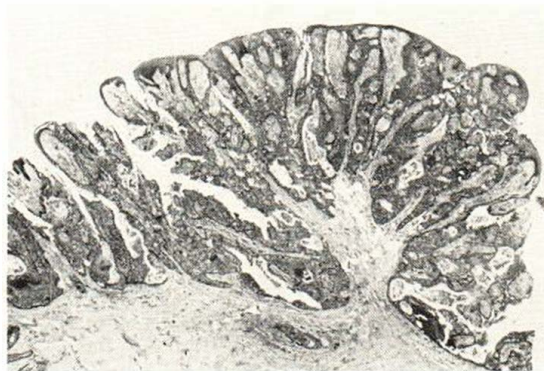

Fig. 5. Section from the papillary growth in the right groin as shown in fig. 1. (H+E×8)

tumor. The further growth in that case is either an intraepidermal spread from the first manifestation or a metastasis which each time comes nearer to the primary

tumor. It would be easier to understand that the alterations from the very beginning represented a carcinoma *in situ* with secondary infiltration of the dermis. The third

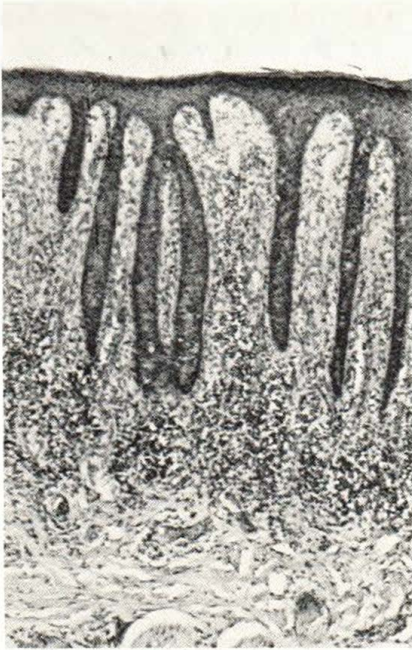


Fig. 6. Section of the same lesion as shown in fig. 1, from an area with "psoriasislike" formation. (H+E \times 35)

mentioned theory is of course also a possibility.

It has been postulated that Paget cells

do not represent a malignant cell, but an altered or degenerated cell. In disagreement with this view these cells are able to spread rapidly in tissue culture (2).

Clinically the disease is described as erythematous and scaling, with secondary weeping, oozing and eczematisation. Contrary to eczema, the borders of the lesion usually remain sharply defined (15). Many of the patients have itching, some have pain. Papillary and leukoplakialike formations, ulcers and bleeding may give the lesion such a varied appearance that the diagnosis cannot be based on the clinical picture alone (4).

The diagnosis is based on the microscopical finding of Paget cells in the epidermis. Miescher (14), calls attention to the fact that especially in the center of larger lesions, nonspecific alterations can be found which tend to impede the diagnosis. These circumstances are best illustrated in the work of Helwig and Graham (8) in their clinico-pathological study of 40 cases of anogenital Paget's disease:

Of the 37 patients from whom data were available, the lesions varied in size from 0.4 to 12 cm in diameter; the medium was

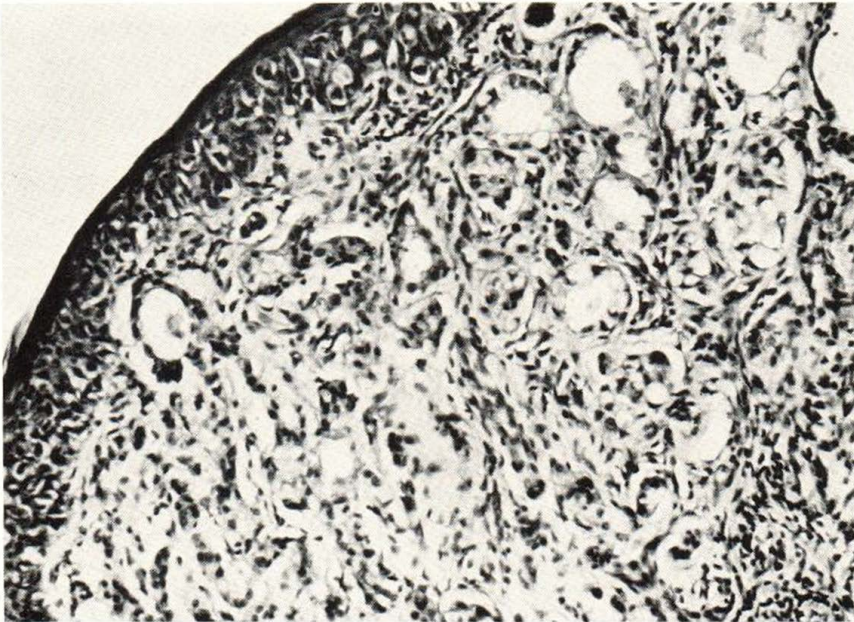


Fig. 7. Section of lesion in the left groin from the same patient as shown in fig. 1 with underlying infiltrating adnexal carcinoma. (H+E \times 9)

3 cm. Clinically only 2 of the 40 lesions were diagnosed as extramammary Paget's disease. One half had "benign" diagnosis, the other half showed some variety of premalignancy or carcinoma.

Prior to the first biopsy, excision or treatment, the duration of the lesion varied from 1 month to 31 years.

The initial pathological diagnosis was extramammary Paget's disease in 16 cases, melanoma or junctional naevus in 8, some variety of carcinoma in 14, Darier's disease in 1, and no diagnosis in 1 case.

Pathologically, the main problem is to differentiate extramammary Paget's disease from malignant melanoma, Bowen's disease, and occasionally from erythroplasia of Queyrat. This is especially true for the malignant melanoma (2, 6, 11, 13).

Extramammary Paget's disease can be differentiated from the mentioned diseases because the Paget cells contain mucin (6, 9, 10, 13). This can be shown with a relatively nonspecific reaction such as mucicarmine—Mayer, or by histochemical demonstration of acid mucopolysaccharides with basic copperphthalocyanins; for example Alcian Blue. Of these two methods the staining with mucicarmine is the least sensitive.

Helwig and Graham (8) found that the mucicarmine staining was negative in Bowen's disease and melanoma, and even in a few cases of extramammary Paget's disease. However, they usually found some Paget cells sensitive to mucicarmine in most of their cases of the latter disease. These authors also found some melanomas positive with Alcian Blue, but pointed out that others were unable to verify this finding. They therefore based their diagnosis on Gomori's aldehyde fuchsin reaction which is only positive in extramammary Paget's disease.

All the slides in our case were stained with Gomori's aldehyde fuchsin and gave a positive reaction which, however, was weaker than the reaction obtained with Alcian Blue.

As a control, eight cases of Bowen's disease and eight cases of malignant melanoma were stained with Alcian Blue. None of

them showed intraepithelial mucin. However, in the melanomas the connective tissue around groups of melanoma cells often was strongly positive. This is in accordance with our earlier experience.

Therefore, we do not believe it should be necessary for diagnostic security to introduce a special staining method in addition to a routine method used in many laboratories, and which we believe is adequate to ascertain the diagnosis of extramammary Paget's disease.

Histologic distinction between extramammary Paget's disease with or without apocrine gland involvement and adenocarcinomas containing mucin with metastasis to the skin, may be another problem entirely (15)

Demonstration of melanin seems to be of less value as the melanomas may be amelanotic, and many authors also have found melanin pigment in the Paget cells (8, 13).

In our slides there is possibly a weak positive reaction with the method of Fontana-Masson. However, it is pointed out that the apocrine glands contain lipofuscin which also reduces silver salts. Confusion can be avoided by the use of hypochlorite or chlordiodydissolution (5).

If proper reagents are available the dopa reaction may be of importance.

Helwig and Graham (8), who analysed their material statistically, generally found the prognosis to be somewhat better in Bowen's disease than in anogenital Paget's disease. The median survival time for patients with anogenital Paget's disease was about seven years after the first biopsy. In the cases with underlying adnexal carcinoma or adjacent internal carcinoma, the prognosis was much worse; as the median survival time then was only one third of that of the whole material. Fundamentally the therapy is surgical, possibly supplemented later with x-ray or radiumtreatment (8,16).

SUMMARY

A case of extramammary Paget's disease with adenocarcinoma in the dermis is de-

scribed. The authors share the view that diagnosis is difficult based on the clinical picture alone. However, this disease should be borne in mind when obscure eruptions occur in regions with apocrine glands and especially if such lesions prove resistant to topical therapy.

In wide-spread lesions the histologic picture may not be distinct. The importance of demonstrating acid mucopolysaccharides with special stains, such as Alcian Blue is stressed. Considering the course of the disease in the presented case it is not likely that the Paget cells in the epidermis represent metastasis or migration from an underlying carcinoma.

REFERENCES

1. Bargmann, W.: *Histologie und Mikroskopische Anatomie des Menschen, Vol. II*, p. 412, 413, Stuttgart, 1951.
2. Becker, S. W., Jr., Brennan, B. and Weichselbaum, P. K.: Genital Paget's disease. *Arch. Derm.* 82: 857, 1960.
3. Bennet, W. A.: *Pathologic study of Paget's disease of the nipple*. Masters Thesis, Graduate School, University of Minnesota, 1943.
4. Berggren, O. G. A. and Bogg, A.: Extramammary localization of Paget's disease. *Acta dermat.-venereol.* 42: 72, 1962.
5. Burk, H. C.: *Histologische Technik*, p. 118. Stuttgart, 1966.
6. Domankos, A.: Extramammary Paget's disease. *Arch. Derm.* 94: 97, 1966.
7. Greeley, P. W. and Curtin, J. W.: Extramammary Paget's disease of the skin. *J. Amer. med. Ass.* 155: 1054, 1954.
8. Helwig, E. G. and Graham, F. H.: Anogenital (extramammary) Paget's disease. *Cancer (Philad.)* 16: 387, 1963.
9. Hertig, A. T. and Gore, H.: *Tumors of the female sex organs*. Armed Forces Institute of Pathology, sect. 9, fasc. 33, Part 2, p. 15. Washington, D.C., 1960.
10. Lund, H. Z.: *Tumors of the skin*. Atlas of Tumor Pathology. Armed Forces Institute of Pathology, sect. 1, fasc. 2, p. 265. Washington, D.C., 1957.
11. Lund, H. Z. and Kraus, J. M.: *Melanotic Tumors of the Skin*. Armed Forces Institute of Pathology, p. 100. Washington, D.C., 1962.
12. Lübschitz, K.: Paget's disease on the nipple. *Acta radiol. (Stockh.)* 25: 127, 1944.
13. Madsen, A.: Paget's disease of the vulva. *Acta dermat.-venereol.* 45: 84, 1965.
14. Miescher, G.: Zwei Fälle von vegetierendem Morbus Paget der Genitalregion. (Two cases of vegetating Paget's disease of the genital region). *Dermatologica (Basel)* 108: 309, 1954.
15. Montgomery, H.: *Dermatopathology, Vol. II*, p. 1007. New York, Evanston, and London, 1967.
16. Muri, O. Jr.: Paget's disease of the vulva. *Acta path. microbiol. scand.* 49: 401, 1960.
17. Sonck, C. E.: Ein Fall von Paget'scher Erkrankung der Vulva. (One case of Paget's disease of the vulva). *Dermatologica (Basel)* 102: 151, 1951.