

## Pigmented Macule on the Sole Probably Caused by a Stink Bug

Naomi TANI, Nanako YAMADA and Osamu YAMAMOTO

Division of Dermatology, Department of Medicine of Sensory and Motor Organs, Faculty of Medicine, Tottori University, 86 Nishi-cho, Yonago, Tottori 683-8504, Japan. E-mail: taninaomi@tottori-u.ac.jp

Accepted Oct 30, 2023; published Dec 11, 2023

Acta Derm Venereol 2023; 103: adv19641. DOI: 10.2340/actadv.v103.19641

We report here a case of a pigmented macule on the sole of the foot with dermoscopic and histopathological findings, which was probably caused by a stink bug.

### CASE REPORT

A 6-year-old female was referred to our department with a 1-month history of a reddish-brown spot on her right sole. She had noticed a red macule on her right sole 1 month prior to presentation, and had pain when walking. Although she was treated with a topical steroid at a local clinic, the skin lesion enlarged gradually and the colour became reddish brown. Physical examination revealed a reddish-brown, firm macule 9×5 mm in diameter with circular scales on the right sole (Fig. 1A, B). Dermoscopic examination revealed homogeneous yellow-orange pigmentation involving both the surface ridges and the furrows (Fig. 1C). Histopathology of a biopsied specimen showed compact hyperparakeratosis. The horny layer showed eosinophilic change with an uneven and mottled staining pattern. Hypergranulosis and regular acanthosis with rete ridge elongation were seen. Dense band-like lymphocyte infiltration in the papillary dermis was observed (Fig. 2A). Necrotic keratinocytes and lymphocyte exocytosis were also present in the epidermis. Infiltration of lymphocytes was seen around eccrine glands. The horny cells had become partially transparent as well as showing a round-to-irregularly shaped eosinophilic homogeneous change (Fig. 2B). Brownish small pigment granules were observed in the horny layer (Fig. 2C).

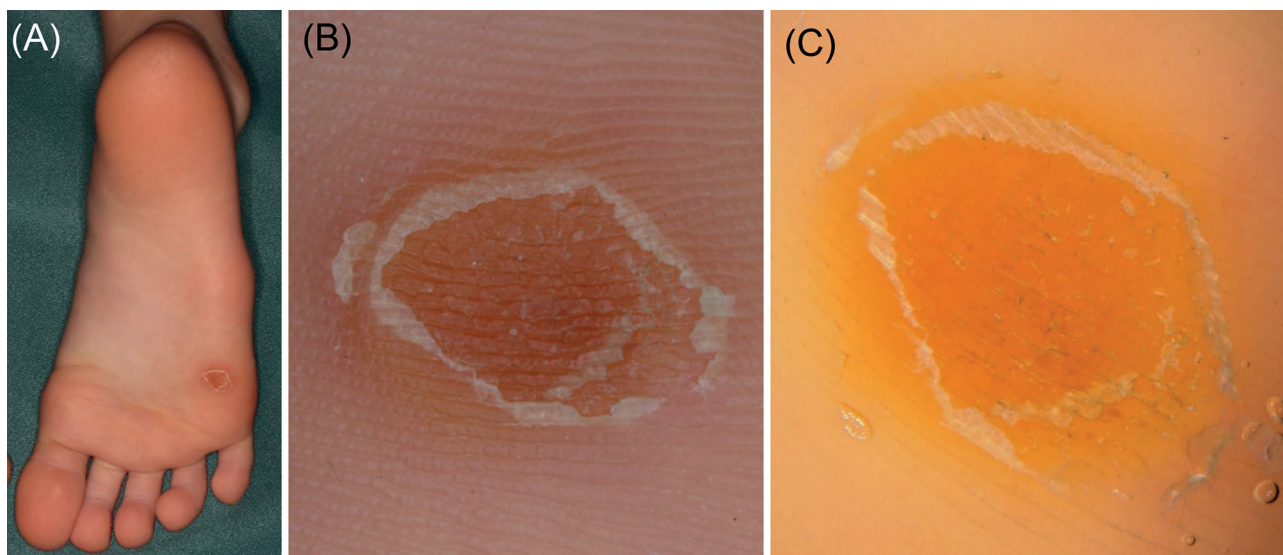
A further detailed interview revealed that she had noticed stink bugs (Insecta: Heteroptera: Pentatomidae) in her house and that she usually walked barefoot in the house. Based on the above, we made a diagnosis of pigmented macule probably caused by a stink

bug. The plantar pigmentation disappeared spontaneously within 1 week after the biopsy.

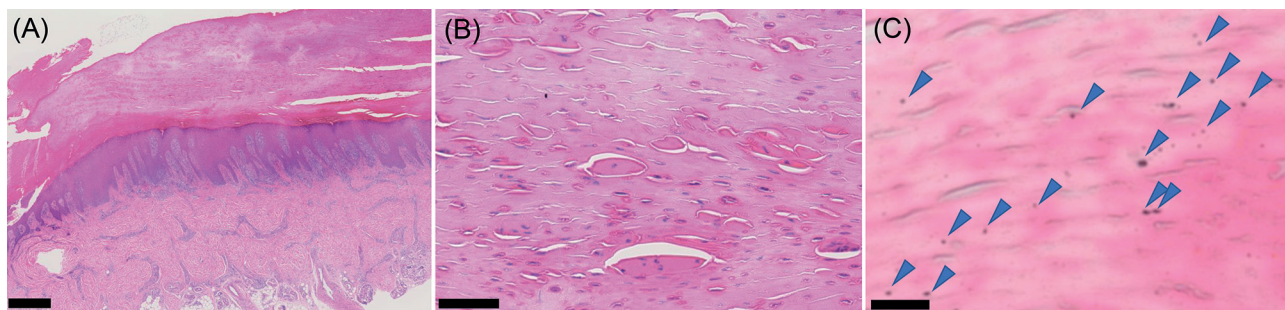
### DISCUSSION

There have been several reports of skin symptoms on the cheeks, neck, and proximal arm/axilla caused by stink bugs (1–3). Stink bugs excrete a substance containing 2 aldehydes from its stink glands, located on its abdomen. These 2 aldehydes, *trans*-2-decenal and *trans*-2-octenal, cause irritant contact dermatitis (3). The characteristics of skin symptoms are swelling, erythema, vesiculation, and burning sensation (2). Histopathology of an erythematous plaque on the cervical area provoked by *Antiteuchus mixtus* showed a moderate, infiltrative, inflammatory reaction with lymphocytes in the superficial dermis (2). Anderson reported a case of irritant contact dermatitis in the proximal arm/axilla region, which was red-orange in colour, caused by a brown marmorated stink bug (3). They observed that a crushed stink bug released an orange substance (3).

On the other hand, pigment spots on the soles caused by stink bugs have been reported to be asymptomatic, orange or black-to-brown in colour, and disappear spontaneously within a few weeks (4–6). Izutani conducted a test in which subjects stepped on a stink bug on paper. He found that orange pigmented spots appeared within



**Fig. 1.** (A, B) Clinical manifestation at first visit. A reddish-brown macule 9×5 mm in diameter with circular scales was observed on the right sole. (C) Dermoscopic examination at first visit. Homogeneous yellow-orange pigmentation was observed involving both the surface ridges and the surface furrows.



**Fig. 2. Histopathological findings.** (A) Compact hyperparakeratosis and regular acanthosis with rete ridge elongation. Dense infiltration of lymphocytes was observed in the papillary dermis and around eccrine glands (haematoxylin and eosin (H&E) staining, bar=500  $\mu$ m). (B) The horny cells had become partially transparent as well as showing round-to-irregularly shaped eosinophilic homogeneous change (H&E staining, bar = 50  $\mu$ m). (C) Brownish small pigment granules were observed in the horny layer (arrows) (H&E staining, bar = 10  $\mu$ m).

5 min of stepping on the stink bug and completely disappeared within 2 weeks (6). The principal differential diagnosis of this case includes exogenous pigmentation caused by a millipede. Millipedes release toxic chemicals (cyanide and quinones) as a defence mechanism and can cause skin and mucous membrane inflammation and hyperpigmentation (7). The characteristics of pigmentation caused by a millipede are sudden appearance of a black or brownish spot, usually on the feet, along with local pain, burning sensation and paraesthesia (7). Pigmentation disappears in a few weeks or months (8). In the current case, a pigmented macule appeared suddenly, as in the case of a pigmented spot caused by a millipede. However, the patient had only noticed stink bugs in her house, and we therefore made a diagnosis of pigmented macule probably caused by a stink bug. One case with histopathological findings of pigmented spots on the plantar arch caused by stink bugs has been reported, and it was reported that the cornified layers were stained by basophilic pigment predominately under the surface ridges and there was no inflammatory infiltrate (5). In contrast, in the current case, eosinophilic homogeneous changes in the horny layers with a mottled staining pattern were observed and there was a dense inflammatory infiltrate in the dermis associated with necrotic keratinocytes and exocytosis of lymphocytes in the epidermis. At higher magnification, small brownish pigment granules were observed in the horny layer. Izutani speculated that the orange pigment spots do not fade even if wiped with alcohol because the aldehyde group in the orange substance released by crushed stink bugs reacted with amino group of corneocytes, resulting in the formation of cross-links, and the orange substance was fixed to corneocytes (6). The small pigment granules in the stratum corneum in the current case may correspond to changes in stratum corneum cells caused by the orange material released

by a stink bug. In addition, unlike previously reported cases, the current case showed dense inflammatory cell infiltration and a firm pigment spot distributed in both the surface ridges and the furrows. The current patient initially had pain, which took 5 weeks to resolve, which is longer than in previously reported cases (4, 6). These peculiar clinical and pathological findings may be due to strong pressure exerted on a stink bug or prolonged contact with a stink bug.

The possibility of stink bug contact should be considered in cases of a characteristic yellow-brown spot and small pigment granules in the horny layer.

## REFERENCES

1. Jones SK, Strong L, Burton JL. Perioral blisters in a bug-biting baby. *Br J Dermatol* 1988; 119: 121–125.
2. Haddad V Jr, Cardoso J, Moraes R. Skin lesions caused by stink bugs (Insecta: Heteroptera: Pentatomidae): first report of dermatological injuries in humans. *Wilderness Environ Med* 2002; 13: 48–50.
3. Anderson BE, Miller JJ, Adams DR. Irritant contact dermatitis to the brown marmorated stink bug, *Halyomorpha halys*. *Dermatitis* 2012; 23: 170–172.
4. Nomura Y, Noborio R, Kiyohara T. Black-to-brown macules, mainly involving the surface ridges on the plantar arch, caused by a stink bug: the first biopsied case demonstrating a pigmented cornified layer. *J Dermatol* 2019; 46: e364–e365.
5. Uhara H, Sano T, Miyake T, Okuyama R. Orange pigmentation spots on the sole may be from a stink bug. *J Dermatol* 2016; 43: 1247–1248.
6. Izutani K. Orange color pigmented spot on the sole caused by Heteropterans. *Japanese J Clin Dermatol (Japanese)* 2014; 68: 851–856.
7. Smaniotto MF, Batzner CN, Rovere RK, de Lima AS. Exogenous pigmentation of skin and nail caused by a millipede in a patient with plantar psoriasis. *Australas J Dermatol* 2018; 59: e225–e227.
8. Sampaio FM, Valviesse VR, Lyra-da-Silva JO, Mesquita EC, Brandão LG, do Valle AC. Pain and hyperpigmentation of the toes: a quiz. Hyperpigmentation of the toes caused by millipedes. *Acta Derm Venereol* 2014; 94: 253–254.