

Supplementary Figures have been published as submitted. They have not been copyedited, typeset or checked for scientific content by Acta Dermato-Venereologica

Fig. S1. Relative proportions of affected sites outside the scalp (%).

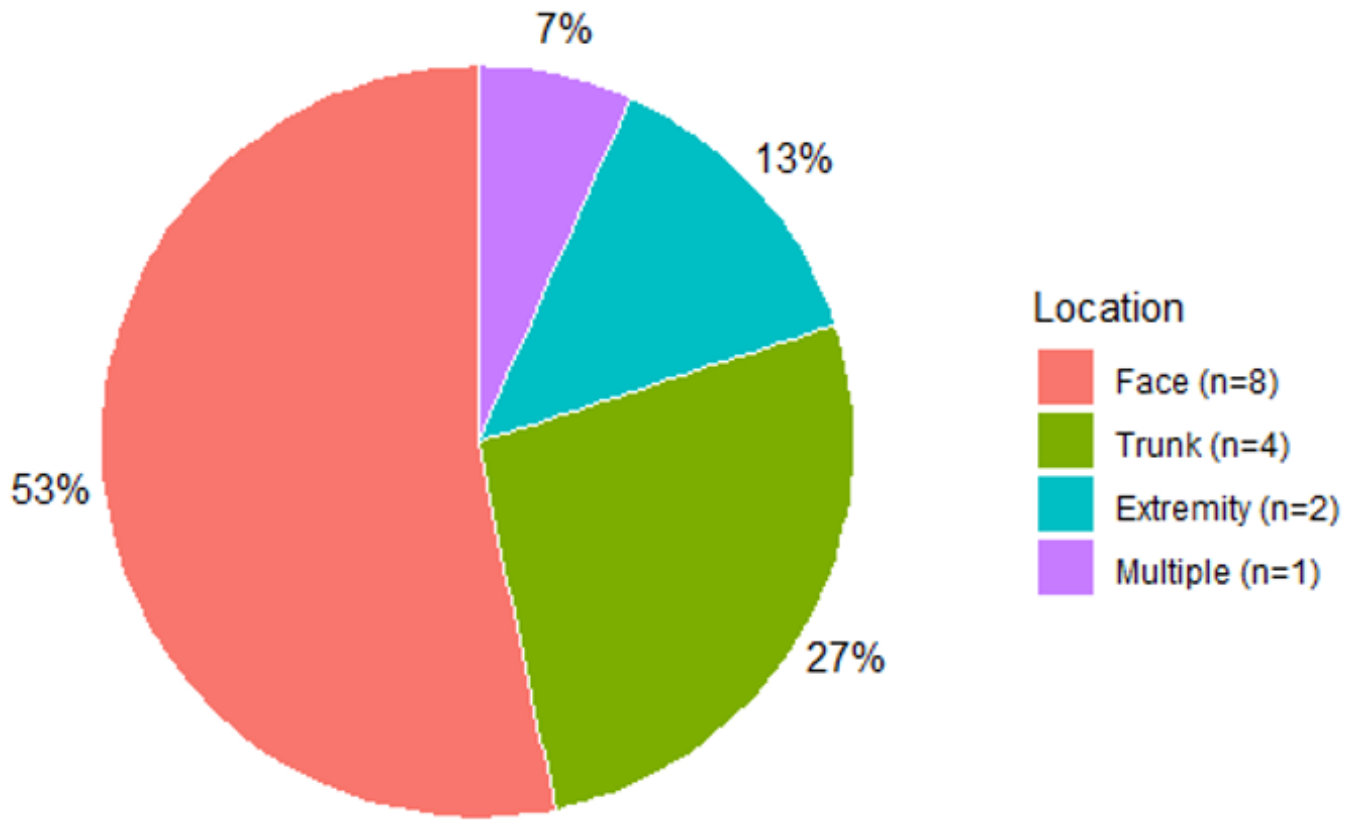


Fig. S2. Frontal scalp vitiligo before treatment (left). Partial improvement after 12 months (middle) and excellent improvement after 24 months (right) by applying topical tacrolimus twice daily and treatment with an excimer laser twice weekly.

