

Propylthiouracil-induced Alopecia Accompanying Hypohidrosis and Onychomadesis

Nozomi YANAGIDA[#], Shunsuke TAKAHAGI^{##}, Akio TANAKA and Michihiro HIDE

Department of Dermatology, Institute of Biomedical & Health Sciences, Hiroshima University, 1-2-3 Kasumi, Minami-ku, Hiroshima 734-8551, Japan. *E-mail: shunstk@hiroshima-u.ac.jp

[#]These authors contributed equally to this work.

Accepted Aug 16, 2022; Epub ahead of print Aug 16, 2022

Acta Derm Venereol 2022; 102: adv00763. DOI: 10.2340/actadv.v102.2690

Drug-induced alopecia areata (D-AA) is mainly caused by molecular-targeted drugs including monoclonal antibodies to tumour necrosis factor (TNF)- α and interleukin (IL)-4 receptor, and immune checkpoint inhibitors (1–3). A few drugs with other mechanisms of action also elicit AA-like hair loss (4). However, there have been no reports of D-AA due to antithyroid agents, and no evidence of D-AA associated with decreased perspiration. We report here a case of propylthiouracil (PTU)-induced AA accompanying generalized hypohidrosis and onychomadesis, evaluated by a thermoregulatory sweat test (TST).

CASE REPORT

A 41-year-old Japanese woman presented with purpuric erythema on her lower legs during tapering of prednisolone for IgA nephropathy. A month later, she found a patch of alopecia on the scalp, which evolved to almost total hair loss from her scalp (Fig. 1a). In addition, she noticed severe dry skin on the trunk and extremities, along with hyperthermia and heatstroke due to reduced sweating. Onychomadesis with periungual erythema and scaling were also found on her fingers and toes (Fig. 1b). PTU had been given for treatment of Graves' disease for 4 months before the onset of these symptoms. A lymphocyte transformation test (LTT) performed after stopping corticosteroid revealed her positive reactivity to PTU (stimulation index 3.3; normal limit <1.8). Trichoscopy showed sparse vellus hairs, and broken hairs as well as sharply bent hair shafts (Fig. 1c). Physical, neurological and laboratory tests suggested overactive thyroid function even on PTU, but no other remarkable findings related to endocrine disorders, collagen diseases and autonomic failure, which might cause hypohidrosis. A TST revealed generalized hypohidrosis on 61% of the total body surface area (Fig. 1d). Histology of a scalp biopsy showed dense CD3⁺ T lymphocyte infiltration and damage to anagen hair bulbs (Fig. 2a, b). CD3⁺ T cells expressed predominantly CD4 compared with CD8 with the absence of Foxp3 expression (Fig. S2). In the hypohidrotic lesion on the thigh, mild atrophy in the secretory portion of eccrine sweat glands was observed with slight lymphocyte infiltration (Fig. 2c, d). Three months after the discontinuation of PTU, the patient achieved full recovery of hair growth on the entire scalp and normal nail growth without particular treatments, while generalized hypohidrosis persisted (Fig. 1e, f). Clinical course of each symptom and laboratory data is summarized in the supplementary figure (Fig. S1).

DISCUSSION

It is possible that that the development of AA may be related to Graves' disease in this case, since AA can occur in association with autoimmune thyroid diseases including Graves' disease. However, a diagnosis of PTU-

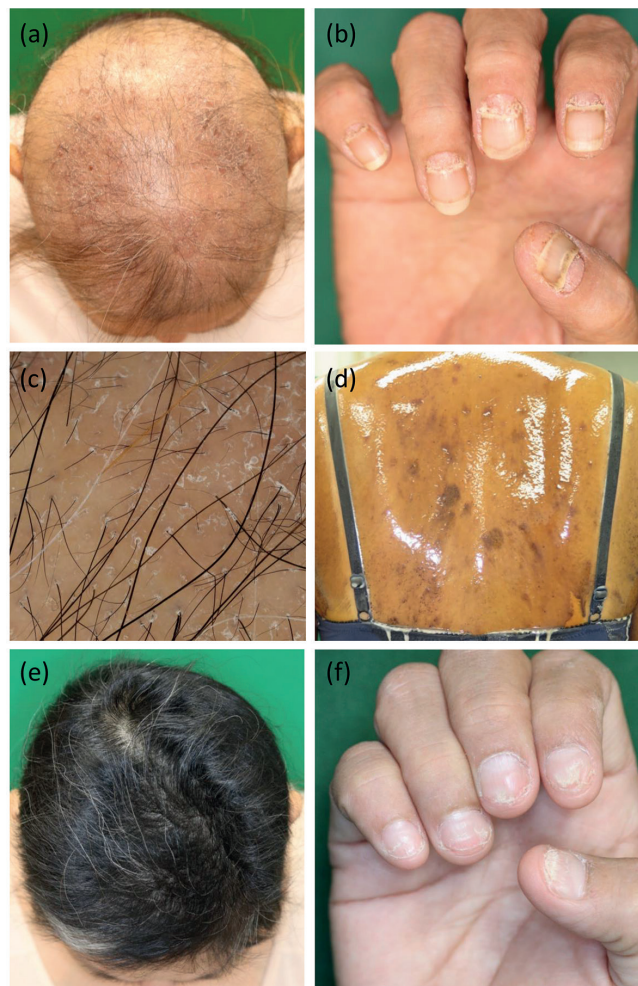


Fig. 1. (a) Almost total hair loss over the scalp. (b) Onychomadesis with periungual erythema and scaling of fingers. (c) Trichoscopy showed sparse vellus hairs, broken hairs, and the sharply bended hair shafts. (d) A thermoregulatory sweat test using the starch-iodine method revealed generalized hypohidrosis distributed on 61% of the total body surface area. (e, f) Three months after discontinuation of propylthiouracil (PTU), the entire scalp and nail plate were completely recovered without treatment.

induced AA is supported by a recovery and sustained remission of alopecia following discontinuation of PTU, and by hypersensitivity to PTU revealed by LTT. The sensitization to PTU might have been established during recovery from immunological suppression by corticosteroids, with the predisposition of autoimmune diseases of IgA nephropathy and Graves' disease. In fact, the rash preceding the alopecia developed in accordance with a decrease of the neutrophil-to-lymphocyte ratio (NLR)

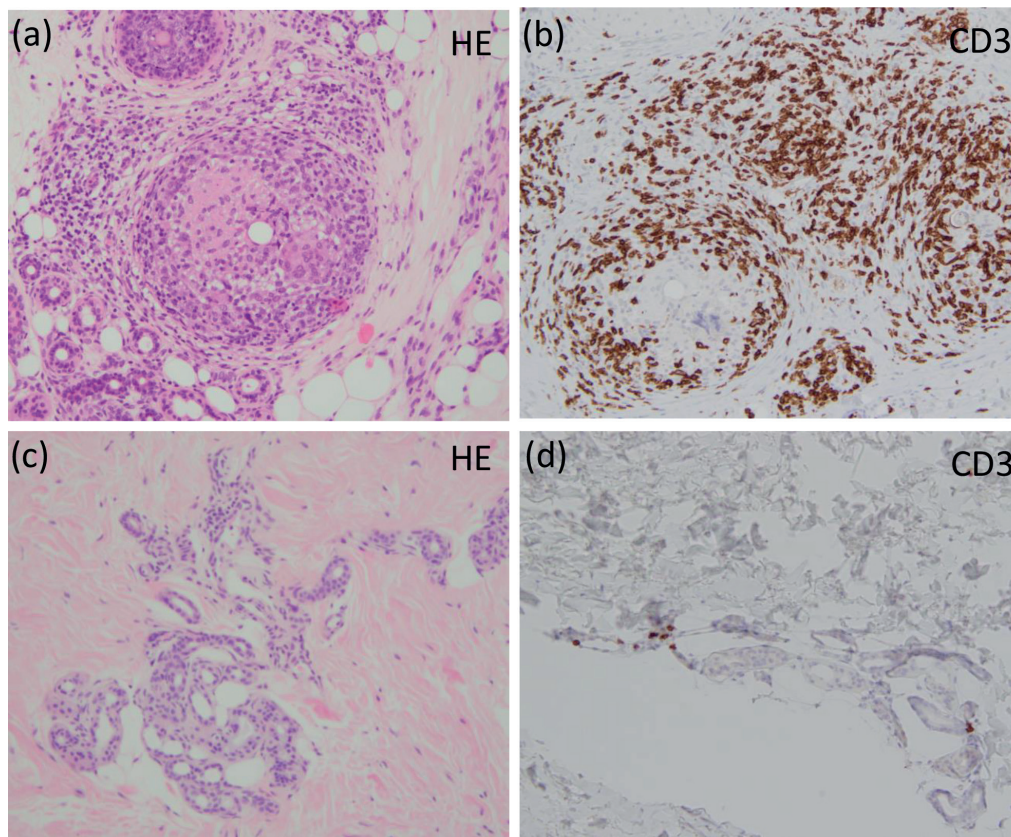


Fig. 2. (a) A skin specimen from alopecia on the scalp revealed dense lymphocytic infiltration and damage to anagen hair bulbs. (b) Infiltrating lymphocytes were stained with CD3 antibody. (c, d) In the lesion of hypohidrosis on the thigh, mild atrophy in the secretory portion of eccrine sweat glands were observed with slight infiltration of CD3⁺ T lymphocyte. HE: haematoxylin and eosin staining: a, b $\times 200$ and c, d $\times 400$.

from 14.6 to 2.5 (Fig. S1). The imbalance of neutrophil and lymphocyte counts was restored upon the withdrawal of prednisolone, possibly reflecting the recovery of the immune response.

The current case presented with multiple cutaneous adnexal disorder involving AA-like hair loss, sweat gland dysfunction, and onychomadesis. After discontinuation of PTU, hair loss and nail symptoms fully recovered, but hypohidrosis did not. Moreover, in histological analysis, hair bulbs were damaged by dense lymphocytic infiltration as seen in idiopathic AA and D-AA (1, 4), whereas no significant morphological change was found in the secretory portion of eccrine sweat glands. Thus, the relationship between alopecia and hypohidrosis is a matter of discussion. In view of the absence of any complications that might cause hypohidrosis, PTU is considered to be the trigger for both hair loss and hypohidrosis based on almost simultaneous or consequential onset of the symptoms following the initiation of PTU. On the other hand, the differences between anhidrosis and alopecia in clinical course and histological findings imply difference between the pathogenic mechanisms involved in these 2 conditions; e.g. the former may be idiopathic, while the latter involves an autoimmune mechanism. Acquired idiopathic generalized anhidrosis can occur even without histologically abnormal sweat glands or

marked lymphocytic infiltration around the glands (5). In conclusion, the current case suggests that PTU can induce D-AA that accompanies generalized hypohidrosis and onychomadesis.

ACKNOWLEDGEMENTS

This study was supported by AMED under Grant Number JP19ek0410059 (S.T. and M.H.).

The authors have no conflicts of interest to declare.

REFERENCES

1. Doyle LA, Sperling LC, Baksh S, Lackey J, Thomas B, Vleugels RA, et al. Psoriatic alopecia/alopecia areata-like reactions secondary to anti-tumor necrosis factor-alpha therapy: a novel cause of noncicatricial alopecia. *Am J Dermatopathol* 2011; 33: 161–166.
2. Marks DH, Mesinkovska N, Senna MM. Cause or cure? Review of dupilumab and alopecia areata. *J Am Acad Dermatol* 2019; Jun 13 [Epub ahead of print].
3. Antoury L, Maloney NJ, Bach DQ, Goh C, Cheng K. Alopecia areata as an immune-related adverse event of immune checkpoint inhibitors: a review. *Dermatol Ther* 2020; 33: e14171.
4. Murad A, Maguire J, Bergfeld W. Drug-induced alopecia areata? *Clin Exp Dermatol* 2021; 46: 363–366.
5. Satoh T. Clinical analysis and management of acquired idiopathic generalized anhidrosis. *Curr Probl Dermatol* 2016; 51: 75–79.