

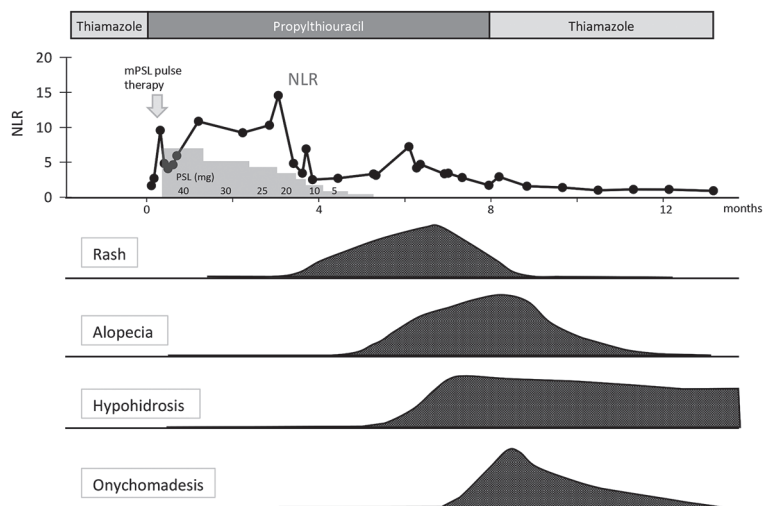Fig. S1. Clinical course of each symptom and laboratory data in the patient. mPSL: methylprednisolone; PSL: prednisolone; NLR: neutrophil-to-lymphocyte ratio.

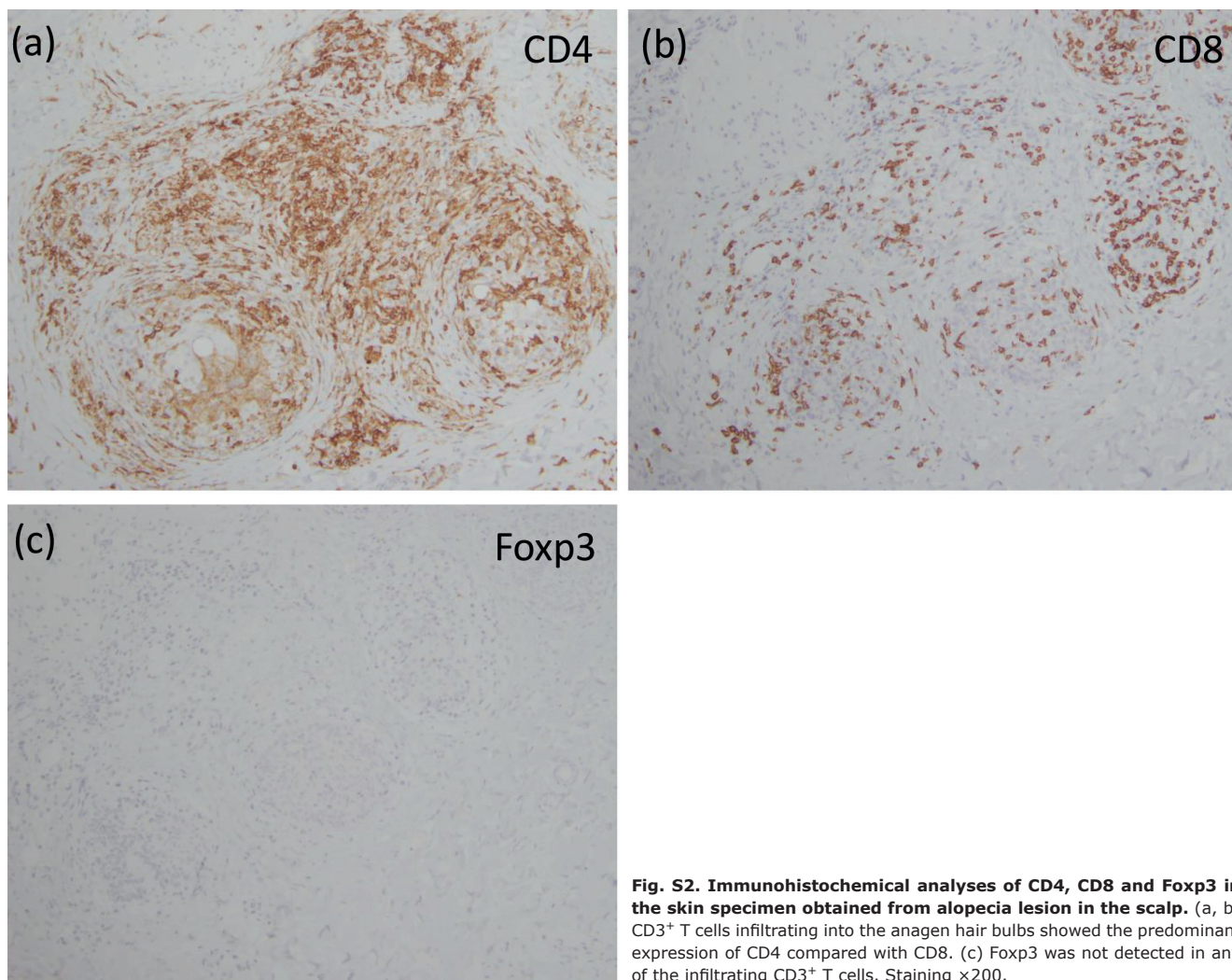


Fig. S2. Immunohistochemical analyses of CD4, CD8 and Foxp3 in the skin specimen obtained from alopecia lesion in the scalp. (a, b) CD3⁺ T cells infiltrating into the anagen hair bulbs showed the predominant expression of CD4 compared with CD8. (c) Foxp3 was not detected in any of the infiltrating CD3⁺ T cells. Staining ×200.