

Efficacy of Oral Ruxolitinib in a Patient with Refractory Chronic Spontaneous Urticaria

Atsushi FUKUNAGA¹, Mitsuhiro ITO² and Chikako NIHIGORI¹

¹Division of Dermatology, Department of Internal Related, Kobe University Graduate School of Medicine, Kobe, Hyogo, 650-0017, and

²Laboratory of Hematology, Division of Medical Biophysics, Kobe University Graduate School of Health Sciences, Kobe, Hyogo, Japan. E-mail: atsushi@med.kobe-u.ac.jp

Accepted Jul 5, 2018; Epub ahead of print Jul 6, 2018

Chronic spontaneous urticaria (CSU) is a skin disorder that is characterized by the spontaneous development of wheals that last for 6 weeks or more (1). CSU is highly prevalent, affecting up to 1% of the population, and has a significant negative impact on a patient's quality of life and health (2). Histamine and other mediators, such as platelet-activating factor and cytokines from activated mast cells, are mainly involved in the pathophysiological aspects of CSU. Inflammatory cytokines, such as Th1-, Th2-, Th17-, and Th22-related cytokines, which are released into the peripheral circulatory micro-environment, have been proposed to determine the disease activity in CSU (3). Significant interactions between the interferon (IFN)- γ , interleukin (IL)-2, and IL-21 networks, which are associated with Janus kinase-signal transducer and activator of transcription (JAK-STAT) signalling, have recently been proposed in CSU (3). The JAK-STAT pathway is used by cytokines, including ILs and IFNs, to transmit signals from the cell membrane to the nucleus. Ruxolitinib, a potent small-molecule inhibitor of JAK1/2, is Food and Drug Administration-approved to treat myeloproliferative disorders and is associated with marked clinical benefits in patients with myelofibrosis (4). It reduces symptoms that are related to proinflammatory cytokine release in haematological disorders. JAK inhibitors are also efficacious in dermatological disorders, including atopic dermatitis, alopecia areata, psoriasis, and vitiligo vulgaris (5). The efficacy of ruxolitinib was reported in a case of systemic mastocytosis, a mast cell-mediated disorder (6), but not in patients with urticaria. We present here a case of a woman with refractory CSU in whom complete control of urticarial symptoms was achieved after treatment with oral ruxolitinib.

CASE REPORT

A 61-year-old woman presented with a 1-year history of recurrent spontaneous urticaria that was resistant to various treatments (H1 antihistamines, oral corticosteroids, and repeated i.v. systemic

corticosteroid) and often accompanied by shortness of breath. H1 antihistamines (fexofenadine hydrochloride 120 mg/day, cetirizine hydrochloride 10 mg/day) and oral prednisolone (15 mg/day) had been prescribed by a family doctor before the first visit, but her symptoms remained. The patient's negative history, provocation testing results, negative prick test results for food, and negative food challenge results excluded chronic inducible urticarias and food allergy. She had not experienced angioedema, unexplained fever, or joint pain in her history, and the mean duration of her wheals was several hours. She did not use anti-inflammatory drugs at the first visit. Therefore, she was diagnosed with CSU (Fig. 1a).

A skin biopsy of a urticarial lesion demonstrated oedema in the upper and mid-dermis, interstitial infiltration of eosinophils and neutrophils in the upper and deep dermis, extended infiltration of eosinophils and neutrophils into the subcutaneous tissue, and no signs of leukocytoclastic vasculitis (Fig. 1c,d). Blood tests showed high blood counts (no blast cells), normal complement levels, and negative C-reactive protein. An autologous serum skin test was positive, indicating the presence of serum histamine-releasing autoantibodies. During the subsequent 6 years, her urticarial symptoms became resistant to several treatments, including uposing of second-generation H1 antihistamines, H2 antagonists, antileukotrienes, systemic corticosteroids, and cyclosporine. Because cerebral infarction occurred during her follow-up, warfarin was started. The warfarin partially improved the urticarial symptoms. However, her urticarial symptoms remained poorly controlled while we waited for the Japanese authorities to approve omalizumab for CSU. Although routine blood tests were performed many times during this follow-up period and showed no abnormality, ensuing blood tests denoted that a peripheral blood smear detected megathrombocytes and blastoid cells. Histological analysis of a subsequent bone marrow biopsy showed hypercellular bone marrow with myelofibrosis and abnormal hematopoietic cells, suggesting chronic myeloproliferative disease. The *JAK2* V617F mutation was identified in peripheral blood cells. An abdominal computed tomography (CT) scan revealed splenomegaly. Therefore, she was diagnosed with primary myelofibrosis. She began treatment with oral ruxolitinib (20 mg/day, twice daily) for abdominal discomfort, which was accompanied by rapid aggravation of splenomegaly. At the time oral ruxolitinib was initiated incidentally by a haematologist in addition to drugs for CSU, including fexofenadine hydrochloride, ebastine, lafutidine, and warfarin. At the start of ruxolitinib, her disease activity and control of CSU remained poor (weekly urticarial activity score (UAS7)=40, Dermatology Life Quality Index (DLQI) score=12, urticaria control test (UCT)=0) (1, 7, 8). Her urticarial symptoms,

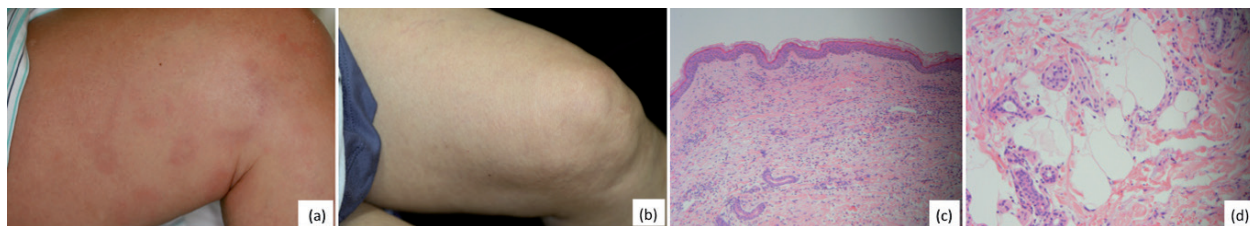


Fig. 1. Clinical appearance: (a) before administration of ruxolitinib; and (b) 5 weeks after initiation with ruxolitinib. Histopathological features: (c) in the dermis; and (d) in the subcutaneous tissue (haematoxylin-eosin staining; original magnification (b: 100 \times , c: 200 \times) (before the start of ruxolitinib).

including the wheals and pruritus, improved markedly within one week after initiation of ruxolitinib, and she became asymptomatic with regard to CSU 2 weeks after treatment outset. Five weeks after the start of ruxolitinib, her UAS7 was 0, UCT was 15, and DLQI was 0 (Fig. 1b), suggesting that the addition of ruxolitinib showed almost complete response. The abdominal discomfort accompanied by splenomegaly disappeared several weeks after the start of ruxolitinib. Eight weeks after initiation, ruxolitinib was reduced to 10 mg/day, due to slight anaemia as a side-effect, by the haematologist, but her urticaria remained asymptomatic 2 months after this de-escalation. However, ruxolitinib was administered continuously for abdominal symptoms rather than skin rash by the haematologist. These clinical course of these treatments are summarized in Fig. 2.

DISCUSSION

This is the first case to show the clinical efficacy of a JAK inhibitor in CSU. Despite the long-term unresponsiveness of various treatments in our CSU patient, the interventional addition of ruxolitinib for complicated primary myelofibrosis significantly improved the urticarial activity within 2 weeks and ultimately led to a long-term complete response for CSU. Notably, ebastine and warfarin could be successfully discontinued under the state of a complete response.

A recent report identified a relationship between a poor treatment response and subcutaneous inflammatory cell infiltration in CSU (9). Indeed, marked eosinophil and neutrophil infiltration into the dermis and subcutaneous tissue was observed in the current case, who was unresponsive to various standard treatments.

Ruxolitinib is a JAK1/2 inhibitor that blocks signal transduction from many cytokine receptors, leading to beneficial effects in patients with myeloproliferative neoplasms. In contrast, increasing evidence has indicated that the pathophysiological aspects of some cases of recurrent CSU include other mast cell mediators, including altered cytokines, in addition to the release of histamine from dermal mast cells (3). Thus, we assume that ruxo-

litinib reduced the inflammation and urticarial activity in our patient with recurrent CSU by blocking signal transduction from various cytokine receptors.

Malignancies have been described as rare causes of CSU (1). Quick resolution of malignancy-linked CSU was observed in some cases, within days to weeks after remission by chemotherapy or resection, strongly indicate a cause-effect relationship (10). Thus, we cannot completely exclude that CSU in this case was a symptom of myelofibrosis, and that adequate treatment of myelofibrosis with ruxolitinib resulted in resolution of CSU.

This report has many limitations. It is a single case report, which remains preliminary for clinical translation and we did not examine the mechanism of action. Although further studies are needed to determine the efficacy of JAK inhibitors in CSU, this case report suggests that they might be a new therapeutic option for patients with refractory CSU.

ACKNOWLEDGEMENTS

The authors thank Edanz Group (www.edanzediting.com/ac) for editing a draft of this manuscript.

Funding: This work was supported Scientific Research (C) (Japan Society for the Promotion of Science KAKENHI) (grant number 15K09742) from the Ministry of Education, Culture, Sports, Science, and Technology, Japan (to AF).

The authors have no conflicts of interest to declare.

REFERENCES

- Zuberbier T, Aberer W, Asero R, Abdul Latiff AH, Baker D, Ballmer-Weber B, et al. The EAACI/GA(2)LEN/EDF/WAO Guideline for the definition, classification, diagnosis, and management of urticaria: The 2017 revision and update. *Allergy* 2018; 73: 1393–1414.
- Maurer M, Weller K, Bindslev-Jensen C, Gimenez-Arnau A, Bousquet PJ, Bousquet J, et al. Unmet clinical needs in chronic spontaneous urticaria. A GA(2)LEN task force report. *Allergy* 2011; 66: 317–330.
- Chen Q, Zhong H, Chen WC, Zhai Z, Zhou Z, Song Z, et al. Different expression patterns of plasma Th1-, Th2-, Th17- and Th22-related cytokines correlate with serum autoreactivity and allergen sensitivity in chronic spontaneous urticaria. *J Eur Acad Dermatol Venereol* 2018; 32: 441–448.
- Verstovsek S, Kantarjian H, Mesa RA, Pardanani AD, Cortes-Franco J, Thomas DA, et al. Safety and efficacy of INCB018424, a JAK1 and JAK2 inhibitor, in myelofibrosis. *N Engl J Med* 2010; 363: 1117–1127.
- Damsky W, King BA. JAK inhibitors in dermatology: the promise of a new drug class. *J Am Acad Dermatol* 2017; 76: 736–744.
- Yacoub A, Prochaska L. Ruxolitinib improves symptoms and quality of life in a patient with systemic mastocytosis. *Biomark Res* 2016; 4: 2.
- Weller K, Groffik A, Church MK, Hawro T, Krause K, Metz M, et al. Development and validation of the Urticaria Control Test: a patient-reported outcome instrument for assessing urticaria control. *J Allergy Clin Immunol* 2014; 133: 1365–1372.
- Mlynek A, Zalewska-Janowska A, Martus P, Staubach P, Zuberbier T, Maurer M. How to assess disease activity in patients with chronic urticaria? *Allergy* 2008; 63: 777–780.
- Itoh E, Nakahara T, Murata M, Ito T, Onozuka D, Furumura M, et al. Chronic spontaneous urticaria: Implications of subcutaneous inflammatory cell infiltration in an intractable clinical course. *J Allergy Clin Immunol* 2017; 139: 363–366 e3.
- Larenas-Linnemann D, Saini SS, Azamar-Jácome AA, Maurer M. Chronic urticaria can be caused by cancer and resolves with its cure. *Allergy* 2018; 73: 1562–1566.

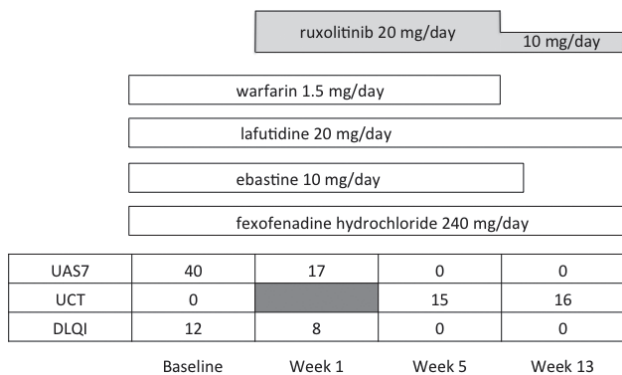


Fig. 2. Clinical course of chronic spontaneous urticaria (CSU) after administration of ruxolitinib. The treatment in Fig. 2 is not in accordance with current international guideline recommendations. Neither warfarin nor lafutidine nor a combination of different H1-antihistamines is recommended in the current international guideline recommendations (1). Cerebral infarction occurred during follow-up, and warfarin was started. The urticarial symptoms improved markedly within one week after initiation of ruxolitinib and the patient became asymptomatic with regard to CSU 2 weeks after initiation of ruxolitinib.