

## Delayed Onset and Protracted Course of Psoriasis-like Secondary Syphilitic Lesions in a HIV-seropositive Man Who has Sex with Men: A Case Report

Rui-Rui PENG<sup>1</sup>, Shuxian SHANG<sup>2</sup>, Jia CHEN<sup>3</sup>, Mei SHI<sup>1</sup> and Fu-Quan LONG<sup>1\*</sup>

<sup>1</sup>STD Institute and <sup>3</sup>Department of Dermatopathology, Shanghai Dermatology Hospital, Tongji University School of Medicine, Shanghai 210043, and <sup>2</sup>Institute of Dermatology, Chinese Academy of Medical Sciences and Peking Union Medical College, Nanjing, China. \*E-mails: md\_longfuquan@163.com or zpyls@yahoo.com

Accepted Aug 22, 2019; E-published Aug 22, 2019

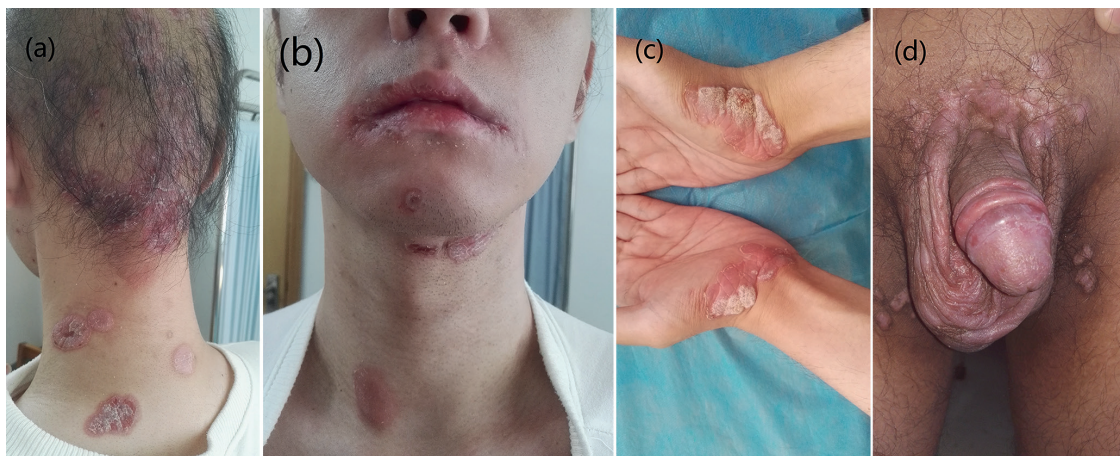Syphilis is a chronic sexually transmitted infection caused by *Treponema pallidum*. The protean cutaneous manifestations of secondary syphilis span a wide spectrum and have earned the name of “the great imitator” (1, 2). Secondary syphilitic lesions usually occur within 3 months after initial exposure to *T. pallidum* and last for 4 to 12 weeks (3). However, co-infection with HIV may alter the clinical presentation and course (4). Here, we report a long-term misdiagnosed HIV-seropositive homosexual man presenting with psoriasis-like secondary syphilitic lesions, which appeared approximately 3 years after initial infection and had a protracted course over one year. Such notable deviations from the normal expectations have never been reported.

### CASE REPORT

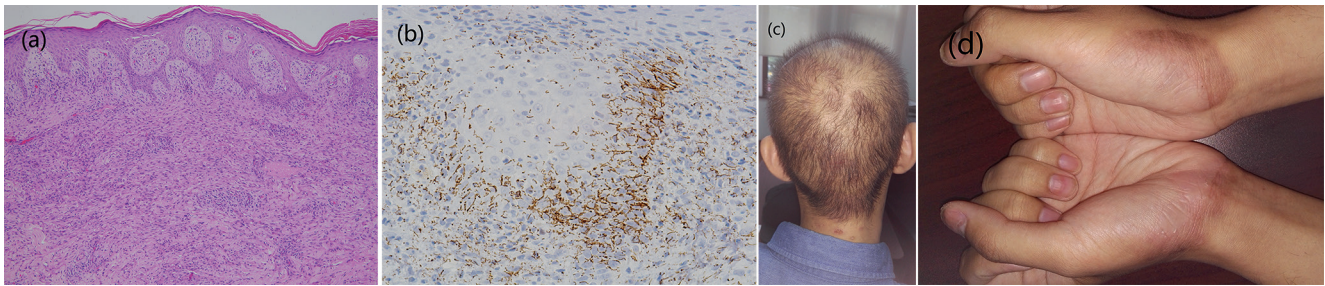
A 30-year-old man who complained of skin rashes and hair loss for more than one year was referred to our STD clinic in August 2017. He denied any sexual behaviour except for two episodes of unprotected anal sex with men in July 2012 and March 2013. His serological tests for HIV and syphilis were all negative before his last sexual encounter. He was diagnosed with HIV infection in July 2013; at that time his CD4<sup>+</sup> T-cell count was 46 cells/ul. He concealed his HIV status from his family members and doctors. He started highly active antiretroviral therapy in September 2016, but he ceased treatment voluntarily after 3 months because of profoundly

pessimistic thoughts. The patient had experienced gradual hair loss and recurrent scalp dermatitis since July 2016. He had been diagnosed with psoriasis with concomitant alopecia for more than one year and was tested for syphilis and HIV in the dermatology clinics. He received intermittent therapy with a topical steroid ointment without improvement. The lesions progressively expanded to involve his neck, shoulders, wrists, feet and genitals.

Physical examination revealed patchy alopecia and multiple varisized infiltrated flat red psoriasis-like plaques involving the scalp, neck, face, shoulders, feet and genitals (**Fig. 1**). He had axilla, neck, submaxilla and groin lymphadenopathy. The *T. pallidum* particle assay was positive with a toluidine red unheated serum test titre of 1:64. His HIV viral load was 151 copies/ml, and his CD4<sup>+</sup> T-cell count was 15 cells/μl. Cerebrospinal fluid tests indicated slightly elevated leukocyte (15 cells/μl) and protein levels (60 mg/dl), but the Venereal Disease Research Laboratory test was negative. A skin biopsy taken from a left wrist lesion revealed that the epidermis was irregularly proliferated, dermal papillae were oedematous, and perivascular plasma cells had infiltrated the superficial dermis (**Fig. 2a**). Immunohistochemical analysis using a polyclonal antibody against *T. pallidum* showed numerous spirochetes (**Fig. 2b**). The diagnosis of secondary syphilis and HIV infection was confirmed. The patient received 4 million units of benzylpenicillin intravenously every 4 h for 14 days. His skin lesions and



**Fig. 1.** a) Patchy alopecia and red psoriasis-like plaques on the patient's scalp and neck. b) Red plaques on the patient's neck and jaw and dry erythema on his lips. Several varisized red and flat-topped, hypertrophic, verrucous and psoriasis-like plaques on the patient's wrists (c) and genital area (d).



**Fig. 2.** A skin biopsy specimen from the patient's left wrist lesion revealed that the epidermis was irregularly proliferated, dermal papillae were oedematous, and perivascular plasma cells infiltrated in the superficial dermis (haematoxylin-eosin stain, original magnification  $\times 100$ ) (a). Immunohistochemical analysis using a polyclonal antibody against *T. pallidum* showed numerous spirochetes (original magnification  $\times 400$ ) (b). Six weeks after treatment, the lesions on the patient's scalp (c) and wrists (c) almost disappeared.

patchy alopecia improved significantly 6 weeks later (Fig. 2c, d). The patient is still being followed.

## DISCUSSION

Syphilis is one of the most important and neglected diseases. A resurgence in syphilis has been observed in many parts of the world in recent decades, especially in China (2, 5). The alarming resurgence has been characterized by high rates of concomitant HIV infection, especially among men who have sex with men (MSM) (6). Co-infection with HIV affects the initial presentation, disease course, diagnosis, and treatment of syphilis (7, 8). It has been documented that HIV often accelerates the progression of syphilis (4, 6, 9). However, our patient did not develop cutaneous eruptions of secondary syphilis until approximately 3 years after *T. pallidum* infection (we cannot be sure of the precise infection date based on the patient's declarations), and had a protracted course of more than one year. Similarly, Carnuba et al. (10) reported that a 44-year-old woman suffering from secondary syphilis and coinfecting with human T-lymphotropic virus-1, a causative agent that, like HIV, predominately invades CD4<sup>+</sup> T cells; it presents with syphilitic lesions with a two-year delayed-onset and lasts for 6 months.

Previous studies have indicated that the clinical course and manifestation of secondary syphilis may be determined by the deposition of circulating immune complexes in highly susceptible tissue and influenced by the balance between delayed-type hypersensitivity and humoral immunity (11, 12). The significantly reduced CD4<sup>+</sup> T-cell count in our patient may have played a role in the delayed onset of his symptoms, suggesting that cellular immunity can modify the evolution of the infection (13, 14). However, the exact mechanism of how HIV and *T. pallidum* co-interact with the host is still unclear.

The early diagnosis and treatment of syphilis in HIV-infected patients is challenging due to atypical clinical features and deviations from the expected course (15). In this case, the patient had been misdiagnosed with psoriasis for more than one year and was finally diagnosed by skin lesion biopsy and serological tests for syphilis. Such unusual presentations should remind clinicians to

be alert to the atypical clinical manifestation of syphilis, especially in patients infected with HIV.

*The authors have to no conflicts of interest declare.*

## REFERENCES

1. Peeling RW, Hook EW 3rd. The pathogenesis of syphilis: the Great Mimicker, revisited. *J Pathol* 2006; 208: 224–232.
2. Balagula Y, Mattei PL, Wisco OJ, Erdag G, Chien AL. The great imitator revisited: the spectrum of atypical cutaneous manifestations of secondary syphilis. *Int J Dermatol* 2014; 53: 1434–1441.
3. Baughn RE, Musher DM. Secondary syphilitic lesions. *Clin Microbiol Rev* 2005; 18: 205–216.
4. Pialoux G, Vimont S, Moulignier A, Buteux M, Abraham B, Bonnard P. Effect of HIV infection on the course of syphilis. *AIDS Rev* 2008; 10: 85–92.
5. Chen XS. Syphilis trends in China: biased by screening and reporting? *Lancet Infect Dis* 2017; 17:804.
6. Roberts CP, Klausner JD. Global challenges in human immunodeficiency virus and syphilis coinfection among men who have sex with men. *Expert Rev Anti Infect Ther* 2016; 14: 1037–1046.
7. Funnyé AS, Akhtar AJ. Syphilis and human immunodeficiency virus co-infection. *J Natl Med Assoc* 2003; 95: 363–382.
8. Zetola NM, Engelman J, Jensen TP, Klausner JD. Syphilis in the United States: an update for clinicians with an emphasis on HIV coinfection. *Mayo Clin Proc* 2007; 82: 1091–1102.
9. Szetela B, Gasiorowski J. Rapid progression and overlapping of skin eruptions in a patient with secondary and tertiary syphilis coinfecting with HIV. *AIDS Res Hum Retroviruses* 2016; 32: 874–875.
10. Carnuba D, Jr., Bittencourt A, Brites C. Atypical presentation of syphilis in an HTLV-I infected patient. *Braz J Infect Dis* 2003; 7: 273–277.
11. Jorizzo JL, McNeely MC, Baughn RE, Solomon AR, Cavallo T, Smith EB. Role of circulating immune complexes in human secondary syphilis. *J Infect Dis* 1986; 153: 1014–1022.
12. Carlsson JA, Dabiri G, Cribier B, Sell S. The immunopathobiology of syphilis: the manifestations and course of syphilis are determined by the level of delayed-type hypersensitivity. *Am J Dermatopathol* 2011; 33: 433–460.
13. Rosa G, Procop GW, Schold JD, Piliang MP. Secondary syphilis in HIV positive individuals: correlation with histopathologic findings, CD4 counts, and quantity of treponemes in microscopic sections. *Cutan Pathol* 2016; 43: 847–851.
14. Palacios R, Jiménez-Oñate F, Aguilar M, Galindo MJ, Rivas P, Ocampo A, et al. Impact of syphilis infection on HIV viral load and CD4 cell counts in HIV-infected patients. *J Acquir Immune Defic Syndr* 2007; 44: 356–359.
15. Genovese G, Nazzaro G, Coggi A, Gianotti R, Ramoni S, Cusini M. Secondary syphilis masquerading as lupus vulgaris in an HIV-infected patient: A diagnosis suggested by histology. *Int J STD AIDS* 2018; 29: 1454–1456.