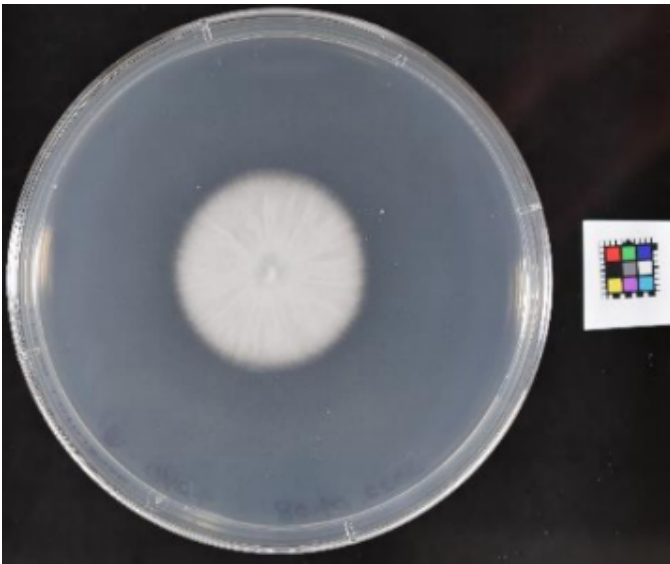
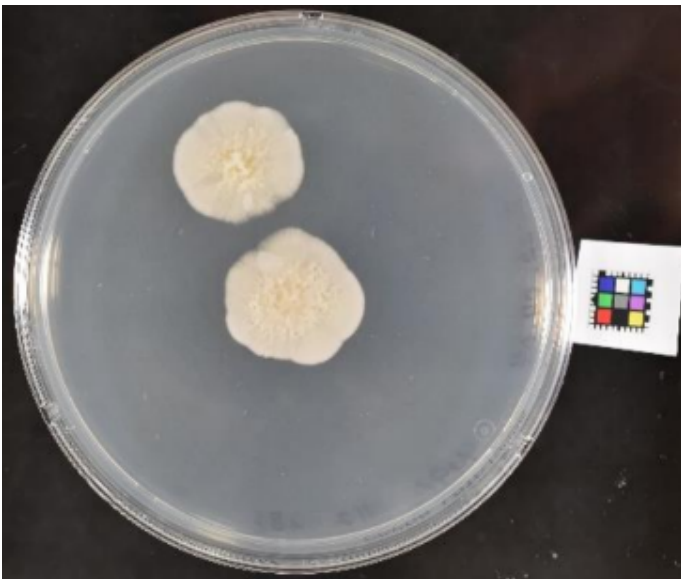


Supplementary material has been published as submitted. It has not been copyedited, or typeset by Acta Dermato-Venereologica

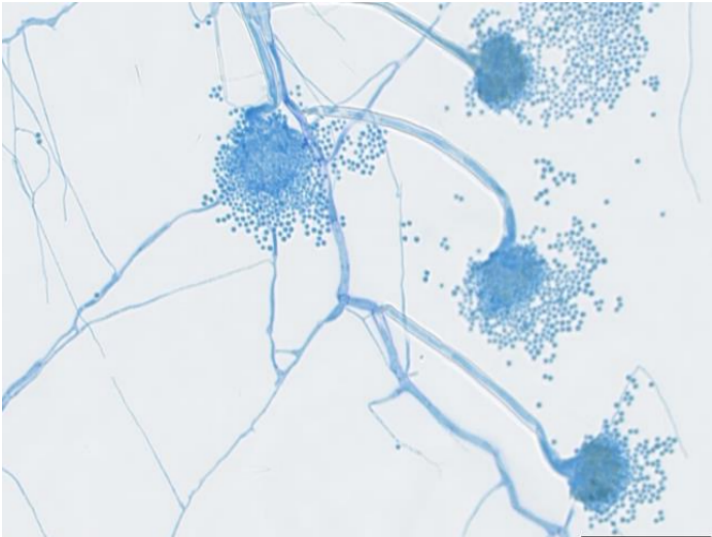
**Fig. S1a: Clinical photograph: white colony on potato dextrose agar**



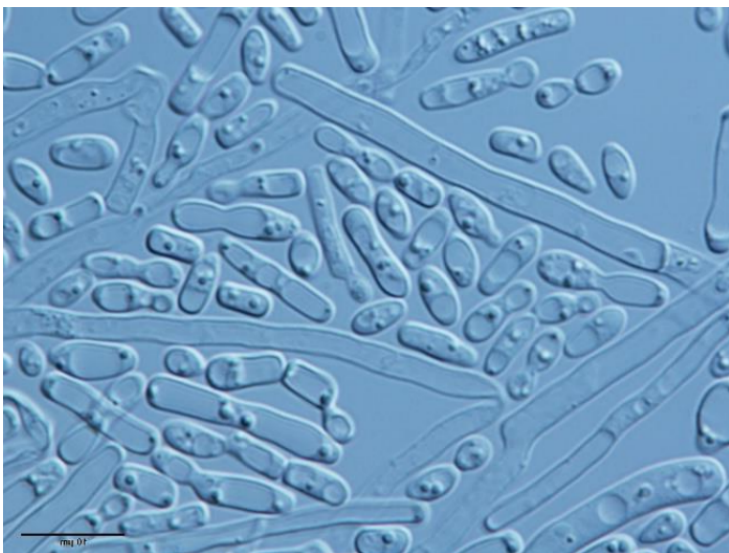
**Fig. S1b: Clinical photograph: yellowish colony on potato dextrose agar**



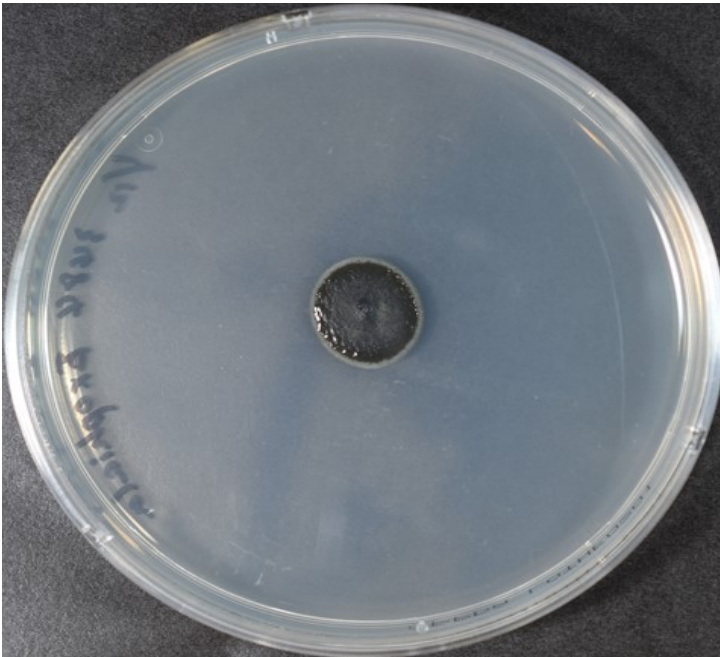
**Fig. S2a: Microscopic findings of slide culture on the white colony: fungal hyphae and clusters of fungal spores**



**Fig. S2b: Microscopic findings of slide culture on the yellowish colony: fungal hyphae and yeast-like spores**



**Fig. S3a: Clinical photograph: black colony on potato dextrose agar**



**Fig. S3b: Microscopic findings of slide culture on the black colony: fungal hyphae and spores**

