

Supplementary material has been published as submitted. It has not been copyedited, or typeset by Acta Dermato-Venereologica

Fig. S1. Preparation of the autologous patch). A: The blood sample after centrifugation. B: The autologous patch.

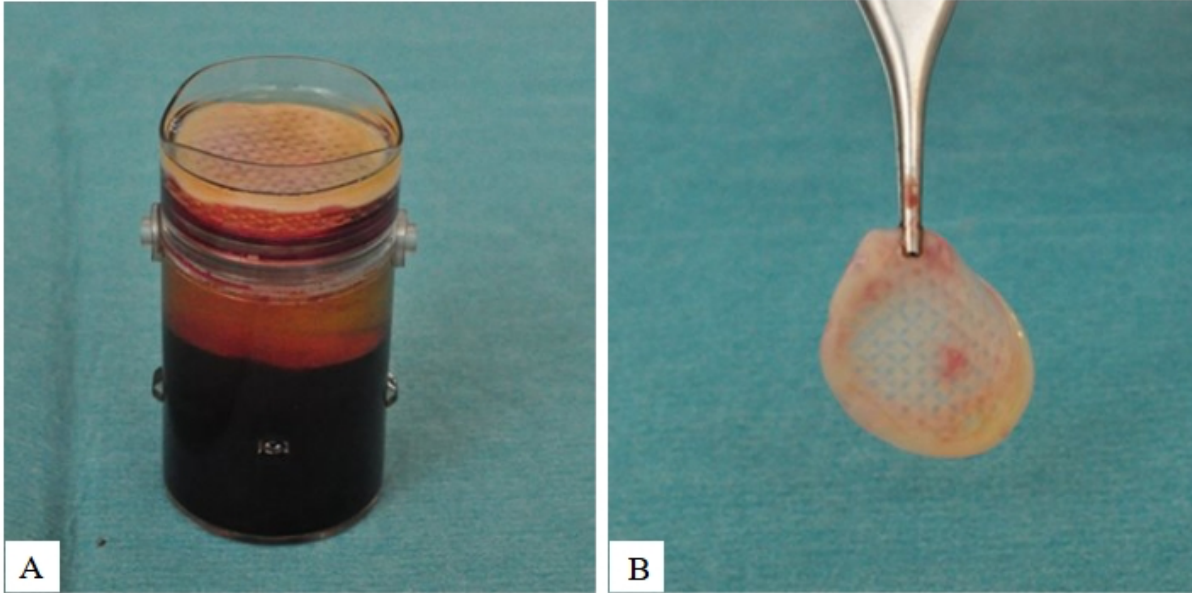
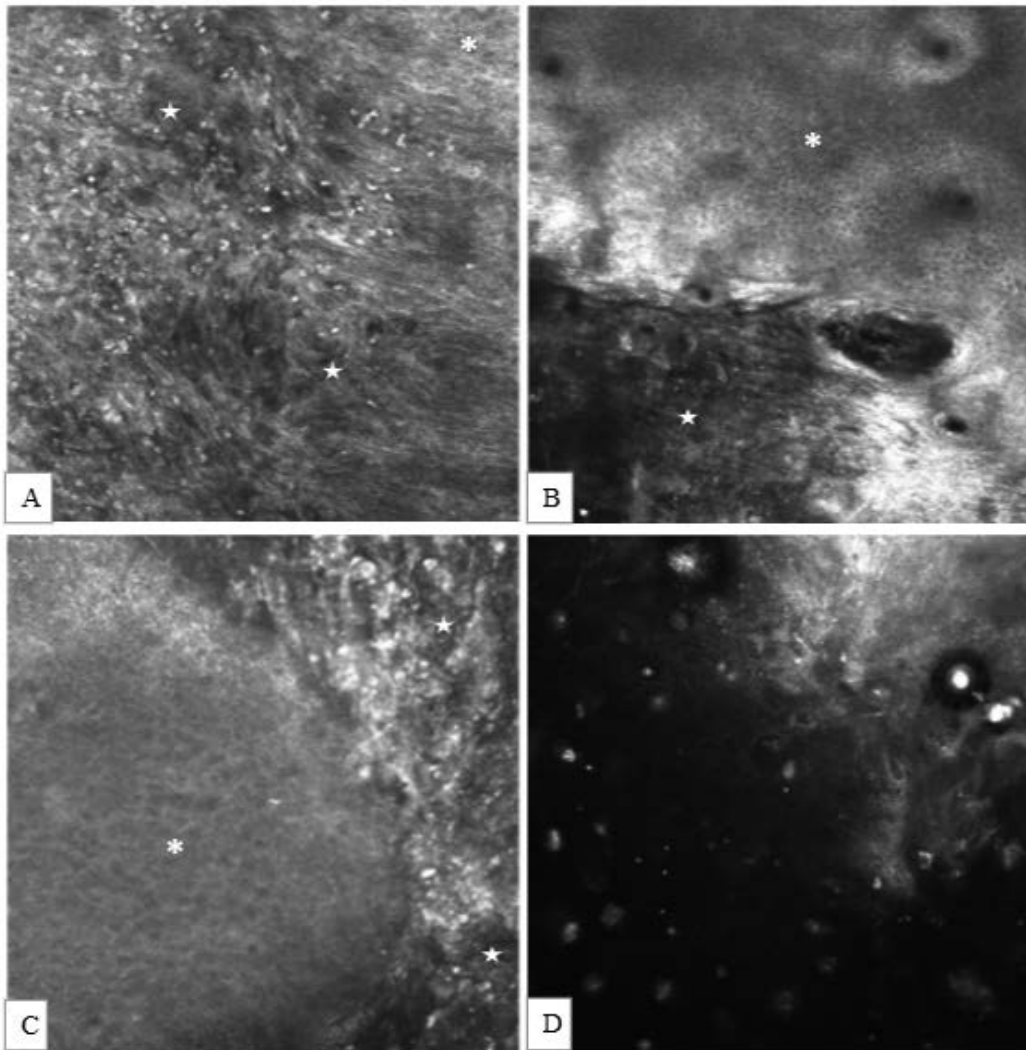


Fig. S2. Reflectance Confocal Microscopy of four patients.



A: ID1 (patch), B: ID5 (patch), C: ID20 (patch), D: ID21 (secondary intent).
Leucocytes (star), well-ordered normal keratinocytes (asterisk)