

Pyoderma Gangrenosum in a Splenectomy Incision in a Patient with Haemolytic Anaemia due to Hereditary Spherocytosis: a Case Report and Literature Review

Piotr K. KRAJEWSKI, Iwona CHLEBICKA, Jacek C. SZEPIETOWSKI and Joanna MAJ

Department of Dermatology, Venereology and Allergology, Wrocław Medical University, Chalubinskiego 1, PL-50-368 Wrocław, Poland.
E-mail: jacek.szepietowski@umed.wroc.pl

Accepted Oct 25, 2021; Epub ahead of print Oct 25, 2021

Pyoderma gangrenosum (PG) is a rare, inflammatory, neutrophilic disorder, first described in 1908 by Brocq (1). The pathogenesis of PG is not yet fully understood and, due to a lack of definitive diagnostic criteria, it is considered a diagnosis of exclusion (2). Suggested mechanisms leading to development of PG include neutrophilic dysfunction, genetic influence and a pathological inflammatory process (3–5). PG affects both men and women at all ages, with a prevalence peak between 50 and 60 years old (6). In up to 65% of cases of PG the disease is associated with an underlying systemic disorder (7). Treatment consists of wound care, pain control, and topical and systemic immunosuppressive therapy (2). We present here a rare case of PG in a splenectomy incision in a patient with haemolytic anaemia, which was treated successfully with systemic steroids. In addition, a literature review of similar cases is presented.

CASE REPORT

A 49-year-old woman, with no significant medical history, was admitted to the department of dermatology due to postoperative complications, which started 6 days after laparotomic splenectomy. Nine months before the surgery the patient was admitted to hospital due to paleness and excessive fatigue. On admission, full blood count revealed severe haemolytic anaemia with poikilocytosis, anisocytosis and spherocytosis. Serological analysis and further blood tests did not reveal any abnormalities. Bone marrow examination (myelogram and trephine biopsy) disclosed increased erythropoiesis with signs of dysplasia and excessive numbers of megakaryocytes. In addition, abdominal ultrasound revealed splenomegaly with numerous hyperechogenic areas and widened splenic vein. Spherocytosis was diagnosed based on the clinical picture and blood analysis. After 3 months and a few hospitalizations due to haemolytic crises, haematologists decided to remove the patient's spleen. Difficulties in wound healing were observed shortly after the splenectomy. After unsuccessful therapy with empirical antibiotics, the woman was referred to the dermatology department for consultation. On admission, 3 round ulcers with irregular, raised, purple, inflammatory borders and surrounding erythema were observed. Two of the ulcers were localized at the beginning and end of the surgical incision, and the third, similar ulcer, near the drainage (Fig. 1A). PG was diagnosed based on the clinical picture and anamnesis. The patient received 500 mg intravenous methylprednisolone daily for 5 consecutive days. Afterwards therapy was continued with oral prednisone, 40 mg/day. On the follow-up, after 4 weeks of therapy, the lesions healed completely (Fig. 1B).

DISCUSSION

PG is a rare neutrophilic dermatosis, in the course of which patients develop solitary or multiple painful skin

ulceration with characteristic erythematous active border (8). The clinical presentation and course of PG often vary greatly between cases and, therefore, it is frequently misdiagnosed. The clinical variants of PG include ulcerative, bullous, pustular, vegetative, peristomal and surgical subtypes (2). The pathogenesis of PG is not fully understood; however, it is commonly associated with underlying systemic conditions. Authors often mention its co-occurrence with inflammatory bowel disease (ulcerous colitis and Crohn's disease), rheumatological (polyarthritis), and haematological disorders (leukaemias, myelodysplastic syndromes) (2, 9, 10). Moreover, Al Ghazal et al. (11), in their paper indicated a necessity to look for additional, possible, unreported predisposing comorbidities, such as anaemia, obesity or diabetes. Furthermore, even less frequently, PG development with no predisposing disease or associated comorbidity is possible. The exaggeration of a skin injury, which may occur after minor trauma, termed pathergy phenomenon, may be seen in one-third of patients with PG. According to the study by Tolkachjov

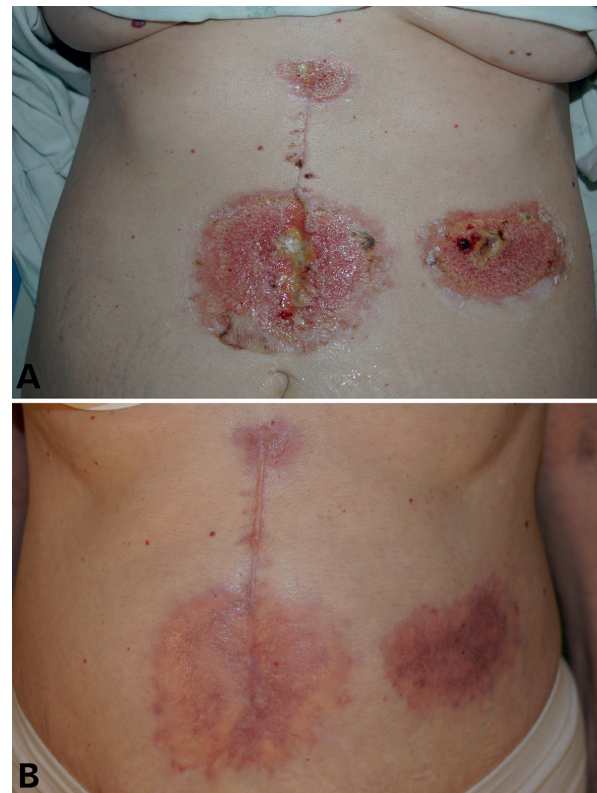


Fig. 1. The lesions (A) before treatment and (B) after 4 weeks of therapy.

et al. (12), the majority of patients (66%) who develop postoperative PG do not have any predisposing systemic condition. In those cases, ulceration at the incision site appears 6.86 ± 4.95 days after surgery (12). In the current patient the time until development of lesions was shorter and took 4 days. However, in the remainder of the cases reported, the time was 6–7 days. The lesions may affect almost every anatomical area: breasts, abdominal and chest wall, lower and upper extremities, with equal distribution among both sexes. Diagnosis of PG is difficult due to the lack of specific markers and histopathology. The optimal evaluation should involve the patient's history, physical examination and skin biopsy (2). Diagnostic criteria, proposed by Maverakis et al. (13), include 1 major criterion (neutrophilic infiltrate in skin biopsy) and 8 minor criteria (exclusion of infection; pathergy; history of inflammatory bowel disease or inflammatory arthritis; history of papule, pustule, or vesicle ulcerating within 4 days of appearing; peripheral erythema, undermining border, and tenderness at ulceration site; multiple ulcerations, at least one on an anterior lower leg; cribriform or "wrinkled paper" scar(s) at healed ulcer sites; and decreased ulcer size within 1 month of initiating immunosuppressive medication(s)) (13). In the current case we decided not to take a biopsy, because the lesions had direct connection with a surgical injury. Since pathergy phenomenon was suspected, any additional trauma could cause further development of PG and deterioration of the patient's health. Moreover, the diagnosis could be made on a clinical basis, due to a typical clinical picture, patient history of systemic disorder, and no response to antibiotic therapy. Treatment of PG presents a challenge for clinicians, as there are only 2 randomized controlled trials and no international guidelines. First-line therapy consists of analgesia, local wound care and topical treatments, which include corticosteroids or tacrolimus ointments. In more severe cases the patients are given oral steroids, cyclosporine, colchicine, sulphasalazine, dapsone or thalidomide. Lately, there is increasing evidence supporting the use of biological treatment in the management of PG. Among them, infliximab and adalimumab have shown the biggest efficacy in the wound healing, but there are also reports of use of etanercept, ustekinumab, anakinra and canakinumab (14).

The association of haemolytic anaemias with PG is rare; there are only 6 cases in the literature (Appendix S1; STable 1[†]). Among them, the most common haematological disorder was paroxysmal nocturnal haemoglobinuria, present in 3 patients. Most of the patients were young adults and all of them were males. In almost all cases the cause of PG development was skin trauma. All the patients were treated with systemic steroids, in 2 cases these were combined with immunosuppressants.

The available literature on PG in a splenectomy incision is extremely scarce, with only 4 similar cases described

(Appendix S1; STable 1[†]). In most of these cases lesions appeared 4–7 days after the surgery. In addition, all of the patients were primarily treated with empirical antibiotic for bacterial infection and referred to a dermatologist after unsuccessful treatment.

Based on the above-mentioned case reports, one may conclude that association of HS with PG is extremely rare. The current patient is reported here because it is the second case of such an association and the first with lesions at the incision site. In addition, it is important to remember that PG at the incision site may present a diagnostic challenge for clinicians and mimic bacterial infection. PG should be diagnosed after the failure of initial treatment with empirical antibiotics, sometimes with negative swabs. It is important to emphasize, that a mistake in diagnosis may delay treatment and hence prolong patient's symptoms.

The authors have no conflicts of interest to declare.

REFERENCES

- Brunsting L, Goeckerman W, O'leary P. Pyoderma (echthyma) gangrenosum clinical and experimental observations in five cases occurring in adults. *Arch Derm Syphilol* 1930; 22: 655–680.
- Alavi A, French LE, Davis MD, Brassard A, Kirsner RS. Pyoderma gangrenosum: an update on pathophysiology, diagnosis and treatment. *Am J Clin Dermatol* 2017; 18: 355–372.
- Adachi Y, Kindzelskii AL, Cookingham G, Shaya S, Moore EC, Todd RF, 3rd, et al. Aberrant neutrophil trafficking and metabolic oscillations in severe pyoderma gangrenosum. *J Invest Dermatol* 1998; 111: 259–268.
- Marzano AV, Ortega-Loayza AG, Heath M, Morse D, Genovese G, Cugno M. Mechanisms of inflammation in neutrophil-mediated skin diseases. *Front Immunol* 2019; 10: 1059.
- Braswell SF, Kostopoulos TC, Ortega-Loayza AG. Pathophysiology of pyoderma gangrenosum (PG): an updated review. *J Am Acad Dermatol* 2015; 73: 691–698.
- Al Ghazal P, Herberger K, Schaller J, Strölin A, Hoff NP, Goerge T, et al. Associated factors and comorbidities in patients with pyoderma gangrenosum in Germany: a retrospective multicentric analysis in 259 patients. *Orphanet J Rare Dis* 2013; 8: 136.
- DeFilippis EM, Feldman SR, Huang WW. The genetics of pyoderma gangrenosum and implications for treatment: a systematic review. *Br J Dermatol* 2015; 172: 1487–1497.
- Al Ghazal P, Klode J, Dissemond J. Diagnostic criteria for pyoderma gangrenosum: results of a survey among dermatologic wound experts in Germany. *J Dtsch Dermatol Ges* 2014; 12: 1129–1131.
- Brambilla L, Minuti A, Brambilla M, Tourlaki A, Genovese G, Berti E. Late-onset post-mammoplasty pyoderma gangrenosum treated with tobacco-pouch suture combined with oral corticosteroids. *G Ital Dermatol Venereol* 2020; 155: 702–704.
- Dolci A, Indirli R, Genovese G, Derlino F, Arosio M, Marzano AV. Post-surgical thyroid bed pyoderma gangrenosum mimicking recurrent papillary thyroid carcinoma. *Front Endocrinol (Lausanne)* 2019; 10: 253.
- Al Ghazal P, Korber A, Klode J, Dissemond J. Investigation of new co-factors in 49 patients with pyoderma gangrenosum. *J Dtsch Dermatol Ges* 2012; 10: 251–257.
- Tolkachjov SN, Fahy AS, Cerci FB, Wetter DA, Cha SS, Camilleri MJ. Postoperative pyoderma gangrenosum: a clinical review of published cases. *Mayo Clin Proc* 2016; 91: 1267–1279.
- Maverakis E, Ma C, Shinkai K, Fiorentino D, Callen JP, Wollina U, et al. Diagnostic criteria of ulcerative pyoderma gangrenosum: a Delphi consensus of international experts. *JAMA Dermatol* 2018; 154: 461–466.
- George C, Deroide F, Rustin M. Pyoderma gangrenosum – a guide to diagnosis and management. *Clin Med (Lond)* 2019; 19: 224–228.

[†]<https://doi.org/10.2340/actadv.v101.438>