

# An Experimental Study Evaluating the Effect of Minoxidil on the Growth Cycle of Hair Follicles

GLEND A C. GOBÉ<sup>1</sup> and GEOFFREY M. STRUTTON<sup>2</sup>

<sup>1</sup>Department of Pathology, University of Queensland, Medical School, Herston, Queensland, and

<sup>2</sup>Department of Pathology, Royal Brisbane Hospital, Brisbane, Queensland, Australia

The possibility that topically-applied minoxidil might affect the growth cycle of hair follicles was studied in inbred Herston white mice and HRA/Skh1 hairless mice. In the normal follicular cycle, the anagen or growth phase can be followed by autoradiographic demonstration of [<sup>3</sup>H]thymidine uptake in proliferating matrical cells, and the catagen or regression phase can be recognised, using light microscopy, by the presence of greatly increased death of matrical cells by apoptosis. Using these two markers, the effects of topically-applied minoxidil on follicular kinetics were studied, during neonatal hair growth and the spontaneous wave of hair loss that occurs 16 to 17 days after birth. Minoxidil at strengths of either 1% or 3%, applied daily to the dorsal skin of newborn mice from birth until 25 days of age, was found to have no recognisable effect. Despite this negative result, however, the study does show the potential for the use of apoptosis as a marker for catagen in research in dermatopathology. **Key words:** Apoptosis; Cell death; Alopecia; Anagen; Catagen; Autoradiography.

(Accepted November 30, 1988.)

Acta Derm Venereol (Stockh) 1989; 69: 190-194.

G. Gobé, Department of Pathology, University of Queensland, Medical School, Herston, Queensland, Australia 4006.

The use of minoxidil (2,4-diamino-6-piperidino-3-oxide) as a topical treatment for alopecia has renewed interest in hair research. Nonetheless, since Zappacosta's (1) revelation of this effect, its exact mode of action is still not clear. Reports that it may enhance the anagen or growth phase of the follicular hair cycle (2-5) prompted us to carry out an experimental study of the effects of topically-applied minoxidil on follicular kinetics.

The newborn mouse provides a suitable model, since anagen proceeds relatively synchronously with the growth of terminal hairs until the mice are 16 to 17 days old, when a spontaneous wave of synchronous catagen occurs. The current study aimed to com-

pare the cell growth cycle in two different strains of mice, with and without minoxidil. Anagen can be followed by light microscopic recognition of mitosis and by the presence, in autoradiographs, of [<sup>3</sup>H]thymidine-labelled follicular matrical cells. The onset of catagen can be detected by the dramatic lack of autoradiographic labelling of follicular matrical cells, and by a sudden marked increase of apoptosis in follicles. This distinctive type of cell death has been shown to be widely involved in tissue atrophy (6, 7) and accounts for the cell deletion responsible for follicular regression (8-10).

## MATERIALS AND METHODS

### Animals

Litters were used from two inbred strains of mice: Herston white mice with normal hair growth, and HRA/Skh1 hairless (Type 1, albino) mice with hair growth that does not recommence after spontaneous catagen. Litter size was limited to eight, and these were housed in separate mouse cages, free access being allowed to a pelleted diet and to water. Climate, nutrition and light were standardised as these may influence moulting in animals which show spontaneous catagen (11). The room in which they were kept was maintained at 21 ± 2°C, and had an artificial light:dark cycle of 12:12 h, with light from 6 a.m. to 6 p.m.

### Preparation of lotions

Minoxidil: 2,4-diamino-6-piperidino-3-oxide, or Loniten of the Upjohn Company, Kalamazoo, USA.

Minoxidil lotions: Minoxidil (crushed 25 mg tablets) 1% or 3%, propylene glycol 10%, distilled water 20%, and ethanol to 100%.

Control lotion: propylene glycol 10%, distilled water 20%, and ethanol to 100%.

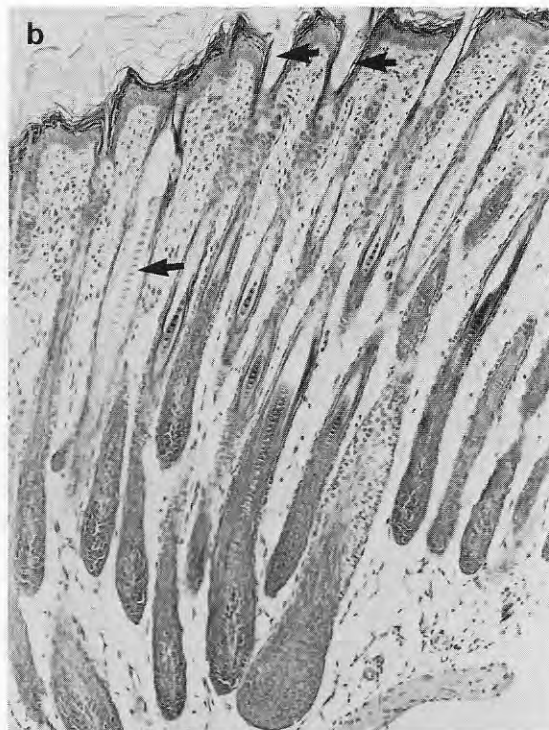
### Experimental protocol

Four groups, each of 52 animals, were used for both strains of mice. These groups were: 1) untreated litters, 2) litters treated with 1% minoxidil lotion, 3) litters treated with 3% minoxidil lotion, 4) sham-treated litters (control lotion).

The dorsal skin of the young animals in groups 2, 3 and 4 was treated with the selected lotion once daily, between 9 and 11 a.m., from day 0 to day 25 after birth. Careful monitoring

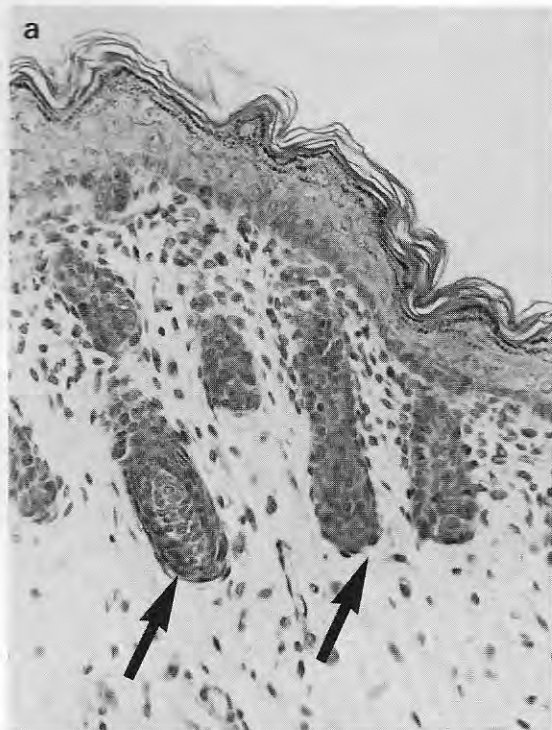

Fig. 1. Active growth phase (anagen) in the skin of neonatal mice: (a) At day 0, the follicular matrix (large arrows) starts to grow down into the skin. No terminal hairs are seen.



(b) At day 10, the follicles are deep in the skin. Many terminal hairs (small arrows) are visible.

of the litters ensured that the mothers did not reject their offspring.

#### Morphological studies

Animals were killed in pairs at daily intervals. They were decapitated, the dorsal skin shaved where necessary, and a portion of approximately 1 cm<sup>2</sup> was placed flat on filter paper and fixed in phosphate-buffered formalin. The tissue was prepared routinely for histology, and paraffin wax sections (5 µm) were stained with haematoxylin and eosin (HE).

For the autoradiographic study, the mice were injected ip. one hour before killing, with [5-H<sup>3</sup>-Me]thymidine (Amersham, Bucks, England; 5.0 Ci/mM or 185 GBq/mM), at a dose rate of 0.5 µCi (185 kBq) per gram body weight. Paraffin wax sections (5 µm) were dipped in Ilford K5 autoradiographic emulsion, exposed for 4 weeks and developed with Kodak D19 fine grain developer. Nuclear-fast red and picric acid were used as counterstains. Pieces of the small intestine from each animal were used as radio-labelling controls.

Using light microscopy, recognition of mitotic figures and the presence in autoradiographs of [<sup>3</sup>H]thymidine-labelled follicular cells were used as indicators of anagen. Appearance of apoptosis, and the cessation of autoradiographic labelling in the follicles were used to recognise catagen. Apoptosis was seen as rounded eosinophilic structures of various sizes that contained one or more pyknotic nuclear fragments, or as slightly shrunken whole cells in which the nucleus showed distinctive margination of chromatin (6, 7).

## RESULTS

### The normal follicular cycle

**A. In Herston white mice:** As the anagen growth phase progressed, mice were covered with terminal hairs by day 10. Fig. 1 *a, b* show the histological appearances of follicles at days 0 and 10, respectively. Using autoradiography, numerous labelled cells were found at these times (Fig. 2 *a, b*). Anagen proceeded until day 15. The onset of catagen at day 16 was marked by the complete cessation of [<sup>3</sup>H]thymidine labelling in the regressing follicular matrices, and the appearance of apoptosis. At days 16 and 17, these follicles were markedly decreased in size (Fig. 3 *a*), and contained large numbers of apoptotic cells (Fig. 3 *b*). Recognisable features of apoptosis included: cell shrinkage with cytoplasmic eosinophilia and nuclear pyknosis; condensation and margination of chromatin against the nuclear membrane, often into a crescentic mass; and presence of discrete apoptotic bodies which had often been ingested by adjacent cells, and which usually contained obvious nuclear fragments (7, 8, 10).

Mitotic activity and autoradiographic labelling in-

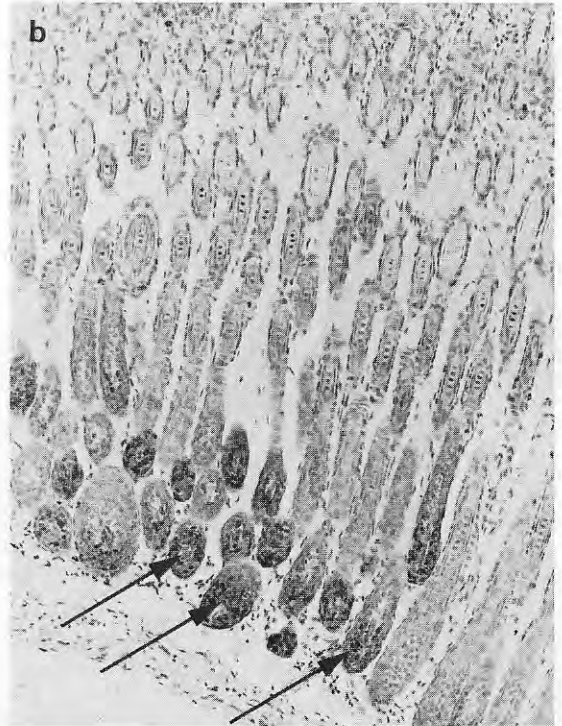
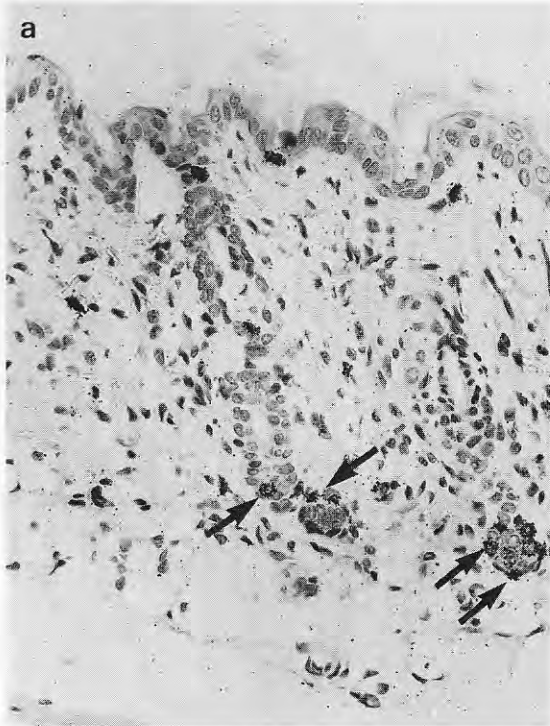


Fig. 2. Autoradiography of the skin, demonstrating anagen phase in the hair follicle growth cycle: (a) At day 0.  $\times 400$ ; (b) At day 10.  $\times 240$ . Rapidly dividing cells label intensely with

$[^3\text{H}]$ thymidine (arrows). Counterstained with nuclear-fast red and picric acid.

indicated commencement of the next anagen phase, at day 19, by which time apoptotic bodies were no longer evident.

**B. In *HRA/Skh1* hairless mice (Type 1, albino):** This inbred strain is homozygous for the 'hairless' mutant gene. Hair growth initially proceeded in a manner identical with that in the Herston white mice. At day 14, however, hair loss started around the eyes and head. This proceeded down the body, so that by day 16 to 17 the dorsal skin was losing hair and by day 20 the mice lacked terminal hairs entirely.

The sequence of microscopic changes in the dorsal skin was identical with that in the Herston white mice, except that the second anagen phase of hair growth did not occur, and the shrunken hair follicles remained in the telogen, or resting phase.

#### *Follicular cycle after treatment with minoxidil*

Histology from daily collections of dorsal skin was compared, for minoxidil-treated, sham-treated, and control groups. Using criteria for recognition of anagen and catagen phases of the hair growth cycle stated

previously, no differences were found in the timing of these phases amongst all groups, in either strain of mice. A qualitative assessment was found to be satisfactory, because the dramatic and observable changes in histological appearances facilitated the recording of cessation of anagen and onset of catagen.

#### DISCUSSION

This study focused on anagen and catagen phases in the hair growth cycle, using distinctive histological markers for each phase. It was of particular interest that catagen could be characterised by apoptotic deletion of matrical cells. Treatment of androgenic alopecia, and sometimes alopecia areata, with topical minoxidil has been widely reported (12–15). One theory on its method of action is that it causes a change in the hair growth cycle (2–5) with prolongation of anagen, and thus delay in onset of catagen.

In the present study, daily application of minoxidil was made to the dorsal skin of two strains of mice, before and after a time when a spontaneous moult is



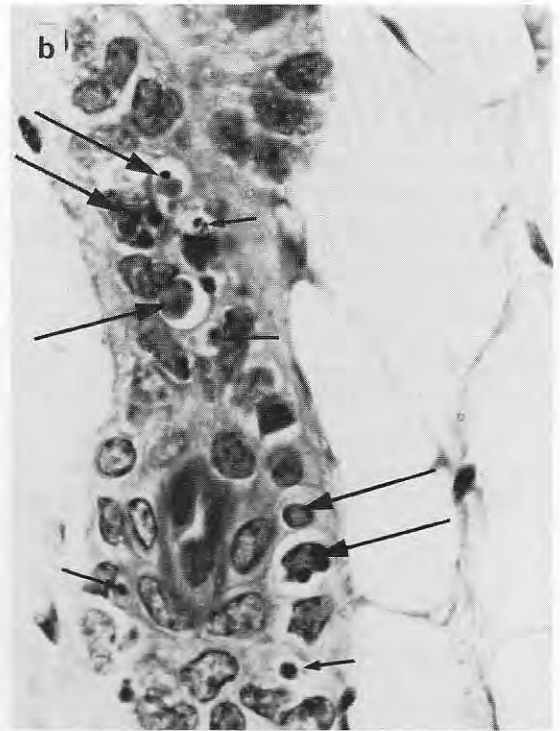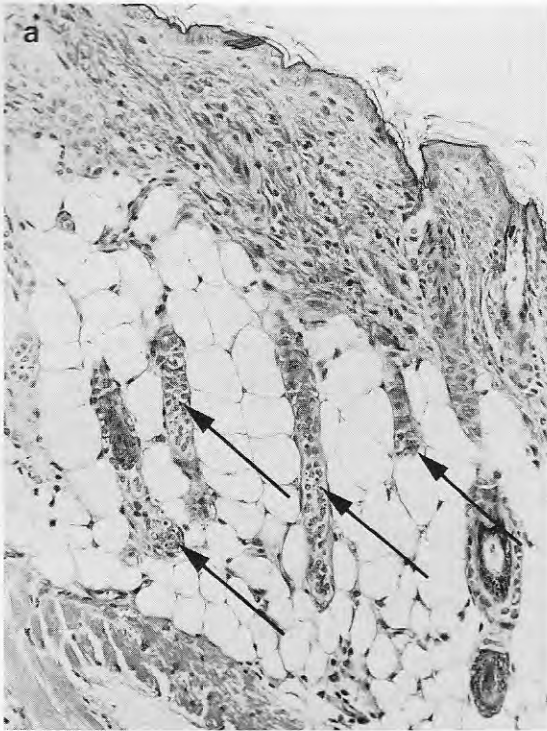


Fig. 3. Catagen involution of the hair follicles at days 16–17: (a) Follicles are markedly reduced in size and some apoptosis is apparent (arrows).  $\times 400$ , HE. (b) Some features typical of apoptosis can be seen with high-power light microscopy.

These include shrunken eosinophilic cells with margination and condensation of the nuclear chromatin (large arrows), and discrete apoptotic bodies phagocytosed by adjacent cells (small arrows).  $\times 960$ , HE.

known to occur. Topical minoxidil did not prolong anagen nor delay catagen in these experiments. The concentration of minoxidil used by us may have been too low, as its absorption in experimental animals may be slightly less than in humans (16). We have found no histological differences, however, in a pilot study using a 5% minoxidil lotion on Herston white mice. The possibility that minoxidil-induced stimulation of hair follicles may be specific to humans or closely-related species must also be considered.

The use of apoptosis as a distinctive marker for catagen should not, however, be underestimated (17). The criteria for identification of apoptosis are well-described (6, 7). Presence of apoptosis has been noted within follicles in catagen: in the human, at the advancing edges of some alopecias, and in trichotillomania (10); in sheep, after depilatory infusions of mouse epidermal growth factor (18); and in other examples of follicular regression (8, 9). As an indicator of catagen involution, apoptosis could have im-

portant applications in other dermatopathological research.

## REFERENCES

1. Zappacosta AR. Reversal of baldness in a patient receiving minoxidil for hypertension. *N Engl J Med* 1980; 18: 1480–1481.
2. Baden HP, Kubilus J. Effect of minoxidil on cultured keratinocytes. *J Invest Dermatol* 1983; 82: 515–517.
3. Cohen RL, Alves MEAF, Weiss VC, et al. Direct effects of minoxidil on epidermal cells in culture. *J Invest Dermatol* 1984; 82: 90–93.
4. Uno H, Capps A, Schlager C. Cyclic dynamics of hair follicles and the effect of minoxidil on the bald scalps of stump-tailed macaques. *Am J Dermatopathol* 1985; 7: 283–297.
5. Uno H, Capps A, Brigham P. Action of topical minoxidil on the bald stump-tailed macaque. *J Am Acad Dermatol* 1987; 16: 657–668.
6. Kerr JFR, Searle J, Harmon BV, Bishop CJ. Apoptosis. In: Potten CS, ed. *Perspectives on Mammalian Cell Death*. Oxford: Oxford University Press, 1987; 93–128.

7. Walker NI, Harmon BV, Gobé GC, Kerr JFR. Patterns of cell death. *Meth Achiev Exp Path* 1988; 13: 18–54.
8. Olson RL, Everett MA. Epidermal apoptosis: Cell deletion by phagocytosis. *J Cutan Pathol* 1975; 2: 53–57.
9. Weedon D, Strutton G. Apoptosis as the mechanism of the involution of hair follicles in catagen transformation. *Acta Derm Venereol (Stockh)* 1981; 61: 335–339.
10. Weedon D, Strutton G. The recognition of early stages of catagen. *Am J Dermatopathol* 1984; 6: 553–555.
11. Ling JK. Pelage and molting in wild animals, with special reference to aquatic forms. *Q Rev Biol* 1970; 45: 16.
12. Headington JT, Novak E. Clinical and histological studies of male pattern baldness treated with topical minoxidil. *Curr Ther Res* 1984; 36: 1098–1106.
13. Frenzt G. Topical minoxidil for extended areata alopecia. *Acta Derm Venereol (Stockh)* 1985; 65: 172–175.
14. De Villez RL. Androgenic alopecia treated with topical minoxidil. *J Am Acad Dermatol* 1987; 16: 669–672.
15. Savin RC. Use of topical minoxidil in the treatment of male pattern baldness. *J Am Acad Dermatol* 1987; 16: 696–704.
16. Novak E, Franz TJ, Headington JT, Wester RC. Topically applied minoxidil baldness. *Int J Dermatol* 1985; 24: 82–87.
17. Weedon D, Searle J, Kerr JFR. Apoptosis: Its nature and implications for dermatopathology. *Am J Dermatopathol* 1979; 1: 133–144.
18. Hollis DE, Chapman RE. Apoptosis in wool follicles during mouse epidermal growth factor (MEGF)-induced catagen regressen. *J Invest Dermatol* 1987; 88: 455–458.