

SHORT COMMUNICATION

Lipoid Proteinosis Resulting from a Large Homozygous Deletion Affecting Part of the *ECM1* Gene and Adjacent Long Non-coding RNAMing-Yang Lee^{1,2#}, Hui-Jun Wang^{1-4#}, Ying Han^{5#}, Yun Zhou⁶, Jia-Hui Zhao^{1,2}, Li-Na Duo¹⁻³, Cheng Feng^{1,2}, Hong Hua⁵, Hong-Wei Liu⁵, Zhi-Miao Lin^{1,2*} and Yong Yang¹⁻³¹Department of Dermatology, Peking University First Hospital, Beijing 100034, ²Beijing Key Laboratory of Molecular Diagnosis on Dermatoses, ³Peking-Tsinghua Center for Life Sciences, ⁴Academy for Advanced Interdisciplinary Studies, ⁵Department of Oral Medicine, School and Hospital of Stomatology, Peking University, Beijing, ⁶Department of Dermatology, The First Affiliated Hospital of Nanchang University, Nanchang, China. E-mail: zhimiaolin@bjmu.edu.cn

#These authors contribute equally to this work and should be considered as first authors.

Accepted Nov 18, 2014; Epub ahead of print Dec 18, 2014

Lipoid proteinosis (LP, OMIM 247100), also known as Urbach-Wiethe disease, is a rare autosomal recessive multisystem disorder which is characterised by various degrees of scarring and hyaline-like deposition. LP primarily involves skin and mucosae membranes of upper aerodigestive tract, leading to hoarseness, dysphagia, abnormal tongue movement, and in severe cases respiratory difficulty (1, 2). Histologically, LP is characterised by widespread intercellular deposits of periodic acid-Schiff (PAS)-positive hyaline material in the dermis (2). The genetic cause of LP has been mapped to the extracellular matrix protein 1 (*ECM1*) gene on chromosome 1q21.2 (3). Among 50 mutations reported to date, 9 are missense, 16 are nonsense, 6 are splicing variants and 19 are in- or out-of-frame insertions or deletions (<100 bp, except for an 1163-bp deletion) (3). Here we report a germline 5141-bp deletion spanning 76% of *ECM1* coding sequence and 28% of the neighbouring long intergenic non-coding RNA a1 (ncRNA-a1) in a consanguineous Chinese family.

CASE REPORT

The proband was a 22-year-old Chinese Han man born to consanguineous first-cousin parents (Fig. 1a). At the age of 7 months, he presented with recurrent, generalised blistering and pustules with erosions involving skin and oral mucosae which was diagnosed as “impetigo”. Most of the skin lesions resolved spontaneously within 2 weeks with scarring, despite several episodes of recurrence documented until the age of 8 years. His oral erosions persisted following the onset, and he had restricted mouth opening and a hoarse voice. Progressive scalp alopecia developed in the first year of life. He had no history of neurological or psychiatric deficits. The parents were clinically unaffected.

On examination, waxy beaded papules were observed on the margins of both upper eyelids and left nasolabial fold (Fig. 1b). Several acneiform atrophic scars were noted on his face and nape. Skin thickening was prominent on his forehead (Fig. 1c). Bilateral punctate hyperkeratotic papules dispersed on his hands and feet, some of which coalesced into plaques. He had diffuse alopecia on his scalp, which accentuated on the parietal and occipital regions (Fig. 1c). Skin pigmentation and nails were normal.

Intraoral examination revealed yellow-white infiltrations on his oral mucosae, gingival overgrowth and hypodontia (Fig. 1d). His lips, tongues and buccal mucosae were thickened with reduced movement (Fig. 1e). Laboratory investigations showed elevated serum protein level (81 g/l) and creatine kinase (270 U/l). Complete blood count and liver function tests were within normal limits.

Histopathology of biopsies taken from his tongue revealed hyperkeratosis with acanthosis and elongated rete ridges. In the lamina propria of his buccal mucosae, there was diffuse deposition of hyaline-like material positive for PAS staining and negative for Congo red staining, indicating the presence of glycoproteins. PAS staining also revealed thickening of the basal membrane (data not shown).

This study was approved by the Clinical Research Ethics Committee of Peking University First Hospital. All family members provided written informed consent for participation. Genomic DNA was extracted from peripheral blood of the patient and parents. Ten exons and flanking sequences of *ECM1* were amplified by PCR using intronic primers, followed by gel purification and direct sequencing.

While no pathogenic mutations were found in *ECM1* exons 1–5, primers specific for exons 6–10 failed to produce any amplicons in the patient but were able to amplify those of a normal control, suggesting a possible homozygous deletion. To find the deletion breakpoints, we employed PCR-based strategies with multiple

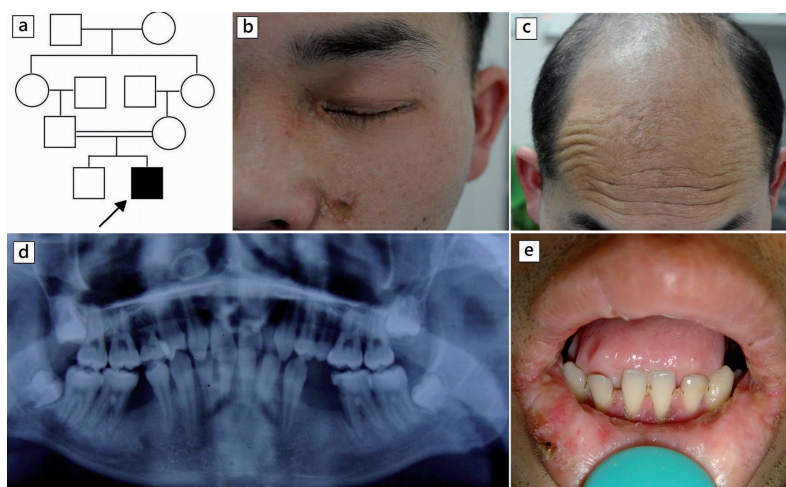


Fig. 1. Clinical findings of the patient. (a) Pedigree of the family with lipid proteinosis. The proband is indicated by an arrow. (b) Waxy beaded papules on his upper eyelid margin and left nasolabial fold. Acneiform atrophic scar is also present. (c) Prominent skin thickening and alopecia on his forehead. (d) X-ray showing hypodontia. (e) Gingival overgrowth and thickening of his lips and tongue with indentations. He had suffered reduced movement and restricted mouth opening.

mutation-specific primers. As a result, a 628-bp PCR amplicon spanning the breakpoints was obtained in the patient and his parents, but not in a normal control (Fig. S1¹). Direct sequencing of the amplicon revealed a homozygous 5141-bp (chr1:150483249–150488389) deletion in the patient (Fig. S2a¹), which encompassed exons 6–10, their flanking introns, and 3'-untranslated region of ECM1, along with the first 157 bp of ncRNA-a1 (non-coding RNA located ~2kb downstream of ECM1, also known as LINC00568) (Fig. S2b¹). This deletion probably resulted in frameshift and a premature termination, leading to nonsense-mediated decay of ECM1 mRNA. This mutation was heterozygous in his parents, but absent in 100 ethnic-matched healthy individuals.

DISCUSSION

While LP is a heterogeneous disorder with a wide phenotypic spectrum including skin and mucosal lesions, otorhinolaryngological and neuropsychiatric conditions, this disease appears to invariably manifest in the first few years of life with hoarseness, skin lesions and a thickened/shortened tongue (2, 4), as present in our patient. However, his hypodontia and gingival overgrowth are uncommon in LP (5). While LP can be complicated by enamel hypoplasia (6) and hyperdontia (7), to our knowledge the only reported case with hypodontia is an Indian girl, who also suffered dental carries due to hyposalivation (8). Another uncommon symptom in our patient is diffuse scalp alopecia, whose progressive course is consistent with the notion that the skin scarring and infiltration could worsen with age (4). Interestingly, a previous study showed that varying levels of alopecia affected 4 of 26 South African subjects (9), whereas only 1 in 10 LP subjects (Asian/European/North American) had alopecia in another study (4).

ECM1, located on chromosome 1q21, has 2 major splice variants expressed in epidermal keratinocytes and upper respiratory tract, namely 540-aa ECM1a and 415-aa ECM1b (lacking exon 7), though ECM1a had much wider expression profiles (10). ECM1 is a secreted basal membrane protein that binds to multiple proteins as a 'biological glue' (11), and functions to regulate the assembly of basement membrane and interstitial collagen fibrils, along with epidermal differentiation (12). The above protein-protein interactions are mediated by the conserved CC-(X₇₋₁₀)-C motif located in ECM1 cysteine-containing domains (residues 151–540) (10). We reason that the 5141-bp deletion completely disrupts the cysteine-containing domains in all 3 *ECM1* isoforms and can abolish the binding sites for laminin-332, matrix metalloproteinase-9, and perlecan (11). The possible resultant down-regulation of matrix metalloproteinase-9 activity (functioning to degrade laminins and collagens) causes aberrant increase of these molecules in the dermis (11), which could explain the characteristic LP-associated histological findings of hyaline material deposits and clinical manifestations.

The mutation also deleted part of the ncRNA-a1, which belongs to a class of non-coding RNAs that have recently been linked to epigenetic control of chromatin, X-chromosome inactivation, imprinting, along with the regulation of epidermal differentiation (13). In mammalian skin, these RNAs have been confirmed to regulate the pathogenesis of melanoma, ultraviolet-induced skin injury and psoriasis (13). By phorbol ester-induced keratinocyte differentiation and siRNA experiments, Ørom and colleagues (14) showed that full-length ncRNA-a1 could positively regulate the neighbouring *ECM1* in an enhancer-like manner, whereas shortened ncRNA-a1 had decreased regulatory functions. Therefore, we deduce that, in our patient, loss of ~28% of ncRNA-a1 sequence is likely to decrease the transcription level of the already mutated *ECM1*. However, whether the joint deletion has contributed to the aforementioned uncommon LP phenotypes (alopecia and hypodontia) is yet to be elucidated.

ACKNOWLEDGEMENTS

We thank the patients and family members who participated in this study. This work was supported by National Natural Science Foundation of China (Grant No. 81201220 and 81271744).

The authors declare no conflict of interest.

REFERENCES

- Urbach E, Wiethe C. Lipoidosis cutis et mucosae. *Virchows Arch A Pathol Pathol Anat* 1929; 273: 285–319.
- Chan I, Liu L, Hamada T, Sethuraman G, McGrath JA. The molecular basis of lipoid proteinosis: mutations in extracellular matrix protein 1. *Exp Dermatol* 2007; 16: 881–890.
- Hamada T, McLean WH, Ramsay M, Ashton GH, Nanda A, Jenkins T, et al. Lipoid proteinosis maps to 1q21 and is caused by mutations in the extracellular matrix protein 1 gene (*ECM1*). *Hum Mol Genet* 2002; 11: 833–840.
- Hamada T, Wessagowit V, South AP, Ashton GH, Chan I, Oyama N, et al. Extracellular matrix protein 1 gene (*ECM1*) mutations in lipoid proteinosis and genotype-phenotype correlation. *J Invest Dermatol* 2003; 120: 345–350.
- Sargenti Neto S, Batista JD, Durighetto AF, Jr. A case of oral recurrent ulcerative lesions in a patient with lipoid proteinosis (Urbach-Wiethe disease). *Br J Oral Maxillofac Surg* 2010; 48: 654–655.
- Lupo I, Cefalu AB, Bongiorno MR, Daniele O, Valenti V, Noto D, et al. A novel mutation of the extracellular matrix protein 1 gene (*ECM1*) in a patient with lipoid proteinosis (Urbach-Wiethe disease) from Sicily. *Br J Dermatol* 2005; 153: 1019–1022.
- Marta S, Marta G, Castilho A, Matsumoto M, Francischone L, Bresola M, et al. Lipoidoproteinose. *Revista Paulista de Pediatria* 2008; 26: 300–303.
- Mainali S, Nayak R, Gaur S. Oral findings in a child with lipoid proteinosis: a case report and review. *J Indian Soc Pedod Prev Dent* 2011; 29: 62–67.
- Scott F. Hyalinosis cutis et mucosae (lipoid proteinosis). *S Afr Med J* 1960; 34: 189–195.
- Smits P, Ni J, Feng P, Wauters J, Van Hul W, Boutaibi ME, et al. The human extracellular matrix gene 1 (*ECM1*):

¹<https://doi.org/10.2340/00015555-2036>

- genomic structure, cDNA cloning, expression pattern, and chromosomal localization. *Genomics* 1997; 45: 487–495.
11. Sercu S, Zhang M, Oyama N, Hansen U, Ghalbzouri AE, Jun G, et al. Interaction of extracellular matrix protein 1 with extracellular matrix components: ECM1 is a basement membrane protein of the skin. *J Invest Dermatol* 2008; 128: 1397–1408.
 12. Smits P, Poumay Y, Karperien M, Tylzanowski P, Wauters J, Huylebroeck D, et al. Differentiation-dependent alternative splicing and expression of the extracellular matrix protein 1 gene in human keratinocytes. *J Invest Dermatol* 2000; 114: 718–724.
 13. Hombach S, Kretz M. The non-coding skin: exploring the roles of long non-coding RNAs in epidermal homeostasis and disease. *Bioessays* 2013; 35: 1093–1100.
 14. Ørom UA, Derrien T, Beringer M, Gumireddy K, Gardini A, Bussotti G, et al. Long noncoding RNAs with enhancer-like function in human cells. *Cell* 2010; 143: 46–58.