

SHORT COMMUNICATION

Deep Cutaneous Infection with *Microspphaeropsis arundinis*: Report of two Japanese CasesAkihiko Asahina^{1,2}, Miwa Kobayashi³, Kazuaki Nakano⁴, Ikuo Saito⁵, Kyoko Yarita⁶, Katsuhiko Kamei⁶ and Yoshiki Tokura⁷¹Department of Dermatology, The Jikei University School of Medicine, 3-25-8 Nishi-Shimbashi, Minato-ku, Tokyo, 105-8461, ²Department of Dermatology, ⁴Clinical Laboratory, and ³Pathology, National Hospital Organization Sagami National Hospital, Kanagawa, ⁵Department of Dermatology, University of Occupational and Environmental Health, Fukuoka, ⁶Medical Mycology Research Center, Chiba University, Chiba, and ⁷Department of Dermatology, Hamamatsu University School of Medicine, Hamamatsu, Japan. E-mail: asahina-ky@umin.ac.jp

Accepted Mar 3, 2015; Epub ahead of print Mar 10, 2015

Coelomycetes are asexual fungi which produce their conidiospores within fruiting structures known as conidiomata. They are ubiquitous in soil and freshwater environments, and recognized as plant pathogens (1, 2). Although human infections with coelomycetous fungi are exceedingly rare, some may cause an opportunistic soft tissue infection, particularly as phaeohyphomycosis, in immunocompromised hosts (1, 3). We recently experienced 2 independent Japanese cases of infection by *Microspphaeropsis arundinis*, a coelomycete fungus (2). This is the first report of *M. arundinis* infection in Asia.

cessfully (Fig. 1 i, j). *M. arundinis* was identified by DNA amplification and sequencing analysis. CT was unremarkable.

As for treatment, tacrolimus was stopped, and itraconazole at a reduced dose of 100 mg/day was continued for 3 weeks because of liver dysfunction, and then switched to fluconazole 100 mg/day for 5 weeks, followed by liposomal amphotericin B 135 mg/day for 2 weeks, but they were found ineffective. The serum β -D-glucan level increased to 191.8 pg/ml (normal 0–20 pg/ml) (Fig. S1a¹). After cessation of antifungal agents, local thermotherapy was initiated and continued for 10 weeks using inexpensive portable chemical pocket warmers (4) at 40–50°C \times 24 h/day. The lesions then showed significant improvement, and resolved

CASE REPORTS

Case 1. A 57-year-old woman living in Fukuoka prefecture had a 6-month history of an ulcerative plaque on the dorsum of her left middle finger. She developed erythematous scaling nodules and plaques on her left forearm, abdomen, left knee and lower leg (Fig. 1a–c). She had been suffering from systemic lupus erythematosus and autoimmune hepatitis for 4 years, and was being treated with oral methylprednisolone 6 mg/day, prednisolone 1 mg/day and tacrolimus 3 mg/day. KOH specimen showed a large number of hyphae in the scale. Biopsy showed abscess formation surrounded by multinuclear giant cells and epithelioid histiocytes, and numerous spores and hyphae were detected (Fig. 1e,f). Culture specimen from disseminated lesions showed a villous grayish brown-green colony on potato dextrose agar (PDA), growing at 25°C, but not at the temperature higher than 35°C (Fig. 1g). Pycnidia, a type of conidiomata filled with conidiospores with an opening in the top portion, were observed only inside the agar of a PDA slant (Fig. 1h). We also grew the fungus on carnation leaf agar suc-

¹<https://doi.org/10.2340/00015555-2091>

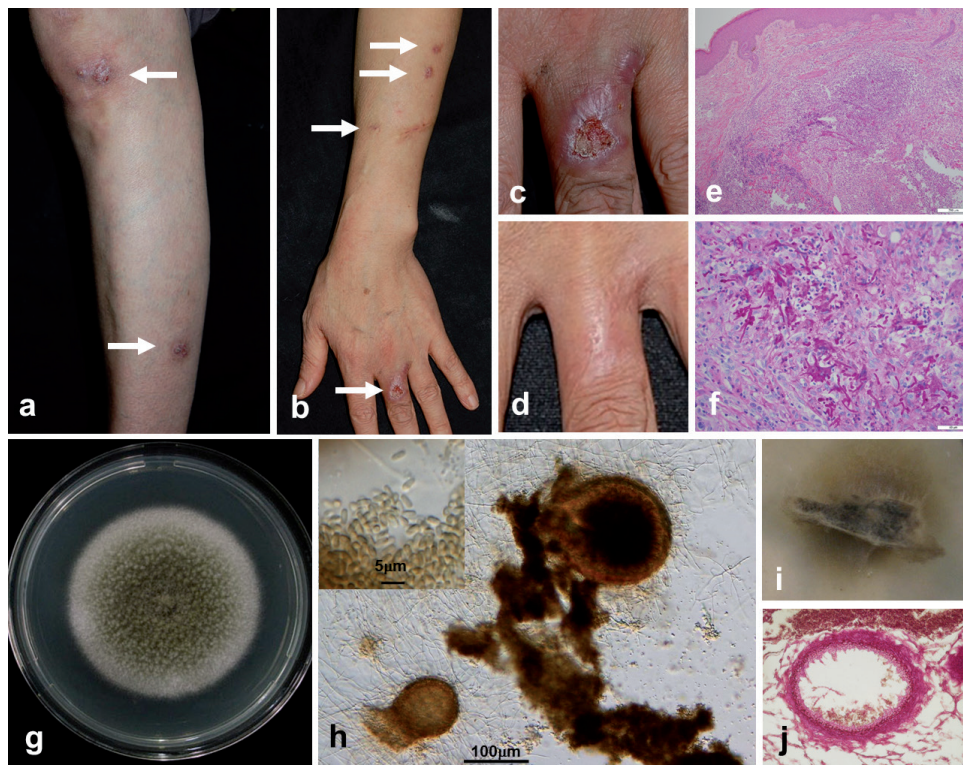


Fig. 1. Clinical, histological, and mycological features of Case 1. (a, b) Multiple erythematous scaling nodules and plaques on the left leg (a) and the left forearm (b) (depicted by arrows). A postoperative scar on the arm indicates the site of biopsy. (c) An ulcerative plaque on the dorsum of the proximal phalanx of left middle finger. (d) Complete resolution after 15 months. (e) Biopsy specimen showing abscess formation surrounded by multinuclear giant cells and epithelioid histiocytes. (hematoxylin-eosin, original magnification \times 100). (f) Demonstration of spores and hyphae in the granuloma (Periodic acid-Schiff staining; original magnification \times 400). (g) A villous grayish brown-green colony on potato dextrose agar (PDA) grown at 25°C (10 days). (h) Pycnidia formation filled with conidiospores (inset) on PDA slant. (i, j) Implantation of the fungus on carnation leaf agar, with subsequent observation of pycnidia as small black dots (29 days) (i) and their demonstration by microscopy (j).

completely within one year (Fig. 1d) together with a decline in the serum β -D-glucan level (Fig. S1a¹).

Case 2. A 74-year-old woman living in Kanagawa prefecture presented with an erythematous indurated plaque of 2-month duration on the dorsum of her left hand, with smaller papules and plaques on the adjacent area (Fig. 2a). She had been suffering from recalcitrant temporal arteritis for 2 years, and because of hypogammaglobulinemia caused by medication with methylprednisolone, she received 4 courses of intravenous immunoglobulin therapy. On presentation, she was on methylprednisolone 10 mg/day and methotrexate 6 mg/week. Blood examination showed low serum immunoglobulin levels, represented by IgG at 466 mg/dl (normal 870–1,700 mg/dl). Mild secondary diabetes mellitus with HbA1c level of 6.9 % (normal 4.6–6.2 %) was noted, and the serum β -D-glucan level was elevated to 59.4 pg/ml (Fig. S1b¹). Biopsy showed an irregular skin surface with pseudoepitheliomatous hyperplasia. There was massive granuloma formation without caseation necrosis and infiltration of inflammatory cells, including numerous epithelioid histiocytes and multinucleated giant cells (Fig. 2c). Fungal elements were detected (Fig. 2d). A pale gray villous fungal colony grew on PDA, but the fungus failed to form conidia. *M. arundinis* was identified by molecular analysis. No visceral involvement was found by CT imaging.

Our initial diagnosis was sporotrichosis, and so we used potassium iodide 900 mg/day and recommended less stringent local thermotherapy with pocket heaters, but the lesion was only slightly improved after 6 weeks. At that time, the infection was diagnosed as phaeohyphomycosis, and we started treatment with itraconazole 200 mg/day and continued for 8 months, while maintaining local thermotherapy. The lesion significantly regressed in parallel with a decline in the serum β -D-glucan level (Fig. S1b¹), leaving a hypertrophic scar at the periphery of the plaque (Fig. 2b).

DISCUSSION

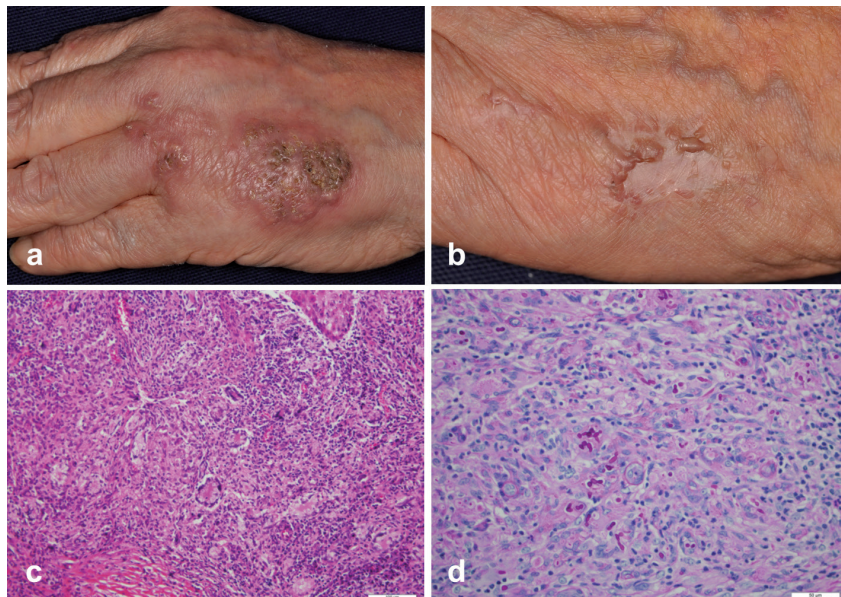
The diagnosis of a coelomycetous fungal infection is challenging. In case 1, the fungus formed pycnidia with conidiospores by *in vitro* culture. However, diagnostic overlap exists in the morphological characteristics among coelomycetes (1), and in case 2, the obtained cultures

failed to produce pycnidia (1). Molecular characterization (2, 3) was thus the most practical approach to identify *M. arundinis*. There have been few reports of human infection with *Microspphaeropsis* species, and more specifically, only 5 confirmed infected cases can be found in the English literature (2, 5), including ours (Table S1¹). These patients were all under treatment with immunosuppressant medications, including corticosteroids. Deficiency of humoral immunity was also noted in our case 2.

Coelomycetes are implanted into human skin through trauma (1). Indeed, the sites of predilection of *M. arundinis* include the dorsum of hands. Three out of 5 cases of *M. arundinis* infection, including our case 1, had multiple lesions, suggesting lymphatic dissemination. Although our patients did not recall trauma, their routine activities included caring for garden plants also noted in patients infected with *Phoma* species (6).

Current treatment options include surgical excision, antifungal agents, and thermotherapy (3). Although previous studies have shown *in vitro* susceptibility of *M. arundinis* to itraconazole and amphotericin B (2), numerous other factors influence the outcome of treatment (1). Case 1 was refractory to multiple agents, but local heat application was useful even as a monotherapy, and case 2 also appeared to benefit from concomitant thermotherapy. Its effectiveness is established for sporotrichosis, and it is also used for phaeohyphomycosis, either as an adjuvant therapy or as a monotherapy for *Alternaria* (4) and *Exophiala* (7).

Interestingly, the serum β -D-glucan level was elevated and reflected the severity of the disease. This test can detect a wide range of invasive fungal infections in high-risk patients (8). Its diagnostic value in deep cutaneous fungal infection, however, is not well documented.



ACKNOWLEDGEMENT

We thank Dr. Kazuko Nishimura in First Laboratories Inc. and Dr. Hiroshi Tanabe in Kanazawa Medical University for making great contribution to the identification of the fungus in case 1.

Fig. 2. Clinical, histological, and mycological features of Case 2. (a) An erythematous indurated plaque with an irregular surface on the dorsum of the left hand, with smaller plaques and papules on the adjacent area. (b) Complete resolution at 10 months after starting oral itraconazole application. (c) Biopsy specimen showing prominent granuloma formation with inflammatory cells, epithelioid histiocytes and multinucleated giant cells. (hematoxylin-eosin, original magnification $\times 200$). (d) Demonstration of spores and hyphae, partly engulfed by giant cells (Periodic acid-Schiff staining; original magnification $\times 400$).

REFERENCES

1. Sutton DA. Coelomycetous fungi in human disease. A review: Clinical entities, pathogenesis, identification and therapy. *Rev Iberoam Micol* 1999; 16: 171–179.
2. Pendle S, Weeks K, Priest M, Gill A, Hudson B, Kotsiou G, Pritchard R. Phaeohyphomycotic soft tissue infections caused by the coelomycetous fungus *Microsphaeropsis arundinis*. *J Clin Microbiol* 2004; 42: 5315–5319.
3. Revankar SG, Sutton DA. Melanized fungi in human disease. *Clin Microbiol Rev* 2010; 23: 884–928.
4. Yasui M, Hattori M, Ikegami N, Kaga M, Ogawa Y, Hiruma M. A case of alternariosis successfully treated with local hyperthermia. *Mycoses* 2011; 54: e623–e626.
5. Hall MR, Brumble LM, Mayes MA, Snow JL, Keeling JH. Cutaneous *Microsphaeropsis arundinis* infection initially interpreted as squamous cell carcinoma. *Int J Dermatol* 2013; 52: 84–86.
6. Everett JE, Busick NP, Sielaff T, Wahoff DC, Dunn DL. A deeply invasive *Phoma* species infection in a renal transplant recipient. *Transplant Proc* 2003; 35: 1387–1389.
7. Fukai T, Hiruma M, Ogawa Y, Ikeda S, Ikeda H, Sano A, Makimura K. A case of phaeohyphomycosis caused by *Exophiala oligosperma* successfully treated with local hyperthermia. *Med Mycol J* 2013; 54: 297–301.
8. Ostrosky-Zeichner L. Invasive mycoses: diagnostic challenges. *Am J Med* 2012; 125: S14–S24.