

QUIZ SECTION

Dyskeratosis of the Face: A Quiz

Valérie Vuong¹, Gentiane Monsel¹, Bénédicte Cavalier-Ballo^{1,2}, Maxime Battistella², Evelyne Collet³, Martine Bagot¹, Nicole Basset-Seguin¹ and Manuelle Viguier^{1*}

¹Dermatology and ²Pathology Department, Hôpital Saint-Louis, Assistance Publique-Hôpitaux de Paris, Université Paris Diderot, 1 avenue Claude-Vellefaux, FR-75475 Paris, and ³Dermatology Department, Hôpital du Bocage, Dijon, France. *E-mail: manuelle.viguier@aphp.fr

A 53-year-old woman presented with a 10-month history of verrucous and hyperkeratotic plaques on the forehead, which had extended progressively to the cheekbones (Fig. 1A).

An initial skin biopsy was taken on the cheek, with pathological findings consistent with a diagnosis of warty dyskeratoma (Fig. 1B). *In situ* human papilloma virus (HPV) hybridization was negative on this biopsy. No improvement was shown after 2 months of acitretin, 25 mg/day. Additional biopsies on the extended lesions of the face identified dyskeratotic cells with some vacuolated keratinocytes evocative of HPV infection. Viral papilloma was suspected and she was treated with shaving, followed by topical application of imiquimod. Four months later, physical examination revealed emaciation, hyperkeratotic, superinfected plaques on the face with a lupoid distribution, erosive lesions on the gums, and vegetant vulvar and perianal lesions. The usual laboratory tests were normal.

What is your diagnosis? See next page for answer.

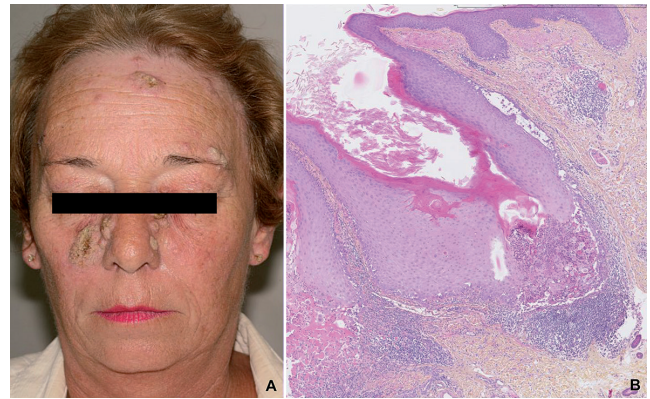


Fig. 1. (A) Verrucous and hyperkeratotic plaques on the forehead and cheekbones. (B) Pathological findings from a skin biopsy on the cheek showing hyperkeratosis and papillomatosis with some acantholysis and dyskeratosis (haematoxylin and eosin (H&E) staining; original magnification $\times 50$). A written permission from the patient is given to publish these photos.

ANSWERS TO QUIZ

Dyskeratosis of the Face: A Comment

Acta Derm Venereol

Diagnosis: Pemphigus vegetans

The patient's facial appearance after imiquimod application is shown in Fig. 2A. New biopsy from the cheek showed more pronounced suprabasal acantholysis with slight dyskeratosis in a hyperplastic epidermis (not shown). Direct immunofluorescence on lesional skin revealed suprabasal intercellular staining of IgG and C3, without staining on the basement membrane zone (Fig. 2B). Indirect immunofluorescence was negative on rat bladder substrate, but showed positive circulating intercellular IgG autoantibodies on monkey oesophagus substrate (1/100). Western immunoblotting, using epidermal extract antigen, detected autoantibodies to 130 kDa. This confirmed pemphigus vegetans (PV) initially misdiagnosed as warty dyskeratoma.

Oral prednisone therapy (1 mg/kg/day) for 3 months provided only partial improvement. The patient then received 2 infusions of rituximab (1 g each, at 15 days interval) that were efficient after 3 months. She was still in remission at one year with 2 supplementary infusions of rituximab (500 mg each) and 10 mg prednisone daily. Four years after the first lesions, the patient now receives 5 mg prednisone daily and topical corticosteroid because of the recurrence of a few vegetant lesions on the face, but all the mucosae are healed.

PV represents less than 2% of all cases of pemphigus vulgaris (1). Two clinical subtypes are described: the Neumann type is the most common, beginning with bullae and having a poor prognosis, whereas the Hallopeau type usually begins with pustules and has an excellent response to treatment (2). Both types are characterized by vegetant plaques in the skin folds (mainly the axillary, the inguinal and the perianal folds) (3–5) and on the mucosae (2, 6). Some cases of Hallopeau type PV have been described on the foot or on the scalp (7, 8).

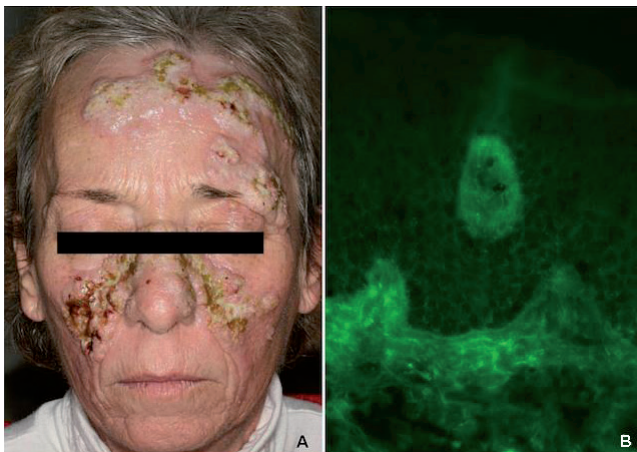


Fig. 2. (A) Four months later, after imiquimod application, hyperkeratotic, superinfected plaques on the face with a lupoid distribution. (B) Direct immunofluorescence: suprabasal intercellular staining of the epidermis with anti-IgG (original magnification $\times 400$).

Our patient's facial involvement with hyperkeratotic plaques following a lupoid distribution is unique in the literature, as is the absence of folds involvement. Another clinical particularity is the huge extended mucosal involvement with vegetant and erosive lesions on the gum, the vulva, and the oesophagus. The absence of eosinophilic microabscesses on skin biopsy is also notable.

Warty dyskeratoma is also characterized by location on the face, mucosal involvement, presence of epidermal hyperplasia and acantholysis on skin biopsy (9). However, epidermal hyperplasia is more pronounced and, clinically, the lesion is usually unique, with only a dozen cases of multiple warty dyskeratoma reported previously (9). Signs evocative of cytopathic HPV on the second biopsies misled us to diagnose viral papilloma. Shaving followed by topical application of imiquimod were then attempted but failed. Retrospective examination of the pathological slides identified that koilocytes corresponded rather to clarified keratinocytes. Some cases of imiquimod-induced pemphigus have been reported presumably caused by a potential stimulation of the production of inflammatory cytokines and induction of Th1-driven autoimmune conditions (10).

The authors declare no conflicts of interest.

REFERENCES

1. Cozzani E, Christana K, Mastrogiacomo A, Rampini P, Drosera M, Casu M, et al. Pemphigus vegetans Neumann type with anti-desmoglein and anti-periplakin autoantibodies. *Eur J Dermatol* 2007; 17: 530–533.
2. Joly P, Litrowski N. Pemphigus group (vulgaris, vegetans, foliaceus, herpetiformis, brasiliensis). *Clin Dermatol* 2011; 29: 432–436.
3. Saruta H, Ishii N, Teye K, Ono F, Ohyama B, Koga H, et al. Two cases of pemphigus vegetans with IgG anti-desmoglein 3 antibodies. *JAMA Dermatol* 2013; 149: 1209–1213.
4. Salah LA. Vegetating inguinal and perianal lesions: a quiz. *Acta Derm Venereol* 2015; 95: 507–509.
5. Dahbi N, Hocar O, Akhdari N, Amal S, Fakhri A, Rais H, et al. Pemphigus vegetans: rare form of pemphigus. *Presse Med* 2014; 43: 619–621.
6. Kershenovich R, Hodak E, Mimouni D. Diagnosis and classification of pemphigus and bullous pemphigoid. *Autoimmun Rev* 2014; 13: 477–481.
7. Mori M, Mariotti G, Grandi V, Gunnella S, Maio V. Pemphigus vegetans of the scalp. *J Eur Acad Dermatol Venereol* 2014 Oct 22. [Epub ahead of print].
8. Ma D, Fang K. Hallopeau type of pemphigus vegetans confined to the right foot: case report. *Chin Med J* 2009; 122: 588–590.
9. Kaddu S, Dong H, Mayer G, Kerl H, Cerroni L. Warty dyskeratoma “follicular dyskeratoma”: analysis of clinicopathologic features of a distinctive follicular adnexal neoplasm. *J Am Acad Dermatol* 2002; 47: 423–428.
10. Sebaratnam DF, Martin LK, Rubin AI, Tran K, Pas HH, Marr PJ, et al. Reversible relapse of pemphigus foliaceus triggered by topical imiquimod suggests that Toll-like receptor 7 inhibitors may be useful treatments for pemphigus. *Clin Exp Dermatol* 2011; 36: 91–93.