

SHORT COMMUNICATION

Effective Oral Psoralen Plus Ultraviolet A Therapy for Digital Ulcers with Revascularization in Systemic Sclerosis

Tomoko Inoue, Toshifumi Yamaoka*, Hiroyuki Murota, Akinori Yokomi, Atsushi Tanemura, Ken Igawa, Mamori Tani and Ichiro Katayama

Department of Dermatology, Osaka University Graduate School of Medicine, 2-2 Yamadaoka, Suita, Osaka 565-0871, Japan. *E-mail: yamaoka@derma.med.osaka-u.ac.jp

Accepted Apr 22, 2013; Epub ahead of print Aug 8, 2013

Systemic sclerosis (SSc) is a heterogeneous disorder characterized by excessive fibrosis and microvascular damage to the skin and various internal organs, including the lungs, kidneys, oesophagus and heart. Raynaud's phenomenon is an almost universal symptom of SSc; 95% of patients are affected. Digital ulcers are observed frequently, especially in intractable cases with severe Raynaud's phenomenon, and there is considerable morbidity, with gangrene and amputations (1).

To date, there is no promising treatment for severe cases of SSc that are complicated by digital ulcers. Apart from immunosuppressive drugs, administration of oral psoralen plus ultraviolet A (PUVA) therapy has been used in patients with SSc with progressive skin sclerosis complications, with some improvement (2).

We report here the first case of successful oral PUVA therapy in a patient with SSc complicated by progressive skin sclerosis and digital ulcers.

alone (up to 0.5 mg/kg) and cyclosporine (3 mg/kg) had been administered, we preferred to decrease or eliminate these drugs because of the risks of steroid-induced cataracts and reduced renal function, respectively. For the past 2 years, following the birth of her second child, her skin sclerosis and digital ulcers had continued to worsen, severely impairing her quality of life and daily activities, and the regular dose of prednisolone (0.3 mg/kg) was increased.

Thus, we decided to perform oral PUVA therapy. On admission, she was found to have a high titre of antinuclear antibodies with homogeneous, speckled, and nucleolar patterns ($\times 640$), increased anti-topoisomerase I antibody (97.5 U/ml), and anti-SS-A/Ro antibody (169 U/ml), although anti-centromere, U1-RNP, Sm, SS-B/La, and DNA autoantibodies were not detected. Regarding the protocol, she received 0.4 mg 8-methoxypsoralen (8-MOP, Oxsoralen, Methoxsalen, Taisho Toyama Pharmaceutical Co., Ltd., Tokyo) per kg body weight 2 h before systemic UV-A irradiation. Oral PUVA therapy was given 3 times per week for 4 weeks, for a cumulative dose of 23 J/cm². Clinical effect was evaluated with a site-matched biopsy derived from the forearm and the modified Rodnan total skin thickness score (MRSS) (3).

At the end of the period of PUVA therapy, the improvement in both the tension of her skin and digital ulcers (Fig. 1b) made her daily life more comfortable. Skin biopsy specimens before and after therapy showed a loosening of collagen bundles after oral PUVA therapy (Fig. 1c–f). In addition, immunofluorescence analysis of her skin revealed a significant difference in the num-

CASE REPORT

A 38-year-old Japanese woman who had suffered from diffuse cutaneous SSc for 20 years, presented with refractory skin sclerosis and digital ulcers (Fig. 1a). Although oral prednisolone

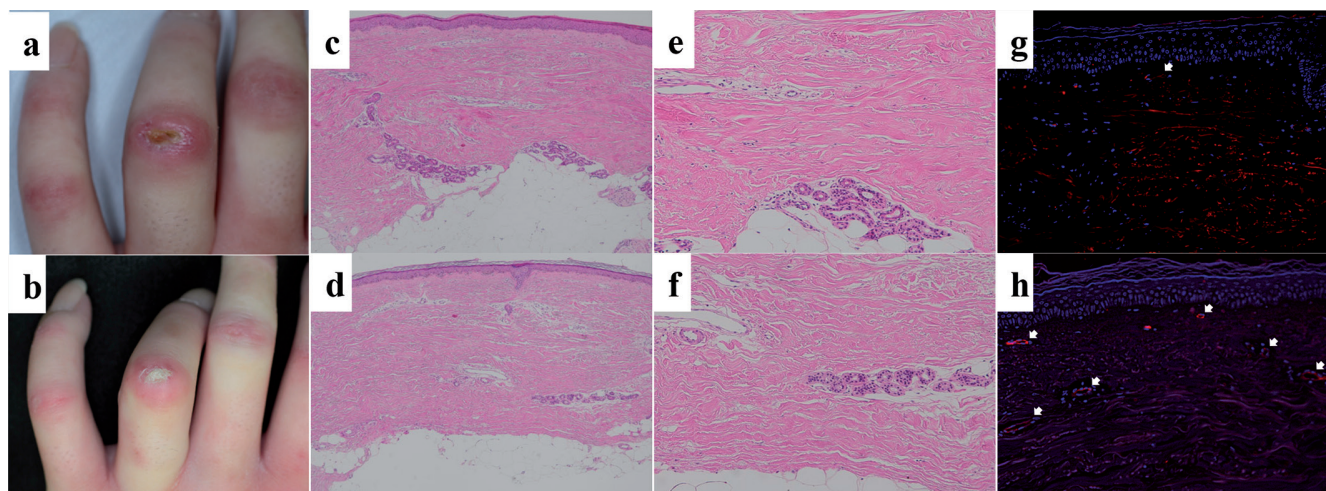


Fig. 1. (a) Before oral psoralen plus ultraviolet A (PUVA) therapy, there was a digital ulcer on the dorsal joint, whereas (b) after oral PUVA therapy, this ulcer improved. Histological examination of site-matched skin biopsy specimens (c, e, g) before and (d, f, h) after oral PUVA therapy. Biopsy specimens were taken from sclerotic lesional skin of the forearms. (e) Before oral PUVA therapy, thickened, homogeneous collagen bundles were visible, while (f) collagen bundles decreased after oral PUVA therapy. Double-staining with immunofluorescence for anti-CD34 (red, see arrows). Nuclear stain: Hoechst (blue). (g) Before oral PUVA therapy, few capillaries were visible, whereas (h) after oral PUVA therapy, more capillaries were seen. Haematoxylin and eosin staining, original magnification (c, d) $\times 40$, (e, f, g, h) $\times 100$.

bers of CD34⁺ cells (Fig. 1 g, h). The treatment was effective in reducing oedema and sclerotic changes, with a reduction in MRSS, from 32 to 15. The skin ulcer healed gradually after initiation of oral PUVA therapy, possibly related to revascularization. Following healing of the ulcer, oral PUVA therapy was continued once per month for 13 months, for a total cumulative dose of 47.7 J/cm².

DISCUSSION

We report here that oral PUVA therapy significantly improved not only progressive skin sclerosis but also refractory digital ulcers. Although the precise mechanism of action of oral PUVA therapy in SSc remains unknown, previous studies have shown that it decreases collagen synthesis associated with elevated tumour necrosis factor- α production (4), and that UVA irradiation induces the synthesis of matrix metalloproteinase-1, -2, and -3, resulting in accelerated degradation of collagen deposition in SSc (5).

Because activated myofibroblasts are thought to be key pathogenic cells in SSc, several experimental antifibrotic strategies have attempted to target activation, proliferation, and/or recruitment of fibroblasts. Although the exact mechanism of skin sclerosis in patients with SSc remains unclear, in this case the skin sclerosis and digital ulcers apparently improved in parallel, associated with revascularization. Hematopoietic stem cell transplantation or statin administration trigger circulating CD34⁺ bone marrow-derived progenitor cells, termed fibrocytes, to recruit and replace the myofibroblast pool at the site of fibrosis (6), in both humans and mouse

models of scleroderma. From these results, oral PUVA therapy induces revascularization and regeneration of myofibroblasts, providing clinical benefits in SSc.

In conclusion, this is the first report to show successful oral PUVA therapy in SSc complicated by progressive skin sclerosis and digital ulcers, possibly related to revascularization. Our findings indicate that oral PUVA therapy may be useful for patients with progressive skin sclerosis complicated by intractable digital ulcers.

REFERENCES

1. Denton CP, Krieg T, Guillevin L, Schwierin B, Rosenberg D, Silkey M, et al. Demographic, clinical and antibody characteristics of patients with digital ulcers in systemic sclerosis: data from the DUO Registry. *Ann Rheum Dis* 2012; 71: 718–721.
2. Hofer A, Soyer HP. Oral psoralen-UV-A for systemic scleroderma. *Arch Dermatol* 1999; 135: 603–604.
3. Clements PJ, Lachenbruch PA, Seibold JR, Zee B, Steen VD, Brennan P, et al. Skin thickness score in systemic sclerosis: an assessment of interobserver variability in 3 independent studies. *J Rheumatol* 1993; 20: 1892–1896.
4. Murota H, Hamasaki Y, Nakashima T, Yamamoto K, Katayama I, Matsuyama T. Disruption of tumor necrosis factor receptor p55 impairs collagen turnover in experimentally induced sclerodermic skin fibroblasts. *Arthritis Rheum* 2003; 48: 1117–1125.
5. Wlaschek M, Briviba K, Stricklin GP, Sies H, Scharffetter-Kochanek K. Singlet oxygen may mediate the ultraviolet A-induced synthesis of interstitial collagenase. *J Invest Dermatol* 1995; 104: 194–198.
6. Wynn TA, Ramalingam TR. Mechanisms of fibrosis: therapeutic translation for fibrotic disease. *Nat Med* 2012; 18: 1028–1040.