

QUIZ SECTION

Erythematous Protruding Skin Lesion in the Retroauricular Area: A Quiz

Kyung Eun Jung^{1,2}, Kyung Min Kim¹, Jun Young Lee¹, Hyung Ok Kim¹ and Young Min Park^{1*}

Departments of Dermatology, ¹College of Medicine, The Catholic University of Korea, Seoul St Mary's Hospital, 222 Banpo-Daero, Seocho-Gu, Seoul, 137-701, Korea, and ²College of Medicine, Eulji University, Eulji University Hospital, Daejeon, Korea. *E-mail: yymmpark6301@hotmail.com

A 31-year-old Korean man presented with an asymptomatic, easy-to-bleed, solitary, rapidly enlarging, and erythematous protruding skin lesion with a stalk on the posterior auricular area, which he had first noticed 6–7 weeks prior to visiting our clinic (Fig. 1). In June 2010, the patient had been diagnosed with chronic myelogenous leukaemia, which was treated first with hydroxyurea and, since September 2012, had been managed with oral radotinib, 600 mg/day. The patient had no history of trauma and denied any family history of similar skin lesions. Our initial impression was pyogenic granuloma or accessory tragus. A skin biopsy showed a proliferation of small-to-medium-sized blood vessels with a cobblestone

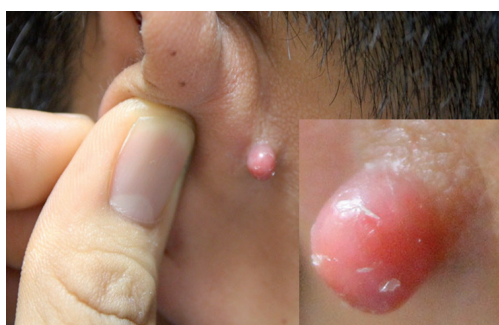

Fig. 1. Asymptomatic, solitary, 6–7-mm diameter, erythematous protruding nodule with a skin-coloured stalk located in the left posterior auricular region.

appearance of enlarged endothelial cells that projected into the lumina. A perivascular inflammatory cell infiltrate was composed mainly of lymphocytes and eosinophils (Fig. 2). The lesion has not recurred during 1-year follow-up after excision and electrodesiccation.

What is your diagnosis? See next page for answer.

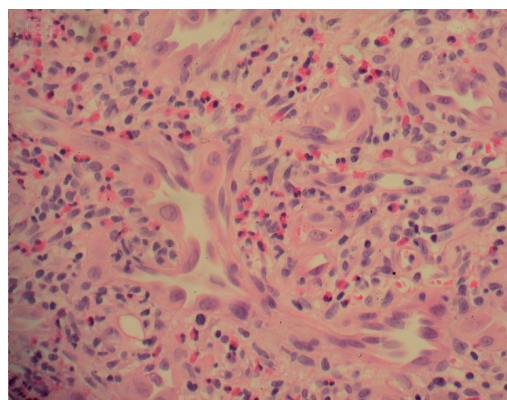


Fig. 2. Cobblestone appearance of enlarged endothelial cells that projected into the lumina, and perivascular inflammatory cell infiltrates composed mainly of lymphocytes and eosinophils (haematoxylin and eosin; $\times 400$).

doi: 10.2340/00015555-1628

ANSWERS TO QUIZ

Erythematous Protruding Skin Lesions in the Retroauricular Area: Comment

Acta Derm Venereol 2014; 94: 365–366.

Diagnosis: **Angiolymphoid hyperplasia with eosinophilia**

Angiolymphoid hyperplasia with eosinophilia (ALHE) is a rare angioproliferative disorder of unknown origin, characterized by solitary or multiple, usually 0.5–3 cm diameter, red-to-brown dome-shaped subcutaneous nodules, usually occurring on the head and neck, particularly in the auricular and periauricular areas, and very rarely on the extremities and trunk (1, 2). Histopathologically, ALHE shows a vascular proliferation of small vessels lined by plump endothelial cells, often accompanied by inflammatory infiltrates with numerous eosinophils and lymphocytes (1). The pathogenesis of ALHE is proposed as a neoplastic process, hypersensitivity reaction, inflammatory vascular reaction or tissue reaction to a previous trauma. Pyogenic granuloma, which is a common, benign vascular lesion, could be ruled out by characteristic histological features, showing lobular aggregates of capillaries and venules lined by plump endothelial cells with fibrous septa (3). Accessory

tragus can be differentiated, in that it showed a central plate of elastic cartilage, histologically, and is usually evident at birth (4). The most common therapeutic options are surgical excision and pulsed dye laser. In addition, cryotherapy, irradiation, intralesional steroid injection, and carbon dioxide laser have been reported as therapeutic options, with variable levels of success.

The present case has unusual clinical features, with a skin-coloured stalk connecting to surrounding normal skin.

REFERENCES

1. Koubaa W, Verdier M, Perez M, Wechsler J. Intra-arterial angiolymphoid hyperplasia with eosinophilia. *J Cutan Pathol* 2008; 35: 495–498.
2. Al-Muharrqi MA, Faqi MK, Uddin F, Ladak K, Darwish A. Angiolymphoid hyperplasia with eosinophilia (epithelioid hemangioma) of the face: an unusual presentation. *Int J Surg Case Rep* 2011; 2: 258–260.
3. Chen AY, Janik MP, Moad JC, Rubin MB. Multiple papules and nodules of the scalp. Angiolymphoid hyperplasia with eosinophilia (ALHE). *Arch Dermatol* 2010; 146: 911–916.
4. Jansen T, Romiti R, Altmeyer P. Accessory tragus: report of two cases and review of the literature. *Pediatr Dermatol* 2000; 17: 391–394.