

SHORT COMMUNICATION

Kindler Syndrome with Severe Intestinal Involvement: A 31-year Follow-up

Satoko Shimizu¹, Wataru Nishie², Kikuo Tsuchiya¹, Daisuke Inokuma¹, Hanako Koguchi-Yoshioka¹, Kazuhiro Kikuchi¹, Satoshi Motoya³, Hideki Nakamura² and Hiroshi Shimizu²

Departments of Dermatology, ¹Sapporo City General Hospital, North 11, West 13, Chuo-Ku, Sapporo, Hokkaido, 060-8604, ²Hokkaido University Graduate School of Medicine, and ³Department of Gastroenterology, Sapporo-Kosei General Hospital, Sapporo, Japan. E-mail: rxel10376@nifty.com

Accepted May 21, 2013; Epub ahead of print Sep 3, 2013

Kindler syndrome (KS) is an autosomal recessive genodermatosis characterised by trauma-induced blistering, poikiloderma, mucosal inflammation and varying degrees of photosensitivity (1, 2). It is caused by mutations in *FERMT1* (also known as *KIND1*), the gene encoding Kindlin1 (3, 4). More than 50 mutations have been reported to the Human Gene Mutation Database (HGMD® Professional Release 2012.4). In addition to the characteristic cutaneous features, KS patients occasionally have intestinal involvement, including diarrhoea or colitis, mainly in childhood (5, 6). However, severe intestinal complications of multiple ileal stenoses have seldom been described in KS patients, and it has remained unclear whether these are characteristics of KS or are coincidental.

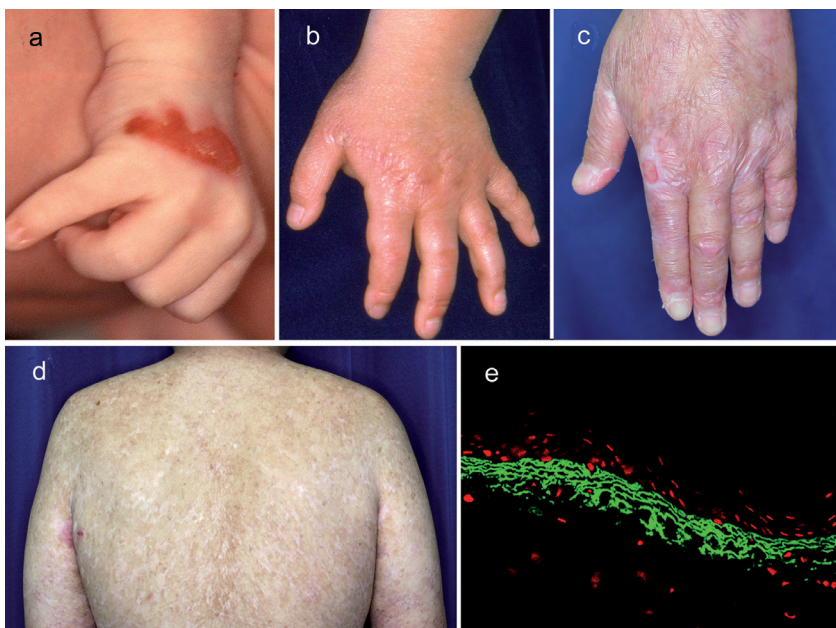
To further clarify the phenotype, genotype and *FERMT1*-expression of KS with severe intestinal involvement, we thoroughly evaluated a patient who has been carefully studied by dermatologists at a single institution for 31 years.

CASE REPORT

Clinical findings. The 31 year-old male patient presented multiple blisters and erosions at birth, which at that time were diagnosed as dystrophic epidermolysis bullosa. Both his non-consanguineous

parents and sister are healthy. Because of the patient's marked blisters, he was referred to Sapporo City General Hospital at 6 days old and has been carefully followed up by dermatologists at the hospital for 31 years. He had blistering after mild trauma, progressive poikiloderma and marked atrophy on the dorsal aspect of the hands and feet, with a cigarette paper-like wrinkled appearance (Fig 1a, b). He has undergone repetitive dilatation procedures for anal, urethral and oesophageal stenosis since age 5. He was first diagnosed with KS at age 18, based on characteristic clinical features as well as negative *COL7A1* mutation, as described previously (7). He now shows marked atrophy and progressive poikiloderma of the entire skin, several erosions on the buttocks and legs, and microstomia, all of which are typical KS cutaneous features (Fig. 1c, d). Since the age of 16 years, he has suffered from stomachaches after meals due to severe stenosis and ulcers in the intestines, which have met the criteria for Crohn's disease. Treatment with prednisolone, methotrexate, mesalazine, azathioprine and infliximab had little effect; therefore, he underwent emergent partial ileotomy due to bowel perforation at the ages of 25, 26 and 29 years (Fig. S1a¹). However, several strictures still cause obstruction, predominantly in the ileum, and they easily recur after repeated balloon dilatation. He has undergone balloon dilatation for ileal stenosis more than 10 times in the past 5 years. Recent colonoscopy showed ulcers and several strictures, mainly in the ileum. The mucosa of the colon and the rectum also showed erosions but no strictures. Histopathological examination of ileal specimens showed apparent epithelial detachment of the mucosa and inflammatory cell infiltrates in the lamina propria (Fig. S1b¹).

Two skin biopsy specimens taken at the ages of 18 and 31 years were compared. Indirect immunofluorescence was performed by using monoclonal antibodies against type IV, VII and XVII collagen, $\alpha 6$ and $\beta 4$ integrin, BP230, plectin, uncein and laminin-332. Type VII collagen and type IV collagen showed a broad reticulate labelling pattern in both specimens, whereas other antibodies showed a normal bright linear pattern, which are compatible with KS (Fig. 1e). Electron microscopy revealed reduplication of the basement membrane in both specimens, but there was not a significant difference between them (not shown).



¹<http://www.medicaljournals.se/acta/content/?doi=10.2340/00015555-1696>

Fig. 1. A blister on the hand at birth (a). Atrophy of the hand at 5 years of age (b). Poikilodermatous change and erosion on the dorsum of the hand at 30 years of age (c). Poikilodermatous change on the back at 31 years of age (d). Broad, reticulate labelling pattern is seen with LH7.2 monoclonal antibodies against type VII collagen (e).

Molecular findings. The blood was obtained from the patient after informed consent and approval by the ethics committee of Hokkaido University. The entire coding region and the exon-intron boundaries of the *FERMT1* gene were analysed by PCR and direct sequencing as previously described (8). Mutation analysis revealed the novel mutation c.1564 delC in exon 12 of the *FERMT1* gene in the maternal allele, which is predicted to lead to nonsense-mediated mRNA decay (Fig. S2a'). Since paternal mutation could not be identified, we next assessed mRNA expression using the following primers directing *FERMT1* (5'-TAGTTTGTAGGGAC-GCAGCT-3' and 5'-CGCCTTTGGCTTGCCCTTGTT-3') and Glyceraldehyde-3-phosphate dehydrogenase (*GAPDH*) (5'-TGAAGGTCGGAGTCAACGGATTGGT-3' and 5'-CATGTGGGCCATGAGGTCCACCAC-3') mRNA, respectively. Total mRNA from cultured keratinocytes or fibroblasts was prepared using the RNeasy Mini Kit (Qiagen), followed by RT-PCR using Superscript III (Invitrogen) according to the manufacturer's instructions. Fibroblasts from the patient were used for this study, because the patient's keratinocytes were unavailable. It was found that *FERMT1* mRNA could be detected from the normal human keratinocytes as well as fibroblasts; however, it was undetectable from the patient's fibroblasts (Fig. S2b'). These results suggest that Kindlin1 expression is disrupted by maternal c.1564 delC and unknown paternal null-mutations in the *FERMT1* gene.

DISCUSSION

In KS, significant clinical variability has been reported among patients. Intestinal involvement, including diarrhoea or colitis, was diagnosed in 15% (9 of 58) of KS patients in the Has study (2), but the exact mechanism and relationship to Kindlin1 deficiency remains unclear. Kern reported two KS patients (homozygous for null mutations) who had severe intestinal involvement with haemorrhagic diarrhoea in the first month of life, and histopathology demonstrated focal detachment of the epithelium in the colonic mucosa (5). Kindlin1 knockout mice have shown marked skin atrophy as well as shortened and swollen terminal ileum and colon with strictures in the distal colon (9). The present case with typical cutaneous features of KS did not have any intestinal symptoms until age 16, but later he had stomach aches due to obstruction of the ileum, despite 3 partial ileal resections and repeated balloon dilatations. This case is unique in that he did not have any intestinal symptoms, such as diarrhoea or abdominal discomfort, in childhood. No similar case accompanying severe strictures has been reported before. Epithelial detachment causing disruption of the intestinal barrier might have occurred first (5), followed by penetration of antigens, inflammation and healing that led to stricture formation. There is another reported KS case which underwent partial resection of the small bowel due to inflammatory stenosis caused by "Crohn's disease" at the age of 45 (10). However, the symptom was reported to disappear completely after resection (6). The present case is the first KS case with the severe intestinal involvement of multiple ileal stenoses. In addition, a Pubmed search has revealed this to be the longest follow-up case report of a KS patient at a single institute from birth.

In this study, we identified the novel mutation c.1564 delC in exon 12 of the *FERMT1* gene in the maternal allele, which is predicted to lead to nonsense-mediated mRNA decay. *FERMT1* mRNA was undetectable by RT-PCR, although the paternal mutation cannot be identified. Despite the novel mutation, the cutaneous findings do not differ from the cases with other mutations. The literature review was unable to reveal any relationship between the *FERMT1* locus (20p12.3) and loci of Crohn's disease.

In conclusion, long-term follow-up of KS patient revealed that severe late-onset ileal strictures can also occur as one of the clinical features of KS. It is suggested that *FERMT1* expression is disrupted by maternal c.1564 delC and unknown paternal null-mutations in the *FERMT1* gene in the present case. Further cases should be accumulated to clarify the different cutaneous and intestinal phenotypes of KS and the genotype correlation.

The authors declare no conflict of interest.

REFERENCES

- Lai-Cheong JE, McGrath JA. Kindler syndrome. *Dermatol Clin* 2010; 28: 119–124.
- Has C, Castiglia D, del Rio M, Diez MG, Piccinni E, Kiritsi D, et al. Kindler syndrome: extension of *FERMT1* mutational spectrum and natural history. *Hum Mutat* 2011; 32: 1204–1212.
- Jobard F, Bouadjar B, Caux F, Haddj-Rabia S, Has C, Matsuda F, et al. Identification of mutations in a new gene encoding a FERM family protein with a pleckstrin homology domain in Kindler syndrome. *Hum Mol Genet* 2003; 12: 925–935.
- Siegel DH, Ashton GH, Penagos HG, Lee JV, Feiler HS, Wilhelmsen KC, et al. Loss of kindlin-1, a human homolog of the *Caenorhabditis elegans* actin-extracellular-matrix linker protein UNC-112, causes Kindler syndrome. *Am J Hum Genet* 2003; 73: 174–187.
- Kern JS, Herz C, Haan E, Moore D, Nottelmann S, von Lilien T, et al. Chronic colitis due to an epithelial barrier defect: the role of kindlin-1 isoforms. *J Pathol* 2007; 213: 462–470.
- Sadler E, Klausegger A, Muss W, Deinsberger U, Pohla-Gubo G, Laimer M, et al. Novel *KIND1* gene mutation in Kindler syndrome with severe gastrointestinal tract involvement. *Arch Dermatol* 2006; 142: 1619–1624.
- Yasukawa K, Sato-Matsumura KC, McMillan J, Tsuchiya K, Shimizu H. Exclusion of *COL7A1* mutation in Kindler syndrome. *J Am Acad Dermatol* 2002; 46: 447–450.
- Natsuga K, Nishie W, Shinkuma S, Nakamura H, Matsushima Y, Tatsuta A, et al. Expression of exon-8-skipped kindlin-1 does not compensate for defects of Kindler syndrome. *J Dermatol Sci* 2011; 61: 38–44.
- Ussar S, Moser M, Widmaier M, Rognoni E, Harrer C, Genzel-Boroviczeny O, et al. Loss of Kindlin-1 causes skin atrophy and lethal neonatal intestinal epithelial dysfunction. *PLoS Genet* 2008; 4: e1000289.
- Lanschuetzer CM, Muss WH, Emberger M, Pohla-Gubo G, Klausegger A, Bauer JW, et al. Characteristic immunohistochemical and ultrastructural findings indicate that Kindler's syndrome is an apoptotic skin disorder. *J Cutan Pathol* 2003; 30: 553–560.