

## SHORT COMMUNICATION

## Behçet's Disease-like Symptoms Associated with Myelodysplastic Syndrome with Trisomy 8: A Case Report and Review of the Literature

Hanako Koguchi-Yoshioka<sup>1</sup>, Daisuke Inokuma<sup>1</sup>, Masatoshi Kanda<sup>2</sup>, Makoto Kondo<sup>2</sup>, Kazuhiro Kikuchi<sup>1</sup> and Satoko Shimizu<sup>1</sup>Departments of <sup>1</sup>Dermatology and <sup>2</sup>Rheumatology and Clinical Immunology, Sapporo City General Hospital, North 11, West 13, Chuo-ku, Sapporo 060-8604, Japan. E-mail: stain\_way@yahoo.co.jp

Accepted May 31, 2013; Epub ahead of print Sep 16, 2013

Dermatologists usually know little about the Behçet's disease (BD)-like symptoms that are associated with myelodysplastic syndrome (MDS) involving trisomy 8. Acquired trisomy 8 is frequently observed in patients with MDS. We report a case of MDS with trisomy 8, who developed high fever, oral aphthae, and genital and intestinal ulceration. We also reviewed the literature for similar cases with skin involvement.

## CASE REPORT

A 63-year-old man was admitted to our hospital with a 1-month history of high fever, oral aphthae and diarrhoea. He was not born with congenital abnormalities and did not have previous history. He was treated with antibiotics, but the symptoms recurred. Three weeks later, he developed painful scrotal ulcers of up to 12-mm in diameter (Fig. 1a). Neither erythema nodosum nor acneform nodules, nor any other eruptions were seen anywhere else on the body. Pathergy test was negative. Skin biopsies from a scrotal ulcer showed necrotic epidermis, perivascular infiltration of neutrophils and mononuclear cells, and extravasation of erythrocytes. Laboratory tests showed macrocytic anaemia (haemoglobin 7.7 g/dl (normal: 13.8–17.0 g/dL), mean corpuscular volume 114.8 fl (normal: 84.0–98.0 fL)) and marked inflammatory reaction (C-reactive protein 17.9 mg/dl (normal: 0.0–0.2 mg/dL)). Biochemical blood tests revealed only mild elevation of liver enzymes (AST 44 U/l (normal: <40 U/L), ALT 56 U/l (normal: <40 U/L), LDH 525 U/l (normal: 103–229 U/L),  $\gamma$ -GTP 192 U/l (normal: 12–69 U/L)). He was HLA-B51 negative. No eye lesions were evident. Ulcers on the tongue (Fig. 1b), buccal mucosa, palate and epiglottis were clearly revealed by nasopharyngolaryngoscopy. Endoscopic examination of the gastrointestinal tract revealed aphthous lesions over the entire colon

(Fig. 1c). Macrocytic anaemia led us to perform a bone marrow examination, which revealed dysplasia, including hypersegmented neutrophils and micromegakaryocytes. Chromosomal analysis of bone marrow cells revealed the 47, XY, +8 karyotype in 16 of 20 dividing cells. Based on similar previous cases, we made the diagnosis of BD-like symptoms associated with MDS, involving trisomy 8. Prednisolone therapy, administered at an initial dosage of 1 mg/kg/day (60 mg) with a gradual tapering, led to complete disappearance of the oral, genital and intestinal ulcers.

## DISCUSSION

Recently, an increasing number of cases of MDS with trisomy 8 were reported to develop symptoms such as fever, oral and genital ulcers, and skin lesions (1, 2), which are characteristic in patients with BD. These patients often had intestinal lesions (1, 2). To date, no clear etiological relationship between MDS, trisomy 8, and BD-like symptoms has been documented; however, there are some clues to such a relationship. Chen et al. (3) analysed the gene expression pattern in purified CD34<sup>+</sup> haematopoietic progenitor cells obtained from MDS patients with trisomy 8. They found that up-regulated genes in these patients included those primarily involved in immune and inflammatory responses, such as TGF- $\beta$ , TGF- $\beta$  receptor, IL-6, IL-7 receptor, VCAM-1 and ICAM-1. Ohno et al. (4) demonstrated increased reactive oxygen production by activated neutrophils due to serum factors such as IL-6 and G-CSF in a patient with MDS with trisomy 8. They predicted that this played an important role in the com-

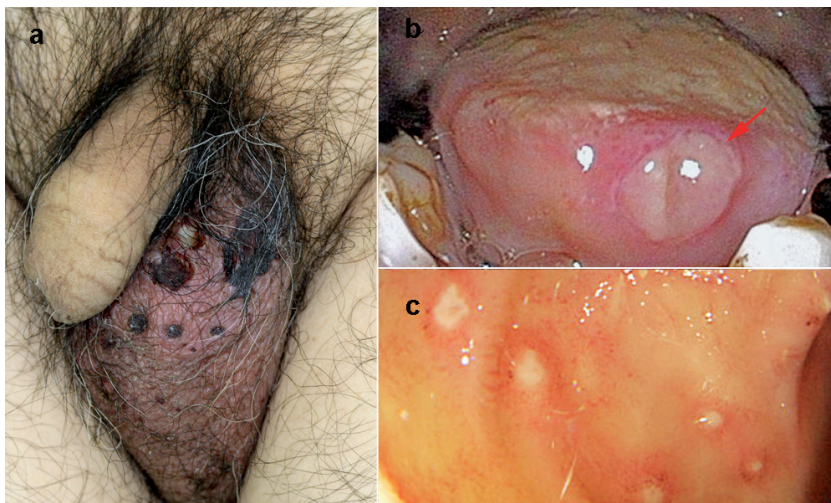


Fig. 1. Painful ulcers with blood crusts are seen on the scrotum (a). Nasopharyngolaryngoscopy clearly reveals an ulcer on the tongue (red arrow) (b). Colonoscopy shows aphthoid lesions over the entire colon (c).

Table 1. Results of 31 reported cases of Behçet's disease-like symptoms associated with myelodysplastic syndrome involving trisomy 8

	n (%)
Sex	
Male	12 (39)
Female	19 (61)
Symptoms <sup>a</sup>	
Recurrent oral aphthae	27 (87)
Recurrent genital aphthae	23 (74)
Eye lesions	3 (10)
Skin lesions	17 (55)
Erythema nodosum	11 (35)
Papulopustular lesions or acneform nodules	6 (19)
Positive pathergy test	8/15 (53)
Other symptoms	
High fever	17 (55)
Gastrointestinal ulcerations	22 (71)
Arthritis	2 (7)
Vascular disease	3 (10)
HLA-B51, positive	2/13 (15)

<sup>a</sup>Meeting the International Study Group criteria of BD.

plications associated with BD. This knowledge does not seem to be well-known to dermatologists; therefore, we searched Pubmed for similar cases and found 31 reported cases (1, 2, 4–15) (Table 1). When the BD diagnostic criteria derived from the International Study Group (16) were applied to these 31 cases, recurrent oral aphthae and recurrent genital aphthae were found in more than 70% of the cases; however, ocular lesions were only rarely detected. About half of the cases exhibited skin lesions, the majority of which manifested as erythema nodosum or papulopustular lesions. Pathergy test was positive in 8 of 15 cases. Twenty-three of the 31 patients met the criteria of BD, which required the presence of recurrent oral aphthae plus at least 2 of the following: recurrent genital aphthae, eye lesions, skin lesions and positive pathergy test (16). Other clinical manifestations frequently seen in these patients were high fever and gastrointestinal ulcers. Thirteen of the previously examined patients had been examined for HLA, and only 2 of these patients had shown HLA-B51, although HLA-B51 carriers have higher risk of developing BD compared with non-carriers (17). Our patient could be said to have characteristics typical of these patients. All these cases were reported by general physicians; therefore, dermatologists seem to be unfamiliar with BD-like symptoms associated with MDS involving trisomy 8. It is important for dermatologists to recognise this and, when we examine patients with BD-like mucocutaneous lesions, such as oral or genital aphthae, erythema nodosum or folliculitis, we should consider taking a blood sample to screen for any underlying haematological disorders.

The authors declare no conflict of interest.

## REFERENCES

1. Fujimura T, Yukawa N, Nakashima R, Imura Y, Kawabata D, Nojima T, et al. Periodic fever and erythema nodosum

- associated with MDS with trisomy 8: report of two cases and review of the literature. *Mod Rheumatol* 2010; 20: 413–419.
2. Kawabata H, Sawaki T, Kawanami T, Shimoyama K, Karasawa H, Fukushima T, et al. Myelodysplastic syndrome complicated with inflammatory intestinal ulcers: significance of trisomy 8. *Intern Med* 2006; 45: 1309–1314.
3. Chen G, Zeng W, Miyazato A, Billings E, Maciejewski JP, Kajigaya S, et al. Distinctive gene expression profiles of CD34 cells from patients with myelodysplastic syndrome characterized by specific chromosomal abnormalities. *Blood* 2004; 104: 4210–4218.
4. Ohno E, Ohtsuka E, Watanabe K, Kohno T, Takeoka K, Saburi Y, et al. Behçet's disease associated with myelodysplastic syndromes. A case report and a review of the literature. *Cancer* 1997; 79: 262–268.
5. Chen HC, Chiu YM. Large-vessel thrombosis in intestinal Behçet's disease complicated with myelodysplastic syndrome and trisomy 8. *World J Gastroenterol* 2012; 18: 1137–1140.
6. Shigemura T, Agematsu K, Yamazaki T, Sakashita K, Nakayama Y, Higuchi Y, et al. A case of Behçet's disease associated with myelodysplastic syndrome involving trisomy 8 and a gain-of-function mutation in SHP-2. *Rheumatology (Oxford)* 2011; 50: 1342–1344.
7. Mantzourani MG, Chantziara K, Thanopoulou I, Variami H, Vaiopoulos G, Pangalis GA. Coexistence of Behçet's disease and chronic myelomonocyte leukemia with trisomy 8: a case report and review of the literature. *Clin Exp Rheumatol* 2009; 27: S85–87.
8. Ahn JK, Cha HS, Koh EM, Kim SH, Kim YG, Lee CK, Yoo B. Behçet's disease associated with bone marrow failure in Korean patients: clinical characteristics and the association of intestinal ulceration and trisomy 8. *Rheumatology (Oxford)* 2008; 47: 1228–1230.
9. Lin YC, Liang TH, Chang HN, Lin JS, Lin HY. Behçet disease associated with myelodysplastic syndrome. *J Clin Rheumatol* 2008; 14: 169–174.
10. Thachil JV, Salim R, Field A, Moots R, Bolton-Maggs P. Myelodysplastic syndrome with trisomy 8 associated with Behçet syndrome: an immunologic link to a karyotypic abnormality. *Pediatr Blood Cancer* 2008; 50: 649–651.
11. Kuttikat A, Haskard D, Chakravarty K. Behçet's disease associated with trisomy 8 in a male Caucasian patient from Great Britain – a case report. *Clin Exp Rheumatol* 2005; 23: S108–109.
12. Eder L, Rozenbaum M, Boulman N, Aayubkhanov E, Wolfowitz E, Zisman D, Rosner I. Behçet's disease, myelodysplastic syndrome, trisomy 8, gastroenterological involvement – an association. *Clin Exp Rheumatol* 2005; 23: S91–95.
13. Ando S, Maemori M, Sakai H, Ando S, Shiraishi H, Sakai K, Ruhnke GW. Constitutional trisomy 8 mosaicism with myelodysplastic syndrome complicated by intestinal Behçet disease and antithrombin III deficiency. *Cancer Genet Cytogenet* 2005; 162: 172–175.
14. Kimura S, Kuroda J, Akaogi T, Hayashi H, Kobayashi Y, Kondo M. Trisomy 8 involved in myelodysplastic syndromes as a risk factor for intestinal ulcers and thrombosis – Behçet's syndrome. *Leuk Lymphoma* 2001; 42: 115–121.
15. Ogawa H, Kuroda T, Inada M, Yamamoto M, Enomoto H, Kishima Y, et al. Intestinal Behçet's disease associated with myelodysplastic syndrome with chromosomal trisomy 8 – a report of two cases and a review of the literature. *Hepato-gastroenterology* 2001; 48: 416–420.
16. International Study Group for Behçet's Disease. Criteria for diagnosis of Behçet's disease. *Lancet* 1990; 335: 1078–1080.
17. de Menthon M, Lavalley MP, Maldini C, Guillevin L, Mahr A. HLA-B51/B5 and the risk of Behçet's disease: a systematic review and meta-analysis of case-control genetic association studies. *Arthritis Rheum* 2009; 61: 1287–1296.