

SHORT COMMUNICATION

Acral Acquired Cutis Laxa Associated with IgA Multiple Myeloma, Joint Hyperlaxity and Urticarial Neutrophilic Dermatitis

Nicolas Kluger^{1,2}, Jean-Pierre Molès³, Olivier M. Vanakker⁴, Charlotte Pernet^{1,5}, Marie Beylot-Barry⁶ and Didier Bessis^{1,3*}¹University of Montpellier I and Department of Dermatology, Saint-Eloi Hospital, CHU Montpellier; 80, avenue Augustin Fliche, FR-34295 Montpellier, France, ²Department of Dermatology, Allergology and Venereology, Institute of Clinical Medicine, Skin and Allergies Hospital, Helsinki University Central Hospital, Helsinki, Finland, ³INSERM 1058, Montpellier, France, ⁴Center for Medical Genetics, Ghent University Hospital, Ghent, Belgium, ⁵Department of Pathology, Gui de Chauliac Hospital, CHU Montpellier, Montpellier, and ⁶Department of Dermatology, Haut-Lévêque Hospital, CHU Bordeaux, Pessac, France. E-mail: d-bessis@chu-montpellier.fr

Accepted Mar 11, 2014; Epub ahead of print Mar 25, 2014

Acral localised acquired cutis laxa (ALACL) is a very rare form of acquired cutis laxa characterised by loose redundant skin folds confined to the hands and feet, giving the appearance of premature aging, and histological loss of dermal elastic tissue (1–9). We report here a new case of ALACL associated with IgA multiple myeloma and also, for the first time, with joint hyperlaxity and recurrent neutrophilic urticarial dermatosis.

CASE REPORT (for detailed methods see Appendix S1¹)

A 40-year-old man presented in 2007 for the management of ALACL and monoclonal IgA gammopathy. He had chronic urticarial dermatosis of the extremities, mostly involving the hands, which had manifested in 1996 and progressively worsened, with repeated swelling of the fingers. ALACL was diagnosed at that time in association with an unusual hyperlaxity of the distal interphalangeal joints. Over the past several years, he has received multiple treatments including methotrexate, colchicine, hydroxychloroquine, intravenous gammaglobulins and dapsone. All have either been ineffective or had debilitating side effects. Oral prednisone resulted in complete remission of the urticarial lesions, with steroid dependence estimated at 20–30 mg/day, but this did not prevent the progression in joint laxity or cutis laxa. Physical examination disclosed the loose, redundant skin of all fingers (Fig. 1A). On demand, he was able to completely dislocate multiple interphalangeal joints painlessly and effortlessly (Fig. 1B). Laboratory tests showed a monoclonal IgA lambda peak with hypogammaglobulinemia (4.9 g/l; normal 7.1–15.6 g/l) with decreased IgG (3.92 g/l; normal 6.9–14 g/l) and normal serum levels of IgM and IgA. Urinary immunoelectrophoresis showed increased lambda light chains. Hand X-rays revealed articular dislocations of most of the proximal and distal interphalangeal joints. Bone marrow aspiration revealed 13% plasma cells with dystrophy, consistent

with IgA myeloma. A biopsy specimen taken from an urticarial papule of the palmar hand revealed a dense dermal interstitial and perivascular neutrophilic infiltrate and leukocytoclasia without oedema or vasculitis (Fig. 2), consistent with neutrophilic urticarial dermatosis. Amyloid Congo red staining was negative in all biopsy specimens. Between 2007 and 2012, the following treatments were all ineffective: plasmapheresis (6 sessions), anakinra (3 months), infliximab (4 months), rituximab (4 sessions) and alkeran (2 sessions). Unfortunately, the patient chose not to follow-up.

Direct immunofluorescence investigation of lesional skin revealed abundant IgA deposits that decorated the dermoepidermal junction (DEJ) and the capillary network of the dermal papillae (Fig. 3A). A control specimen from non-lesional forearm skin showed only faint staining in the DEJ (data not shown). Electron microscopy showed conspicuous diminution of the elastic fibres with normal-appearing collagen fibres; macrophages were observed phagocytosing the elastic fibres. Direct immunoelectron microscopy further localised the IgA deposits at the anchoring fibres located underneath the DEJ (Fig. 3B). Additional gold-staining was observed in the papillary dermis but no association with a defined structure was determined (data not shown).

Molecular analysis of the *FBLN5* gene and exon 4 and the last 7 exons of the *ELN* gene revealed no mutations. In addition, the western blot of extracellular matrix proteins (ECM) secreted by isolated lesional ALACL fibroblast was probed with anti-fibulin-5 antibody. The detected proteins had the same apparent molecular weight as in the ECM extracts produced by control fibroblasts. Last, the same ECM blots were probed with the patient's antibodies (concentrated sera obtained after plasmapheresis) and no specific reaction against ALACL ECM extracts was revealed (data not shown).

DISCUSSION

The acral localisation of cutis laxa is very rare. To the best of our knowledge, only 12 cases (including the present case) have been described (see Table S1¹). Our patient developed striking spontaneous joint hyperlaxity after

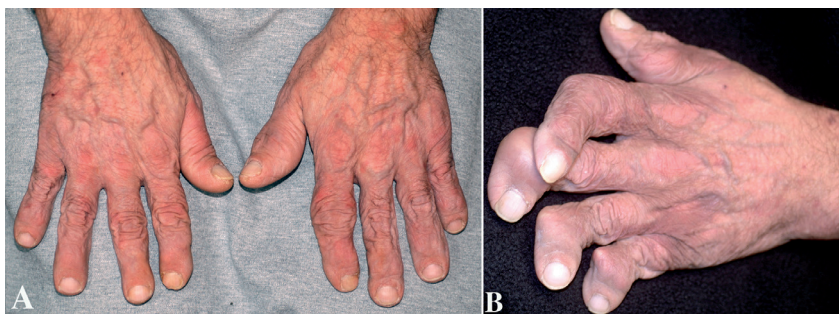
¹<http://www.medicaljournals.se/acta/content/?doi=10.2340/00015555-1846>

Fig. 1. Acral cutis laxa. (A) Cutis laxa is predominant on the fingers and associated with misalignment of the proximal interphalangeal articulation of the left index. (B) Complete dislocation of multiple interphalangeal joints could be obtained painlessly and effortlessly.

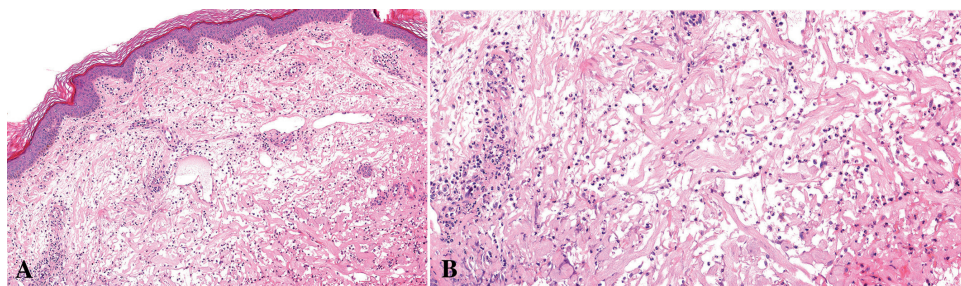


Fig. 2. (A) Dermal interstitial and perivascular neutrophilic infiltrate without vasculitis (haematoxylin-eosin, original magnification $\times 10$); (B) At highest magnification, dense interstitial neutrophilic infiltrate is noted with significant leukocytoclasia and altered collagen bundles, but no oedema.

several years of disease progression in the absence of any underlying rheumatologic disease. This feature has not been reported thus far in any of the prior cases of ALACL.

A history of local swelling and chronic urticaria at the location of the cutis laxa was reported in 3 cases of ALACL (1, 5) with variable delay, the maximum thus far being 14 years (1). Only one biopsy specimen from an urticarial lesion associated with ALACL has been documented and it showed the same pattern of neutrophilic urticarial dermatosis (NUD) (11) as observed in our case. NUD is considered as one of the clinical and histological expressions of skin autoinflammation and a sign of auto-inflammatory syndromes or suspected disorders of the innate immunity, including adult-onset Still's disease and Schnitzler syndrome. Schnitzler syndrome is classically characterised by a constant recurrent urticarial rash and monoclonal IgM gammopathy, and deposition of IgM in the epidermis, the dermoepidermal junction and the papillary dermal vessels is a suspected trigger for the urticarial lesions (12). In our observation, the results of direct immunofluorescence and immunoelectron microscopy of the IgA deposits in skin sections along the basement membrane zone or around the superficial dermal vessels were strikingly similar, suggesting a common pathogenic mechanism of inflammatory dermal lesions induced by monoclonal Ig in these 2 diseases.

ACKNOWLEDGEMENT

The authors are grateful to Chantal Cazevieille and Cécile Sanchez for their technical assistance and data interpretation concerning the ultrastructural microscopy (Centre de Ressources en Imagerie Cellulaire de Montpellier, France) and to Anne Tesniere for protein analysis.

REFERENCES

1. Fisher BK, Page E, Hanna W. Acral localized acquired cutis laxa. *J Am Acad Dermatol* 1989; 21: 33–40.
2. Yoneda K, Kanoh T, Nomura S, Ozaki M, Imamura S. Elastolytic cutaneous lesions in myeloma-associated amyloidosis. *Arch Dermatol* 1990; 126: 657–660.
3. Klein-Lerousseau F, Lacour JP, Perrin C, Bozetto G, Ortonne JP. “Vanishing” finger pads syndrome: localized acquired cutis laxa? *Ann Dermatol Venereol* 1992; 119: 939–941.
4. Martín L, Requena L, Yus ES, Furio V, Fariña MC. Acrolocalized acquired cutis laxa. *Br J Dermatol* 1996; 134: 973–976.
5. Rongioletti F, Cutolo M, Bondavalli P, Rebora A. Acral localized acquired cutis laxa associated with rheumatoid arthritis. *J Am Acad Dermatol* 2002; 46: 128–130.
6. Appiah YE, Onumah N, Wu H, Elenitsas R, James W. Multiple myeloma-associated amyloidosis and acral localized acquired cutis laxa. *J Am Acad Dermatol* 2008; 58: S32–33.
7. Ferrándiz-Pulido C, Serra M, Bel S, Ferrer B, Repiso T, Garcia-Patos V. Multiple myeloma-associated amyloidosis presenting with acrolocalized acquired cutis laxa. *Arch Dermatol* 2010; 146: 1433–1434.
8. Dicker TJ, Morton J, Williamson RM, Chick J. Myeloma-associated systemic amyloidosis presenting with acquired digital cutis laxa-like changes. *Australas J Dermatol* 2002; 43: 144–146.
9. Marti N, Monteagudo C, Revert A, Reig I, Gamez L, Jorda E. Acral localized acquired cutis laxa. *Int J Dermatol* 2013; 52: 983–986.
10. Jover B, Girardot D, de Courtois Roy de Vacquières F, Casellas D, Molès JP. Wnt-4 potently inhibits capillary outgrowth from rat aorta in 3D culture. *Fundam Clin Pharmacol* 2013; 27: 465–470.
11. Kieffer C, Cribier B, Lipsker D. Neutrophilic urticarial dermatosis: a variant of neutrophilic urticaria strongly associated with systemic disease. Report of 9 new cases and review of the literature. *Medicine (Baltimore)* 2009; 88: 23–31.
12. Lipsker D, Spehner D, Drillien R, Schmitt P, Cribier B, Heid E, et al. Schnitzler syndrome: heterogeneous immunopathological findings involving IgM-skin interactions. *Br J Dermatol* 2000; 142: 95–99.

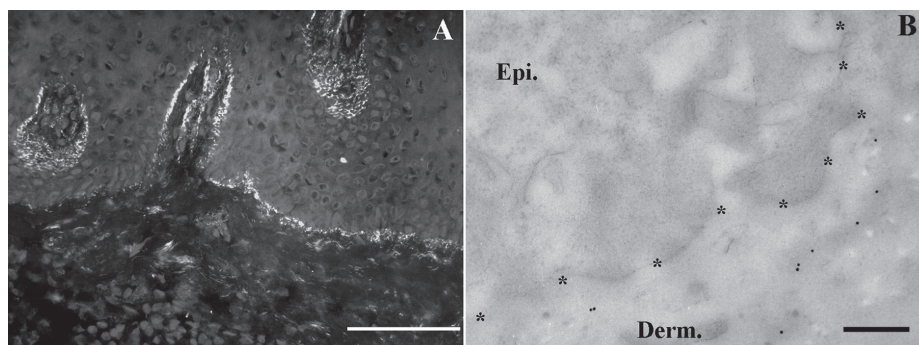


Fig 3. Direct immunofluorescence (A) and immunoelectron microscopy of IgA deposits (B) in skin sections. (A) The main IgA deposits were observed at the dermo-epidermal junction of the lesional skin sections. The papillary dermis was also positive, as was the papillary microcirculation (bar = 50 μm); (B) gold particles were observed underneath the dermo-epidermal junction in lesional skin section decorating anchoring fibres. The basement membrane zone was delineated by a series of * (Epi. = epidermis; Derm. = dermis; bar = 400 nm).