

Immunocompetent Cells of Fixed Drug Eruption

K. VISA, K. KÄYHKÖ, S. STUBB and S. REITAMO

Department of Dermatology and Fourth Department of Medicine, Helsinki University Central Hospital, Helsinki, Finland

Visa K, Käyhkö K, Stubb S, Reitamo S. Immunocompetent cells of fixed drug eruption. *Acta Derm Venereol (Stockh) 1987; 67: 30-35.*

The positive provocation test reactions of the skin of six patients with fixed drug eruption (FDE) were studied from timed skin biopsies taken between 2 hours and 9 days after the appearance of FDE. Monoclonal antibodies to the following immunocompetent cell surface epitopes were used: T3, T4, T6, T8, T9, M1, Ia1, Drc, Leu7 and B cell. The dermal infiltrate comprised 60-80% of T lymphocytes at all the times studied. Cells with T4 and T8 epitopes were displayed in similar numbers. A transient decrease in the number of T6+ cells of the epidermis could be detected with a simultaneous and also transient increase of the T6+ cells in the dermis, which suggests a possible traffic of Langerhans' cells from the epidermis to the dermis. The epidermal Ia1+ cells showed changes similar to but less marked than the T6+ cells. The number of the dermal Ia1+ cells increased continuously. In the late biopsies these Ia1+ cells comprised up to 90% of the infiltrating cells. Except for the finding of a reduction of T6+ and Ia1+ epidermal cells, the cellular kinetics of FDE are similar to those seen in both cutaneous immunological and irritant reactions. *Key word: Immunocompetent cells of the skin.* (Received June 6, 1986.)

S. Reitamo, Department of Dermatology, Helsinki University Central Hospital, Snellmaninkatu 14, 00170 Helsinki, Finland.

Fixed drug eruption (FDE) is a cutaneous reaction characterized by recurrent lesions which usually appear as one or more solitary pruritic erythematous macules that evolve into edematous plaques, vesicles and bullae, which may develop at a later stage, (1, 2). The histology of FDE shows hydropic degeneration of epidermal basal cells resulting in pigmentary incontinence. Melanin is present in the upper dermis, partly within macrophages. The inflammatory cells appear as dermal perivascular infiltrates consisting mainly of mononuclear cells. The classification of FDE has been difficult, although it seems that the cell-mediated immunity plays a major role in its pathogenesis (2).

In the present paper we study the *in situ* distribution of immunocompetent cells and their kinetics in FDE. For this purpose we have studied timed biopsies from positive provocation test reactions.

PATIENTS AND METHODS

Patients

Six patients with FDE (mean age 41.8 years; range 25-61 years) were studied. Five were males and one was female. A peroral provocation with the suspected drug was performed in each case. The drugs were sulphonamides (two cases), phenazone or phenazone salicylate (three cases) and carbamazepine (one case). The onset of FDE varied from 15 min to 12 h after the provocation (Table I).

Biopsies

Serial surgical biopsies (3-5/patient) were taken from the same lesion (Table II). The biopsies were divided into two parts: one was immediately frozen in liquid isopentane at -50° for immunoperoxidase studies as described by Scheynius et al. (3); the other was fixed in Bouin's fluid for enumeration of the mast cells from paraffin sections.

Immunostaining

The following primary antibodies were used: OKT3, OKT4, OKT6, OKT8, OKT9, OKM1, OKIa1 (all from Ortho Diagnostic Systems Inc., Raritan, NJ, USA), Leu 7 (Becton-Dickinson, CA, USA), anti dendritic reticular cell (Drc) and anti B cell (Dakopatts A/S, Copenhagen, Denmark). The immunoperoxidase staining was performed using the avidin-biotin-complex (ABC) method (Vectastain ABC kit mouse IgG PK-4002, Vector Laboratories Inc., Burlingame, CA, USA) as described by Hsu (4). The sections were incubated in darkness with 0.5% 3,3'-diaminobenzidine tetrahydrochloride (DAB, Sigma Chemical Co., MO, USA) and 0.01% H₂O₂ in phosphate-buffered saline (PBS), counterstained with haematoxylin, dehydrated in a graded alcohol series, cleared in xylene and mounted in Histoclad (Clay Adams, NJ, USA). The following controls were performed: the first antibody was replaced by PBS or a non-relevant monoclonal antibody, and tissue sections were stained for endogenous peroxidase activity without antibody treatment.

Mast cells

Mast cells were stained from paraffin sections with toluidine blue and Giemsa's stain.

Counting of the cells

The inflammatory cell subclasses were counted from tissue sections at 400-fold magnification. At least 200 inflammatory cells were counted separately by two investigators in each test reaction. The dendritic cells of the epidermis (the number/mm²) were counted with the aid of a calibrated grid for three different areas of each tissue section. A dendritic cell was only regarded as being Ia1+ or T6+ when the nucleus was clearly associated with dendrites.

RESULTS

All but the Drc marker positive cells could be identified in the epidermis or the dermis (Table III); however, cells displaying Leu7 and B cell markers were rare.

Table I. *Provocation for fixed drug eruption (FDE)*

Patient	Age (yrs)	Sex	Drug used	Dose (mg)	Onset of FDE
1. L. V.	56	F	Sulfadiazine	150	20 min
2. R. J.	33	M	Phenazone salicylate	50	4 h
3. K. S.	61	M	Phenazone	100	1 h
4. A. K.	43	M	Carbamazepine	25	12 h
5. M. L.	33	M	Sulfamethoxydiazine	40	15 min
6. E. P.	25	M	Phenazone salicylate	30	12 h

Table II. *Biopsy scheme for FDE*

Patient	Biopsy site	Time point of biopsy after eruption (h)									
		2	6	12	24	40	48	72	84	6 days	9 days
1. L. V.	Side of hand	×	×		×			×			
2. R. J.	Pelvic area	×	×		×						
3. K. S.	Back	×	×		×			×			×
4. A. K.	Gluteal area			×		×		×			
5. M. L.	Wrist	×			×		×			×	
6. E. P.	Side of hand	×				×			×		

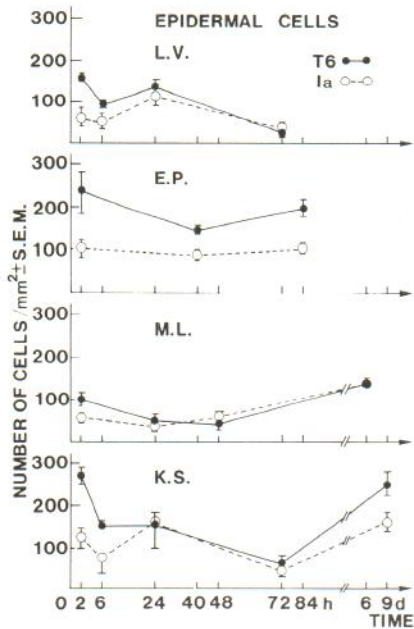


Fig. 1. Kinetics of epidermal dendritic cells displaying T6 and Ia1 in FDE.

T6- and Ia1-positive cells

Fig. 1 shows the number of epidermal T6+ and Ia1+ cells in the four patients in whom significant changes of cells displaying these markers were seen in consecutive biopsies. In the second biopsy the number of T6+ cells was always less than in the first (2 h) biopsy. In the biopsies performed at 84 h or later there was again an increase in the number of T6+ cells to the level seen at 2 h. The changes in Ia1+ cells were similar (Fig. 2). In the 2 h biopsies the T6+ cells always outnumbered the Ia1+ cells. In the remaining two patients (biopsies taken at 2, 6 and 24 h and at 12, 40 and 72 h) there were no significant changes in the number of T6+ or Ia1+ cells. No Ia1 positive keratinocytes were seen in the late or any other biopsies studied.

The number of dermal T6+ cells was 10% or less of the total inflammatory cells in all the 2 h biopsies. In two patients (patients 1 and 5), however, the number of T6+ cells remained under 10% in all the biopsies studied. In the subsequent biopsies of the remaining four patients there was an increase in the number of T6+ cells at 40–72 h. The T6+ cells then made up 20–50% of the dermal infiltrate. This increase was followed by a decrease in the number of T6+ cells. In the 6 day biopsies less than 5% of inflammatory cells were T6 positive. Both round and dendritic T6+ cells could be seen. The numbers of Ia1+ cells in the dermal infiltrate was 10–30% in three out of five biopsies performed at 2

Table III. Immunocompetent cells of the skin in FDE

Site	Positive for marker									
	T3	T4	T6	T8	T9	M1	Ia1	Drc	Leu7	B cell
Epidermis	-	-	+	+	-	+	+	-	-	-
Dermis	+	+	+	+	+	+	+	-	+	+

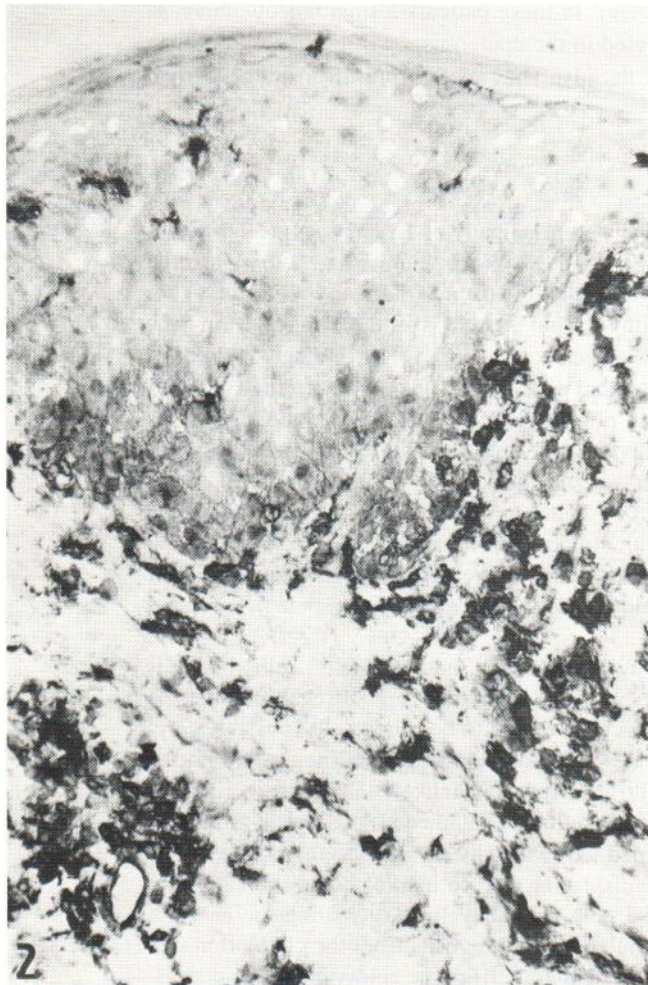


Fig. 2. Skin biopsy in FDE taken at 72 h after onset of eruption (patient 3: K. S.). Immunoperoxidase staining with OKIa1 shows that the epidermal cells are mainly Ia1 negative whereas the majority of dermal inflammatory cells are Ia1 positive ($\times 310$).

h. In patients 2 and 3 the numbers of Ia1+ cells were 70% and 80%, respectively. In all patients there were more Ia1+ cells in the following biopsy. At 36 h–6 d the Ia1+ cells made up 50–90% of the dermal inflammatory cells (Fig. 2) except in patient 5, in whom the number of Ia1+ cells was 30%; the corresponding number in this patient's 2 h biopsy was 20%.

Other cells

No T4+ cells were seen in the epidermis. In the dermal infiltrate the number of T4+ cells was 30–40% at all times studied. Compared to other antibodies used staining with OKT4 resulted in less intense specific staining. Occasional T8+ cells could be seen in the epidermis at various times. The number of T8+ cells in the dermal infiltrate was constantly 30–40%. No T9+ (transferrin receptor+) cells could be found in the epidermis and the number of them in the dermis was always under 5%.

M1+ cells were only occasionally seen both in the epidermis and dermis. However, in the dermis of two patients (patient no 1 at 6 h and no 4 at 36 h) the M1+ cells showed a

transient increase (5% and 20%, respectively). In these patients a simultaneous increase in the number of M1+ cells could be detected in the epidermis.

The mast cells were found only in the dermis. They made up 5–10% of the dermal infiltrate.

DISCUSSION

The inflammatory cell infiltrate of FDE consisted principally of T lymphocytes (60–80%). The T4/T8 ratio was close to one. As the T4 staining was less intense as compared to the T8 staining this ratio could be artificially low despite the use of OKT4 antibodies in higher concentration than OKT8 antibodies. Although no double staining studies were performed, it can be concluded that most of the T cells were Ia1+. The finding of HLA-DR positivity suggests that the T cells were activated cells. This is in contrast to the HLA-DR negativity of the majority of T cells of the peripheral blood. The low numbers of cells displaying a marker for proliferating T cells, i.e. T9, indicates that the T cells originate mainly from outside the skin rather than as a result of local proliferation.

The observation that only T8+ but not T4+ cells can be identified in the epidermis in FDE has been made earlier (5). However, our studies show that the same phenomenon can be seen in other skin conditions, e.g. test reactions of the delayed or irritant type after epicutaneous testing (6). A similar distribution of T8+ cells can also be seen in normal skin (7).

T6+ cells of the dermis have been shown to be mainly "indeterminate" cells, i.e. cells resembling Langerhans' cells but lacking some characteristics, e.g. Birbeck granules as described by Murphy (8). A number of T6+ cells seemed to be round cells (possibly early T cells), especially in dense cellular infiltrates; however, possible dendrites would not be possible to distinguish from such dense infiltrates. It seems unlikely that the high numbers of T6 positive cells in the early FDE reactions could be explained as a technical artifact as staining with OKT6 was usually accompanied with virtually no background staining. The increase in the number of epidermal cells displaying the T6 marker could indicate that: 1) the T6 marker is displayed when these cells are actively participating in the FDE inflammatory reaction; 2) there is an accumulation of these cells from the circulation into the site of the inflammation; 3) these cells could migrate from the epidermis to the dermis. We observed an increase in the number of T6+ cells in the dermis and a simultaneous decrease in the number of T6+ cells in the epidermis. There is recent evidence for such transepidermal migration of T6+ Langerhans' cells (9). The transient increase of the dermal T6+ cells is similar to our earlier observation of an early increase in the number of dermal T6+ cells in a delayed type hypersensitivity reaction after both intracutaneous and epicutaneous application of tuberculin (PPD) (10). However, in that study the epidermal T6+ cells were not counted. Recently, several studies on the immunocompetent cells of one form of delayed hypersensitivity reaction, i.e. the allergic patch test reaction, have shown that there is already an increase in the number of T6+ epidermal Langerhans' cells on the first days of the test reaction (11, 12, 13). This is in contrast to the present finding of a transitional decrease of T6+ or Ia1+ epidermal cells in FDE. A decrease in the number of epidermal Langerhans' cells in immunologically challenged skin has been described by Silberberg-Sinakina et al. (14). Low numbers of epidermal Langerhans' cells have usually been associated with immunosuppression, e.g. topical treatment with corticosteroids (15). Our unpublished studies show a similar transitional decrease of T6+ and Ia1+ cells of the epidermis in the time course test reactions of ultraviolet radiation on human skin.

That FDE may be a form of a T lymphocyte mediated delayed type hypersensitivity reaction (2) could be suggested by the cellular kinetics of the lesion and the predominance

of T lymphocytes in the cellular infiltrate displaying markers of activated cells, e.g. HLA-DR. However, in two patients we already saw the FDE 15 to 20 min after the oral application of the test drug. Such a rapid appearance of the lesion is usually associated with anaphylactic type immunological reactions.

ACKNOWLEDGEMENTS

This study was supported by grants from the Sigrid Jusélius Foundation and Finska Läkaresällskapet. The expert technical help of Dr Kari Kähönen and Ms Leena Juusela is gratefully acknowledged.

REFERENCES

1. Stubb S. Blood leukocytes, with special reference to basophils and eosinophils during provocation tests in fixed drug eruption and drug exanthema. *Acta Derm Venereol (Stockh)* 1976; Suppl 56: 1-47.
2. Korkij W, Soltani W. Fixed drug eruption. A brief review. *Arch Dermatol* 1984; 120: 520-524.
3. Schenynius A, Fisher T, Forsum U, Klareskog L. Phenotypic characterization in situ of inflammatory cells in allergic and irritant contact dermatitis in man. *Clin Exp Immunol* 1984; 55: 81-90.
4. Hsu S, Raine L, Fanger H. The use of avidin-biotin-peroxidase complex (ABC) in immunoperoxidase technique: A comparison between ABC and unlabeled antibody (PAP) procedures. *J Histochem Cytochem* 1981; 29: 577-580.
5. Niemi K-M, Ranki A, Mynttinen S, Stubb S, Plosila M. Erythema fixum: a histological and immunoperoxidase study using monoclonal antibodies. In: MacDonald D, ed. *Immunodermatology*. London: Butterworth & Co Ltd, 1984; 155.
6. Reitamo S, Visa K, Kähönen K, Käyhkö K, Stubb S, Salo O P. Eczematous reactions in atopic patients caused by epicutaneous testing with inhalant allergens. *Br J Dermatol* 1986; 114: 303-309.
7. Smolle J, Ehall R, Kerl H. Inflammatory cell types in normal human epidermis. An immunohistochemical and morphometric study. *Acta Derm Venereol (Stockh)* 1985; 65: 479-483.
8. Murphy G, Bhan A, Harris T, Mihm M. In situ identification of T6-positive cells in normal human dermis by immunoelectron microscopy. *Br J Dermatol* 1983; 108: 423-431.
9. Murphy G, Fonferko E, Flotte T, Bhan A. Association of basal-lamina defects with epidermal and dermal T6-positive cells: Evidence of Langerhans-cell migration. *Arch Dermatol Res* 1985; 278: 126-132.
10. Kontinen Y, Bergroth V, Visa-Tolvanen K, Reitamo S, Förström L. Cellular infiltrate in situ and response kinetics of human intradermal and epicutaneous tuberculin reactions. *Clin Immunol Immunopathol* 1983; 28: 441-449.
11. Ralfkiaer E, Wantzin G L. In situ immunological characterization of the infiltrating cells in positive patch tests. *Br J Dermatol* 1984; 111: 13-22.
12. Ferguson J, Gibbs J, Swanson Beck J. Lymphocyte subsets and Langerhans cells in allergic and irritant patch test reactions: histometric studies. *Contact Dermatitis* 1985; 13: 166-174.
13. Christensen O, Daniels T, Maibach H. Expression of OKT6 antigen by Langerhans cells in patch test reactions. *Contact Dermatitis* 1986; 14: 26-31.
14. Silberberg-Sinakin I, Baer RL, Thorbecke GJ. Langerhans cells. A review of their nature with emphasis on their immunologic functions. *Progr Allerg* 1978; 24: 268-294.
15. Halliday G, Knight B, Muller H. Reduction in murine Langerhans cell ATPase staining following topical but not systemic treatment with steroid and non-steroid immunosuppressants. *Br J Dermatol* 1986; 114: 83-89.