

Crossed-leg Callosities

NEIL H. COX and ANDREW Y. FINLAY

Department of Dermatology, Western Infirmary, Glasgow, U.K.

Cox NH, Finlay AY. Crossed-leg callosities. *Acta Derm Venereol (Stockh)* 1985; 65: 559-561.

We report five patients in whom localised callosities were found on the dorsum of the feet. This was bilateral in four cases and was due to repetitive minor trauma associated with the sitting posture adopted by the patients. Three of the patients also had psoriasis vulgaris which was clinically dissimilar to the lesions we describe. *Key words: Lichen simplex; Psoriasis.* (Received May 22, 1985.)

N. H. Cox, Department of Dermatology, Western Infirmary, Glasgow, G11 6NT, Scotland, U.K.

Callosities are a common finding on hands and feet, usually associated with occupation, leisure activities, and footwear. Many unusual patterns of callosity have been described (1-3) and their importance in recognition of occupation, and as a differential diagnosis of other skin diseases, has been stressed. We report five patients seen in a period of eight months in whom a distinctive pattern of callosity was recognized on the dorsum of the feet, all cases being caused by the posture adopted when sitting with crossed legs. The relevance of this finding, and its relationship to psoriasis in three of our patients, is discussed.

CASE REPORTS

Case 1

A 38-year-old woman gave a one-year history of mildly pruritic lesions on the dorsum of both feet, and of previous similar lesions on ankles and elbows. Thick callosities were found on the dorsum of both feet over the bony prominence of the distal tarsal bones. The patient admitted that she frequently sat on the floor with legs crossed underneath her, as illustrated diagrammatically in Fig. 1.

Case 2

A 35-year-old woman with a 15-year history of psoriasis vulgaris drew attention to lesions on the dorsum of the feet which were dissimilar to her usual psoriasis. Examination revealed callosities similar to those described for case 1, and this patient also sat with the same posture.

Case 3

A 28-year-old woman gave a one-year history of thickened plaques of skin on the dorsum of both feet. She noticed these especially if sitting cross-legged with the feet inverted, when the plaques were compressed against the floor. She also had psoriasis, but the callosities seen (Fig. 2) were clinically dissimilar to her psoriatic plaques. There were no radiographic abnormalities, but a skin biopsy showed acanthotic, mildly psoriasiform, epidermis and some scarring of dermal collagen.

Case 4

A 30-year-old woman, admitted to hospital for therapy of psoriasis, reported symmetrical lesions on the dorsum of her feet, which were unlike her usual psoriasis. Callosities similar to those described above were found on examination, and she admitted sitting in the posture illustrated in Fig. 1.

Case 5

A 19-year-old man gave a history of intermittent swelling of the dorsum of the left foot. He frequently sat with his left foot pressed against the floor by his right leg, and examination revealed a thick lichenified plaque over the tarsus. He was also noted to have very mobile ankle joints, with active extension to 90° (the dorsum of the foot being in the same longitudinal axis as the tibia). There were no abnormal radiographic findings, and skin biopsy showed mild acanthosis only.

Examination of radiographs of the feet of these patients (two cases) and of an articulated skeleton of the foot, suggested that the usual region of callosity in our patients was overlying the area of apposition of navicular, lateral cuneiform, and cuboid bones.

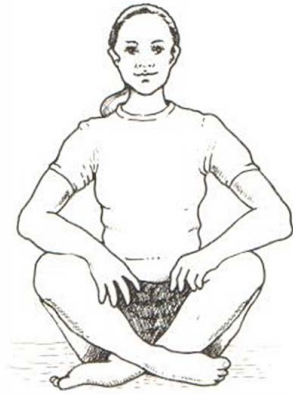

Fig. 1. Posture adopted by patients who developed 'crossed-leg callosities'.

DISCUSSION

Callosities on the dorsum of the feet appear to be a distinctive clinical entity related to sitting posture. Tardieu (4), referred to by Ronchese (1), described calluses on the lateral aspect of the ankles in tailors over a century ago. A similar lesion occurring near the lateral malleolus in Muslims, and ascribed to the posture adopted whilst praying, has been described more recently (3). The cases we describe are similar but occurred in patients in whom the cross-legged posture was neither occupational or religious.

There was a female preponderance in our group of patients, which may be explained by pelvic anatomical differences influencing the sitting posture. This difference between the sexes is also suggested by the fact that all four female patients, but not the male patient,

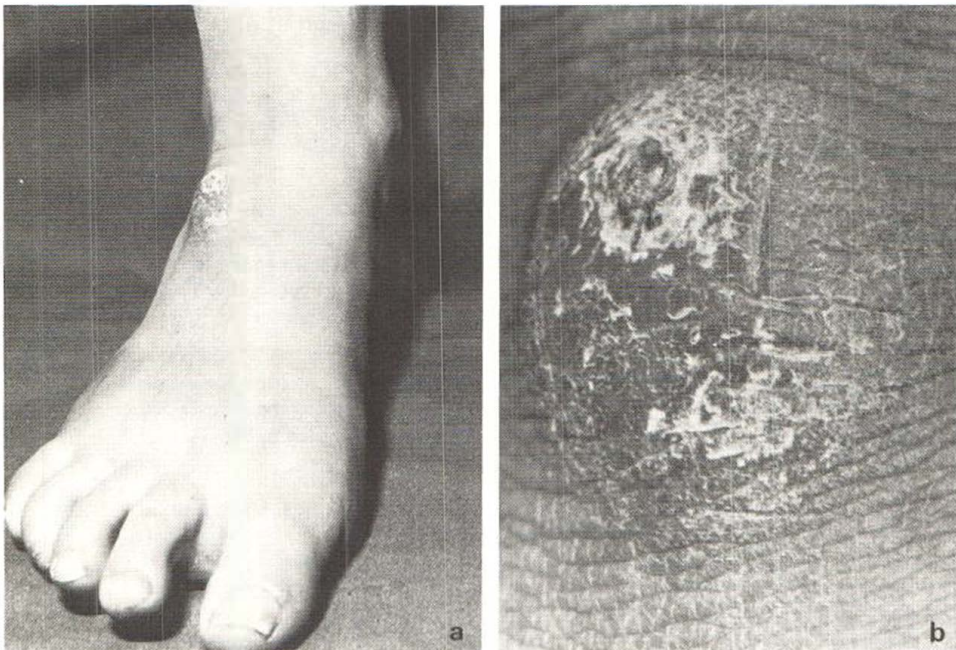


Fig. 2. (a) Callosity on the dorsum of the foot. (b) Close-up of the same lesion.

had bilateral lesions. All patients had very mobile ankle joints, as described for case 5, such that the distal tarsal bones were prominent when sitting cross-legged—in all cases callosities were related to this site being in contact with the floor when sitting. There was a surprising reluctance of the patients to accept this explanation for their foot lesions, in spite of demonstration of how the lesions might arise.

It is interesting that in all three patients with psoriasis the foot callosities appeared lichenified or hyperkeratotic but were not clinically similar to psoriatic plaques elsewhere on the body. Biopsy of one of these foot lesions in one of the psoriatic patients did not show diagnostic features of psoriasis although the epidermis was mildly psoriasiform. Ronchese (1) described traumatic calluses with overlying psoriasis in a patient with a strong family history of psoriasis, and it has been suggested that the sites of predilection of psoriasis are explained by chronic mild trauma (5). Regular local trauma in our three psoriatic patients had not, however, produced typical psoriatic lesions.

When callosities due to the cross-legged posture are being considered in the differential diagnosis of plaques on the dorsum of the feet, the essential points to consider are: 1) an appropriate history of sitting cross-legged; 2) a lack of other factors causing callosity, such as poor-fitting footwear; 3) hyperextensible ankle joints with bony prominence at the site of the callosity. In order to include occupational, religious, and domestic causes of this pattern of callosity, and in order to avoid confusion between 'prayer nodules' of the forehead (2) and of the feet (3), we suggest that 'crossed-leg callosities' may be the most appropriate name for these lesions.

ACKNOWLEDGEMENTS

We are grateful to Dr Shaw Dunn of the Department of Anatomy, University of Glasgow, for his advice. The clinical photographs were provided by the Department of Medical Illustration, Western Infirmary, Glasgow.

REFERENCES

1. Ronchese F. Occupational marks and other physical signs. A guide to personal identification. Grune and Stratton, New York, 1948.
2. Harahap M. Peculiar forehead mark from praying. *Int J Dermatol* 1981; 20: 133.
3. English JSC, Fenton DA, Wilkinson JD. Prayer nodules. *Clin Exp Dermatol* 1984; 9: 97–98.
4. Tardieu A. Mémoire sur les modifications physiques et chimiques que determine dans certaines parties du corps l'exercice des diverses professions, pour servir à la recherche medico-légale de l'identité. *Ann d'hyg publique & de med leg* 1849; 42: 388–423, and 1850; 43: 131–144. Cited by Ronchese (1).
5. Hurley HJ. Papulosquamous eruptions and exfoliative dermatitis. In: Moschella SL, Pillsbury DM, Hurley HJ, eds. *Dermatology*. WB Saunders, Philadelphia: 1975: 414–415.