

## Phenotypic Characterization of Skin-infiltrating Cells in Pagetoid Reticulosis by Monoclonal Antibodies

M. GONZALEZ,<sup>1</sup> M. MARTIN-PASCUAL,<sup>2</sup> J. SAN MIGUEL,<sup>1</sup>  
M. D. CABALLERO<sup>1</sup> and A. LÓPEZ BORRASCA<sup>1</sup>

<sup>1</sup>Division of Haematology-Immunology and <sup>2</sup>Department of Dermatology, Hospital Clínico Universitario, Salamanca, Spain

González M, Martín-Pascual A, San Miguel JF, Caballero MD, López Borrasca A. Phenotypic characterization of skin-infiltrating cells in pagetoid reticulosis by monoclonal antibodies. *Acta Derm Venereol (Stockh)* 1984; 64: 421-424.

The immunological characterization of the infiltrating cells in a patient with a disseminated form of Pagetoid reticulosis (PR) was carried out—in histological section and cell suspensions—by means of a panel of monoclonal antibodies and classical markers (E-rosette and surface immunoglobulins (SIg)). Most of the infiltrating cells were seen to be mature T-lymphocytes with a suppressor/cytotoxic phenotype (T11<sup>+</sup>, T3<sup>+</sup>, T8<sup>+</sup>, T4<sup>-</sup>). The results suggest that this variant of PR represents a special histological type of cutaneous T cell lymphoma. *Key words: Keiron-Goodman disease; Cutaneous T-cell lymphoma; Surface markers.* (Received March 19, 1984.)

M. González Diaz, Division of Haematology-Immunology, Hospital Clínico Universitario, Salamanca, Spain.

Pagetoid reticulosis (PR) is a rare and still puzzling skin disease of which 35 cases have been reported up to the present (1). Clinically the cases can be divided into a localized form, first described by Woringer & Kolopp, and a generalized form described by Keiron & Goodman (2, 3). Histologically, both are characterized by a unique epidermal infiltrate and transmission electron microscope studies showed the presence of large atypical cells in the epidermis which are normally not found in the cutaneous T cell lymphoma (1, 4). The origin of these cells remains to be clarified, although T-lymphocytes, Merckel cells and cells of the monocyte-macrophage series have been considered to play a predominant role (1, 4, 5, 6). The phenotypic characterization of skin-infiltrating cells by monoclonal antibodies (McAb) has not been previously reported.

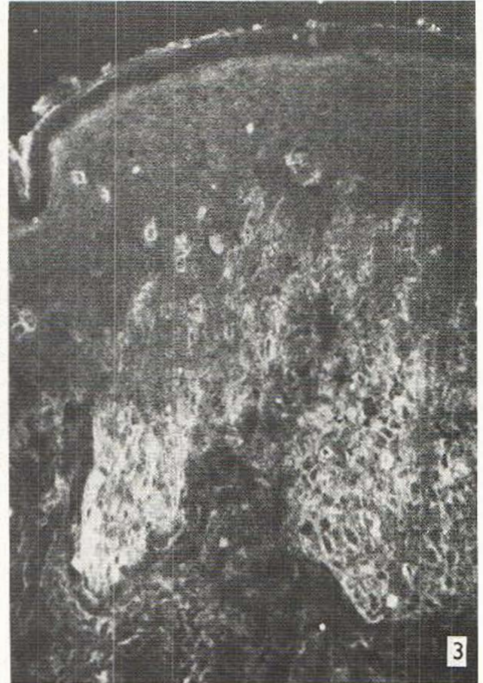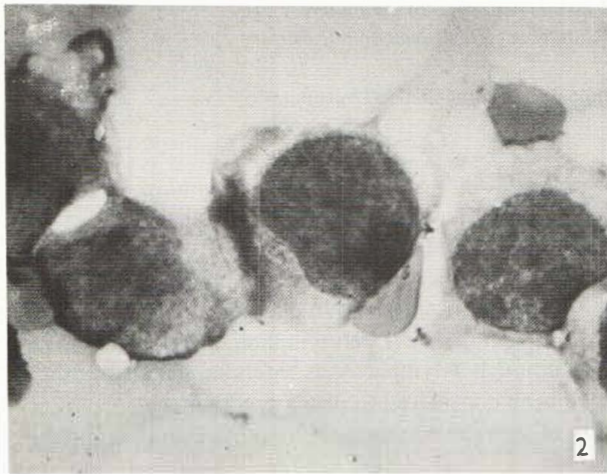
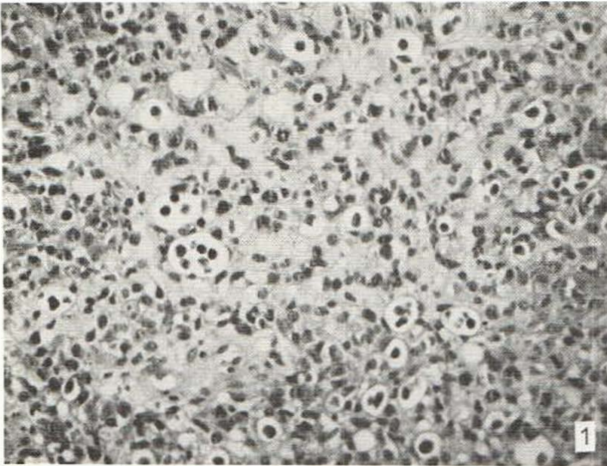
Using a panel of antihuman cell McAb we have found that the infiltrating cells in skin epidermis from a patient with PR expressed the T-cell antigen OKT8 (suppressor/cytotoxic T cells).

## MATERIAL AND METHODS

### Case Report

A 79-year-old woman showed multiple papulo-erythematous lesions with infiltrated edges and exocentric growth. These lesions had developed one year before and initially responded to local treatment with topical N<sub>2</sub> mustard and oral cyclophosphamide. Later, they began to show resistance and new outcrops of cutaneous lesions appeared; some were tumor-like. The immunological study was carried out when the patient showed a relapse of cutaneous lesions. Lymph nodes and visceral infiltration were not observed. No leukocytosis nor circulating Sézary cells could be noted at any time during the evolution of the condition. Histological and electron microscopy studies revealed marked hyperkeratosis with localized areas of parakeratosis and a prominent infiltrate of mononuclear cells particularly in the basal layer of epidermis. Some of these cells were large and hyperchromatic and apparently surrounded by a clear halo—pagetoid aspect (Fig. 1). A diagnosis of PR was established.

*Monoclonal antibodies.* Nine monoclonal antibodies with well-defined specificities were used (7): OKT3 (peripheral T cells), OKT4 (inducer-helper T cells), OKT8 (cytotoxic/suppressor T cells), OKT6 (common thymocytes and Langerhans' cells), OKT9 (transferrin receptor), OKT11 (sheep cell receptor), OKT10 (early thymocyte and replicating lymphoid cells), OKIa 1 (Ia-like antigen) and B<sub>1</sub> (B lymphocytes).



*Fig. 1.* Pagetoid reticulosis. Histological section showing an epidermal pagetoid cellular infiltrate. H & E,  $\times 500$ .

*Fig. 2.* Pagetoid reticulosis. Presence of azurophilic granules in the cell cytoplasm in the cutaneous lesion imprint. M-G-G,  $\times 1000$ .

*Fig. 3.* Pagetoid reticulosis. Reactivity of infiltrating cells in the lower layer of the epidermis with the OKT8 monoclonal antibody (suppressor/cytotoxic T cells).  $\times 250$ .

*Surface marker analysis in skin tissue sections using monoclonal antibodies.* Skin specimens were obtained surgically and placed in RPMI 1640 medium (Flow Laboratory, Irvine Scotland). They were then snap-frozen in liquid  $N_2$  and stored at  $-70^\circ C$  until being sectioned (8). The expression of different antigens was explored by the indirect immunofluorescence technique. Four micron frozen sections of skin were cut (at  $-20^\circ C$ ), allowed to air dry for 30 min and fixed for 2 min in cold acetone. They were then incubated for 30 min in a moist chamber with a saturating amount of monoclonal antibody. Following 3 rinses with phosphate buffered saline solution (PBS), excess liquid was removed from the slide and the sections were overlaid with 100  $\lambda$  of the second antibody (fluorescein conjugated goat anti-mouse IgG (Meloy Lab., Springfield, Va) at a dilution of 1/20. The slides were again incubated in a moist chamber at room temperature for 30 min. After 3 rinses in PBS, the sections were mounted on coverslips with 10% PBS in glycerine and examined under a Leitz Ortholux II fluorescence microscope.

*Surface marker analysis in cell suspensions.* Cell suspensions from skin infiltrates were mechanically extracted by means of a disaggregating homogenizer: (a) Immunofluorescence studies. The expression of different antigens was explored by the binding of monoclonal antibodies on separated infiltrating cells stained by indirect immunofluorescence technique. Briefly,  $1 \times 10^6$  cells resuspended in PBS buffer containing sodium azide and bovine serum albumin were incubated with the monoclonal antibody at the appropriate dilution for 30 min at  $4^\circ C$ . After two washes the cells were resuspended in 50  $\mu$ l of PBS buffer and incubated for another 30 min at  $4^\circ C$  with equal volumes of FITC goat anti mouse immunoglobulin. After washing, the cells were mounted on slides and examined under a fluorescence microscope. (b) Terminal deoxynucleotidyl transferase (TdT), was determined by the



indirect immunofluorescence technique on cytocentrifuge preparations fixed in methanol for 15 min at 4°C. Rabbit anti TdT (Bethesda Research Laboratories) was used as a first layer and a goat anti rabbit antiserum coupled to FITC as the second layer. (c) Rosette formation with sheep red blood cells (SRBC) (E-rosette) and identification of cells with surface immunoglobulins (sIg) using a polyvalent antisera against human immunoglobulins were analysed according to standard techniques. (d) Simultaneous analysis of the Ia antigen and E rosettes (Ia<sup>+</sup> + E<sup>+</sup>). After identification of the Ia antigen by the monoclonal antibody OKIa1 the formation of spontaneous rosettes was carried out to analyze the cells containing both markers (9).

## RESULTS

The cells of the cutaneous lesion imprints were large in size, with a high nuclear/cytoplasmic ratio and contained azurophilic granules in their cytoplasm (Fig. 2).

Immunological analysis of the cell suspension showed a mature T cell suppressor/cytotoxic phenotype (T11<sup>+</sup>, T3<sup>+</sup>, T8<sup>+</sup>, T4<sup>-</sup>). The cells did not express TdT or immature T antigens (T6<sup>-</sup>, T9<sup>-</sup>, T10<sup>-</sup>) (Table I). Ia-antigens were present in 30% of these cells and 34% of the Ia positive cells formed rosettes with sheep erythrocytes.

The infiltrating cells in the histological section were localized in the lower layer of the epidermis and had the same phenotype as that of the cell suspensions (T11<sup>+</sup>, T3<sup>+</sup>, T8<sup>+</sup>, Ia<sup>+/+</sup>) (Fig. 3). A minor population of T6 positive cells was found in the upper layer of the epidermis. Reactivity with the monoclonal antibodies T9, T10 and B1 was negative.

## DISCUSSION

The nature of the infiltrating cells in pagetoid reticulosis (PR) has given rise to considerable discussion (1, 4, 10). Several reports have suggested a T lymphoid cell origin according to (i) the clinical similarities of the generalized form of PR and mycosis fungoides (MF) (3) and (ii) ultrastructural and immunological findings (E-rosette forming cells) (1, 4). However, other origins for the infiltrating cells, such as Merckel cells and histocytes (5, 6) have been postulated. Using a panel of McAb together with classical markers we have shown that these cells in suspension form E rosettes and express specific mature T antigens with a suppressor/cytotoxic phenotype (T11<sup>+</sup>, T3<sup>+</sup>, T8<sup>+</sup>, T4<sup>-</sup>). Furthermore, 30% of the cells expressed the Ia antigen present in the T-stimulated lymphocytes (9). Morphological studies with light microscopy showed the presence of azurophilic granules in the cytoplasm which have been described in the suppressor/cytotoxic T lymphocytes (11). Finally, the infiltrating cells of the lower layer of the epidermis in the histological section had an identical phenotype to that of the cell suspension, thereby confirming for the first time the suppressor/cytotoxic phenotype of this condition.

Table I. *Pagetoid reticulosis Phenotypic characterization in cell suspension from skin infiltrated*

All results are expressed in percentages. Negative results (-): <5% positive cells

E-rosette	71	OKT9	-
OKT11	76	OKT10	-
OKT3	80	OKIa1	30
OKT4	7	B1	-
OKT8	72	sIg	-
OKT6	5	Ia <sup>+</sup> + E <sup>+</sup>	34
		TdT	-

The immunological differences between MF (helper phenotype in most cases) and PR (suppressor/cytotoxic phenotype) could explain the different histological findings in each; however, this would be difficult to substantiate since rare cases of MF with the suppressor/cytotoxic phenotype have been reported (12). It would thus be necessary to consider other factors—the immune state of the patient, a different oncogenic stimulus etc—in order to explain the different characteristics in both processes.

## REFERENCES

1. Schmoeckel Ch, Burg G, Hoffmann-Fezer G, Wolff HH, Braun-Falco O. Pagetoid reticulosis—A rare entity ? In: Goos M, Christophers E, eds. *Lymphoproliferative diseases of the skin*. Berlin: Springer-Verlag, 1982: 217–221.
2. Woringer F, Kolopp P. Lésion érythémato-squameuse polycyclique de l'avantbras depuis 6 ans chez un garçonnet de 13 ans. Histologiquement infiltrat intraépidermique d'apparence tumorale. *Ann Dermatol Syphiligr* 1939; 10: 945–958.
3. Ketron LW, Goodman MH. Multiple lesions of the skin apparently of epithelial origin resembling clinically mycosis fungoides. *Arch Dermatol Syphilol* 1931; 24: 758–777.
4. Braun-Falco O, Schmoeckel C, Burg G, Ryckmann S. Pagetoid reticulosis: A further case report with a review of the literature. *Acta Derm Venereol (Stockh) (suppl. 85)* 1979; 59: 11–21.
5. Revuz J, Pouset F, Allegret C, Wechsler J, Jouffray L, Touraine R. La "reticuloïse pagetoïde" de Woringer et Kolopp. Une maladie de la cellule de Merkel. *Ann Derm Venereol* 1977; 104: 312–320.
6. Chu AC, MacDonald DM. Pagetoid reticulosis: A disease of histiocytic origin. *Br J Dermatol* 1980; 103: 147–157.
7. Foon KA, Schroff RW, Gale RP. Surface markers on leukemia and lymphoma cells: recent advances. *Blood* 1982; 60: 1–19.
8. Fithian E, Kung P, Goldstein G, Rubinfeld M, Fenoglio C, Edelson R. Reactivity of Langerhans cells with hybridoma antibody. *Proc Natl Acad Sci USA* 1981; 78: 2 541–2 544.
9. Reinherz EL, Kung PC, Pesando JM, Ritz J, Goldstein G, Schlossman SF. The determinants on human T-cell subsets defined by monoclonal antibody. Activation stimuli required for expression. *J Exp Med* 1979; 150: 1472–1482.
10. McDonal DM. Pagetoid reticulosis—A problem of histogenesis. In: Goos M, Christophers E, eds. *Lymphoproliferative disease of the skin*. Berlin: Springer-Verlag, 1982: 217–221.
11. Costello C, Catovsky D, O'Brien M, Morilla S. Chronic T-cell leukaemias. I. Morphology, cytochemistry and ultrastructure. *Leuk Res* 1980; 4: 463–476.
12. Haynes BF, Henseley LL, Jagasothy BV. Phenotypic characterization of skin-infiltrating T-cells in cutaneous T-cell lymphoma: Comparison with benign cutaneous T-cell infiltrates. *Blood* 1982; 60: 463–473.