

Paediatric Acute Generalized Exanthematous Pustulosis Induced by Paracetamol with High Serum Levels of Interleukin-8 and -22: A Case Report

Takatsune Umayahara, Takatoshi Shimauchi, Toshiharu Fujiyama, Taisuke Ito, Satoshi Hirakawa and Yoshiki Tokura*

Department of Dermatology, Hamamatsu University School of Medicine, 1-20-1 Handayama, Higashi-ku, Hamamatsu 431-3192, Japan. *E-mail: tokura@hama-med.ac.jp

Accepted Jul 4, 2012; Epub ahead of print Sep 25, 2012

Acute generalized exanthematous pustulosis (AGEP) is a rare skin disorder, characterized by acute development of numerous, pin-head sized, non-follicular, sterile pustules that usually begin in intertriginous folds with high fever and neutrophilia (1–3). The condition is frequently induced by hypersensitivity reaction to drugs (1). AGEP usually affects adults; paediatric cases have rarely been reported (4–7). We describe here a case of paediatric AGEP induced by paracetamol. High levels of serum interleukin (IL)-8 and IL-22 observed in our patient suggest a role of these cytokines/chemokines in the pathogenesis of AGEP.

CASE REPORT

A 7-year-old boy was referred to us with a generalized eruption. Five days prior to our initial examination, the patient had developed upper respiratory symptoms, diagnosed as influenza A, and he had received oral paracetamol and oseltamivir. Two days after the start of treatment, he developed an itchy exanthema on the trunk with a high fever. On examination, the patient had an erythematous eruption on his trunk (Fig. 1a) and the proximal parts of his arms and thighs. Numerous small pustules, less than 1 mm in diameter, were present, especially on the inner aspects of the thighs (Fig. 1b), axillae, and lumbar region. Slightly swollen cervical lymph nodes were palpable. Laboratory investigations showed a normal leukocyte count, but C-reactive protein was elevated (1.4 mg/dl; normal <0.1 mg/dl).

Histopathologically, there were subcorneal neutrophilic pustules and a dermal lymphocytic infiltrate (Fig. 1c). We determined the likelihood of AGEP by using the reported scoring system, which can be used to identify cases of AGEP based on morphology, course and histology of the skin reaction (8). Our patient had a score of 11, indicating a definite diagnosis of AGEP. The culprit drugs and results of lymphocyte transformation test performed 19 days after disease onset were as follows (stimulation index [SI] ≥ 1.8 is considered positive): paracetamol, 1,516 cpm (SI 2.75); oseltamivir, 450 cpm (SI 0.81); and no-addition control, 551 cpm. We thus diagnosed the eruption as AGEP induced by paracetamol. Discontinuation of paracetamol and oral administration of prednisolone (5 mg daily for 7 days) improved the patient's skin lesions within 2 weeks.

The serum level of IL-8 was measured with Cytometric Bead Array (BD Biosciences, San Diego, CA, USA), serum levels of IL-17A, IL-22 and TNF- α with enzyme-linked immunosorbent assay (ELISA) kits (R&D Systems, Minneapolis, MN, USA), and that of chemerin with an ELISA kit (Millipore, St Charles, MO, USA) in the patient and 4 healthy individuals. These cytokines and chemokines may be involved in the accumulation of neutrophils in the epidermis (9, 10). A blood sample was taken from the patient 5 days after the onset of eruption. It is noted that IL-8 and IL-22 were markedly elevated in the patient, compared with the normal individuals (Table I). IL-17 and tumour necrosis factor- α (TNF- α) were below the level of detection in both patient and normal healthy controls. Chemerin, a chemoattractant for plasmacytoid dendritic cells (pDC) (11, 12), was not increased in the patient compared with the normal subjects.

DISCUSSION

AGEP should be differentiated from pustular psoriasis (von-Zumbusch type). In our patient, the skin eruption and high fever were improved by discontinuation of paracetamol and 7-day administration of prednisolone (5 mg daily), and there was no recurrence thereafter. This shorter duration supports the diagnosis of AGEP. The SI of 2.75 in a lymphocyte stimulation test was significantly high (13). The possibility of the causative role of infection could not be completely ruled out, but at least paracetamol contributed to the eruption,

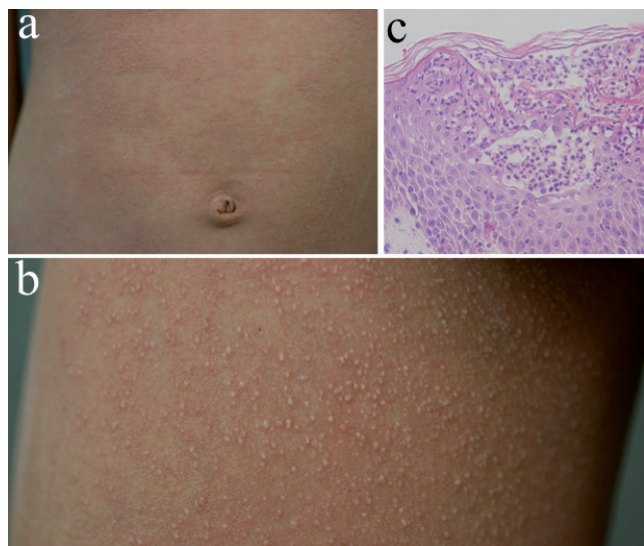


Fig. 1. Clinical and histopathological appearances. (a) Clinical appearance, showing an erythematous eruption present on the trunk. (b) Close-up view, showing multiple small pustules on the thigh. (c) Histopathology, exhibiting subcorneal collection of many neutrophils in the epidermis (haematoxylin and eosin (HE), original magnification $\times 200$).

Table I. Serum levels of cytokines/chemokines

Cytokines/chemokines	Serum levels	
	Patient	Normal subjects (n = 4, mean \pm SD)
IL-8	274.6 pg/ml	1.29 \pm 1.49 pg/ml
IL-17A	UDL	UDL (all)
IL-22	25.3 pg/ml	UDL (all)
TNF- α	UDL	UDL (all)
Chemerin	176.8 pg/ml	229.0 \pm 31.0 pg/ml

UDL: under the detection level; SD: standard deviation.

and infection may participate in the occurrence of the eruption. Although AGEP is generally considered to be an adult disease (1–3), recent reports suggest that it occasionally occurs in paediatric individuals (4–7). Thus, children may develop AGEP upon administration of antibiotics or non-steroidal anti-inflammatory drugs, as seen in our patient.

As the lymphocyte transformation test with a causative drug usually shows a high SI, drug-specific T cells are thought to mediate AGEP (2, 3). Drug-specific CD4⁺ and CD8⁺ T cells play an important role by producing neutrophil chemo-attractant IL-8. To explain the mechanism of subcorneal accumulation of neutrophils, however, a certain population of drug-specific T cells are thought to stimulate keratinocytes to produce IL-8, and the keratinocyte-derived IL-8 may contribute to the accumulation of neutrophils in the lesional epidermis. In fact, the elevated expression of IL-8 was observed in keratinocytes as well as infiltrating mononuclear cells (3).

Th17 cell is a CD4⁺ T helper cell subset capable of producing IL-17 and IL-22, and dysregulated Th17 responses mediate a variety of skin inflammatory conditions, such as psoriasis (9) and atopic dermatitis (14). IL-17 and IL-22 exert a strong synergistic effect on the production of IL-8 by keratinocytes (14). Increased frequencies of Th17 cells and high levels of IL-22 have been reported in AGEP (15, 16).

Our study showed an increase in serum IL-8 and IL-22 in a paediatric patient with AGEP. Since the amount of IL-17A was below the limit of detection, the involvement of Th17 cells remains unclear in this single case report. In order to maintain Th17 cells, IL-23 released from dendritic cells (DCs) is important (10), and DCs are activated by TNF- α in an autocrine manner (9). Alternatively, type I interferon derived from pDCs may indirectly lead to Th17 cell stimulation with the help of chemerin serving as a pDC-chemo-attracting factor (11). While patients with psoriasis have higher levels of chemerin (12), our AGEP patient did not have an increased level of chemerin in the peripheral blood, suggesting that pDC are not substantially involved in the pathogenesis. Although IL-17 and/or IL-22 may be involved in the pathogenesis of AGEP, the exact role of Th17 cells in this drug eruption, and their stimulation mechanism, are as yet unknown.

The authors declare no conflicts of interest.

REFERENCES

- Sidoroff A, Dunant A, Viboud C, Halevy S, Bouwes Bavinck JN, Naldi L, et al. Risk factors for acute generalized exanthematous pustulosis (AGEP): results of a multinational case-control study (EuroSCAR). *Br J Dermatol* 2007; 157: 989–996.
- Schaerli P, Britschgi M, Keller M, Steiner UC, Steinmann LS, Moser B, et al. Characterization of human T cells that regulate neutrophilic skin inflammation. *J Immunol* 2004; 173: 2151–2158.
- Britschgi M, Steiner UC, Schmid S, Depta JP, Senti G, Bircher A, et al. T-cell involvement in drug-induced acute generalized exanthematous pustulosis. *J Clin Invest* 2001; 107: 1433–1441.
- Miteva L, Kadurina M, Schwartz RA. Childhood acute generalized exanthematous pustulosis induced by oral ketoconazole. *Acta Dermatovenerol Croat* 2010; 18: 267–270.
- Poliak N, Elias M, Cianferoni A, Treat J. Acute generalized exanthematous pustulosis: the first pediatric case caused by a contrast agent. *Ann Allergy Asthma Immunol* 2010; 105: 242–243.
- Ozmen S, Misirlioglu ED, Gurkan A, Arda N, Bostanci I. Is acute generalized exanthematous pustulosis an uncommon condition in childhood? *Allergy* 2010; 65: 1490–1492.
- Riten K, Shahina Q, Jeannette J, Palma-Diaz MF. A severe case of acute generalized exanthematous pustulosis (AGEP) in a child after the administration of amoxicillin-clavulanic acid: brief report. *Pediatr Dermatol* 2009; 26: 623–625.
- Sidoroff A, Halevy S, Bavinck JN, Vaillant L, Roujeau JC. Acute generalized exanthematous pustulosis – a clinical reaction pattern. *J Cutan Pathol* 2001; 28: 113–119.
- Zaba LC, Fuentes-Duculan J, Eungdamrong NJ, Johnson-Huang LM, Nogales KE, White TR, et al. Psoriasis is characterized by accumulation of immunostimulatory and Th1/Th17 cell-polarizing myeloid dendritic cells. *J Invest Dermatol* 2009; 129: 79–88.
- Zheng Y, Danilenko DM, Valdez P, Kasman I, Eastham-Anderson J, Wu J, et al. Interleukin-22, a Th17 cytokine, mediates IL-23-induced dermal inflammation and acanthosis. *Nature* 2007; 445: 648–651.
- Albanesi C, Scarponi C, Pallotta S, Daniele R, Bosisio D, Madonna S, et al. Chemerin expression marks early psoriatic skin lesions and correlates with plasmacytoid dendritic cell recruitment. *J Exp Med* 2009; 206: 249–258.
- Nakajima H, Nakajima K, Nagano Y, Yamamoto M, Tarutani M, Takahashi M, et al. Circulating level of chemerin is upregulated in psoriasis. *J Dermatol Sci* 2010; 60: 45–47.
- Sawada Y, Nakamura M, Tokura Y. Generalized fixed drug eruption caused by pazufloxacin. *Acta Derm Venereol* 2011; 91: 600–601.
- Koga C, Kabashima K, Shiraishi N, Kobayashi M, Tokura Y. Possible pathogenic role of Th17 cells for atopic dermatitis. *J Invest Dermatol* 2008; 128: 2625–2630.
- Nakamizo S, Kobayashi S, Usui T, Miyachi Y, Kabashima K. Clopidogrel-induced acute generalized exanthematous pustulosis with elevated Th17 cytokines levels as determined by a drug lymphocyte stimulation test. *Br J Dermatol* 2010; 162: 1402–1403.
- Kabashima R, Sugita K, Sawada Y, Hino R, Nakamura M, Tokura Y. Increased circulating Th17 frequencies and serum IL-22 levels in patients with acute generalized exanthematous pustulosis. *J Eur Acad Dermatol Venereol* 2011; 25: 485–488.