

## QUIZ SECTION

### Hypopigmented Patches in a Caucasian Male: A Quiz

Izelda M. C. Costa and Pedro C. Queiroz Zancanaro\*

Hospital Universitario de Brasilia – HUB/UnB, SQSW 304 Bl. C Apt. 402 70673403 Brasilia DF, Brazil. \*E-mail: zancanaro@unb.br

A 55-year-old Caucasian male presented with white spots on his right flank, sacrum and popliteal fossae, which had been present for 6 months, associated with discrete pruritus (Fig. 1 a and b). He reported that the lesions diminished after sun exposure and he denied worsening factors. The patient reported no fever or weight loss. He had an unremarkable past and no family history of cancer.

No lymphadenopathy was noted. The patient underwent lesion biopsy (flank and sacral) and histopathological examination (Fig. 1c). Epidermotropism was observed. Immunohistochemistry revealed mononuclear cells with T-cell phenotype CD3 and CD45 R0.

*What is your diagnosis? See next page for answer.*

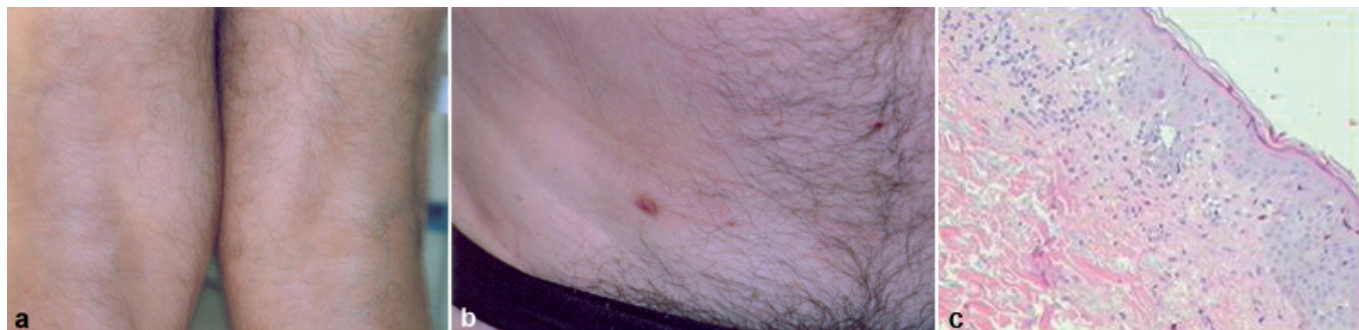


Fig. 1. Hypopigmented macules, with ill-defined irregular borders, plain texture, measuring 12–20 cm, observed at (a) the bilateral popliteal areas and (b) the right flank. The purple papule corresponds to the biopsy scar. (c) Histopathology showing multifocal mononuclear infiltration at papillary dermis, with scant cytoplasm and round, elongated, hyperchromatic nuclei (H&E  $\times$  400).

doi: 10.2340/00015555-0736

## ANSWERS TO QUIZ

**Hypopigmented Patches in a Caucasian Male: Comment**

*Acta Derm Venereol* 2010; 90: 109–111 (contd).

*Diagnosis:* **Hypopigmented mycosis fungoides**

Mycosis fungoides (MF) is part of non-Hodgkin's T-cell lymphomas, primarily impairing the skin (1), with an incidence of 1000 cases per year in the USA more frequently on the sixth decade of life. Male patients are affected twice as frequently as women. Histopathology and immunohistochemistry may evidence Pautrier abscesses, vacuolated lymphocytes, epidermotropism, larger epidermal than dermal lymphocytes and hypercircumvolution nuclei.

The classical histopathology of MF is not found in the hypopigmented variant, which is more common in young (mean 35 years) African-American and Asian patients, with no gender preference (2, 3). Although it has unknown physiopathology, there are reports of decreased melanogenesis due to a reduced number of melanocytes and presence of incomplete melanosomes at electron microscopy. Similarly to vitiligo, hypopigmented mycosis fungoides has CD8+ T lymphocytes infiltration, in contrast to CD4+ clones in the classic form (4).

The treatment options include ultraviolet A radiation, occlusive corticosteroids, electron beam, bis-chloronitrosurea (carmustine), ultraviolet (UV)A and UVB phototherapy, topical nitrogen mustard, imiquimod (5) and tacrolimus. The psoralen and UVA (PUVA) treatment for stage Ia and Ib has been effective and completely repigmented 85% of patients. Recurrences are common, but repeated phototherapy is effective (6).

Hypopigmented mycosis fungoides is frequently underdiagnosed and there is a 10-year delay between the onset of hypopigmented lesions and the correct diagnosis (7). Hypopigmented macules are frequent complaints at dermatological visits. A prevalence of 4.7% is estimated among Caucasians (8, 9). Numerous diseases should be part of

differential diagnosis, e.g. tinea corporis, pityriasis alba, undetermined Hansen's disease, vitiligo, adult atopic dermatitis, hypopigmented sarcoidosis and post-inflammatory hypopigmentation (10).

## REFERENCES

1. El-Darouti MA, Marzouk SA, Azzam O, Fawzi MM, Abdel-Halim MR, Zayed AA, et al. Vitiligo vs. hypopigmented mycosis fungoides (histopathological and immunohistochemical study, univariate analysis). *Eur J Dermatol* 2006; 16: 17–22.
2. Werner B, Brown S, Ackerman AB. "Hypopigmented mycosis fungoides" is not always mycosis fungoides! *Am J Dermatopathol* 2005; 27: 56–67.
3. Singh ZN, Tretiakova MS, Shea CR, Petronic-Rosic VM. Decreased CD117 expression in hypopigmented mycosis fungoides correlates with hypomelanosis: lessons learned from vitiligo. *Mod Pathol* 2006; 19: 1255–1260.
4. Chiam LY, Chan YC. Solitary plaque mycosis fungoides on the penis responding to topical imiquimod therapy. *Br J Dermatol* 2007; 156: 560.
5. Akaraphanth R, Douglass MC, Lim HW. Hypopigmented mycosis fungoides. Treatment and a 6(1/2)-year follow-up of 9 patients. *J Am Acad Dermatol* 2000; 42: 33–39.
6. Vanderhooft SL, Francis JS, Pagon RA, Smith LT, Sybert VP. Prevalence of hypopigmented macules in a healthy population. *J Pediatr* 1996; 129: 355–361.
7. Stone ML, Styles AR, Cockerell CJ, Pandya AG. Hypopigmented mycosis fungoides: a report of 7 cases and review of the literature. *Cutis* 2001; 67: 133.
8. Kazakov DV, Burg G, Kempf W. Clinicopathological spectrum of mycosis fungoides. *J Eur Acad Dermatol Venereol* 2004; 18: 397–415.
9. Lambroza E, Cohen SR, Phelps R, Lebwohl M, Braverman IM, DiCostanzo D. Hypopigmented variant of mycosis fungoides: demography, histopathology, and treatment of seven cases. *J Am Acad Dermatol* 1995; 32: 987–993.
10. Whitmore SE, Simmons-O'Brien E, Rotter FS. Hypopigmented mycosis fungoides. *Arch Dermatol* 1994; 130: 476–480.