

## Perifollicular Xanthomas Associated with Epidermal Growth Factor Receptor Inhibitor Therapy

Tatiana Eames, Julia Kroth, Michael J. Flaig, Thomas Ruzicka and Andreas Wollenberg\*

Department of Dermatology and Allergy, Ludwig-Maximilian-University, DE-80337 Munich, Germany. \*E-mail: wollenberg@lrz.uni-muenchen.de  
Accepted October 26, 2009.

Sir,

Epidermal growth factor receptors (EGFR) play an important role in the development and progression of many solid tumours. Numerous cell functions, such as cell proliferation, differentiation and angiogenesis, depend on EGFR activation. Moreover, EGFR is over-expressed in many solid tumours (e.g. up to 80% of colorectal cancer and up to 93% of non-small-cell lung cancer) and is an important target structure in tumour therapy of patients refractory or intolerant to chemotherapy. The chimeric EGFR-blocking monoclonal antibody cetuximab, the fully human EGFR-blocking monoclonal antibody panitumumab, and the low-molecular weight tyrosine kinase inhibitors gefitinib and erlotinib are the most frequently used EGFR inhibitors. As EGFR is also expressed in normal epidermis, sweat glands, sebaceous glands and the outer root sheath of the hair follicle, many cutaneous side-effects are frequently encountered during its therapeutic blockade. Acneiform skin reactions are most common, but xerosis, hair and nail changes have also been described (1–3).

We report here the case of a 43-year-old woman who developed a clinically distinct, yellowish papular eruption within the borders of an otherwise typical acneiform skin eruption on her cheeks and sporadically on the chest during treatment change from cetuximab to panitumumab.

### CASE REPORT

A 43-year-old woman was diagnosed with colorectal adenocarcinoma and ovarian, pulmonary and hepatic metastases in October 2004. Her skin had always been healthy. Anti-neoplastic treatment was started with oxaliplatin and 5-fluoro-uracil. Due to tumour progression, the therapy was switched to second-line chemotherapy with bevacizumab and 5-fluoro-uracil. Because of further local progression, a third-line tumour therapy with cetuximab was initiated in February 2008.

Five days after starting cetuximab treatment, an intense, pruritic, acneiform rash appeared on the face, spreading to the neck, chest and upper back (Fig. 1a). Physical examination revealed

widely disseminated inflammatory papules, papulopustules and nodules on an extensive erythema. Coagulase-negative *Staphylococcus* was cultured from the lesions. Laboratory tests showed elevated liver enzymes attributed to the liver metastases, but normal leukocyte counts, blood lipids and C-reactive protein.

Diagnosis of a cetuximab-induced acneiform eruption was made, and sporadic topical treatment was performed with nadifloxacin and prednicarbate cream, as well as betamethasone valerate/fusidic acid cream. Systemic therapy with tetracyclines or retinoids was offered, but was refused by the patient. The skin lesions remained stable during therapy, but did not heal either. After one month of treatment with cetuximab, our patient developed xerosis, followed by pulpitis sicca, fissures on hands and feet, as well as paronychia, recurrent aphthous stomatitis and hypertrichosis of the eyelashes.

In October 2008 numerous small soft yellowish papules appeared on both cheeks and sporadically on the chest. At the same time, therapy was changed from cetuximab to panitumumab because of tumour progression. Within 3 weeks of panitumumab therapy, the lesions increased in number and size and changed into dense yellowish papules (Fig. 1b). A skin biopsy from the left cheek revealed a granulomatous reaction in perifollicular distribution (Fig. 2a), rich in xanthomatized macrophages bearing large vacuoles. Furthermore, remnants of pilosebaceous units were seen along with foreign body type multinucleated macrophages phagocytosing hair shaft fragments (Fig. 2b). Fungal infection was excluded by periodic acid-Schiff (PAS) stain.

Due to progression of the tumour, panitumumab therapy was terminated in March 2009. A few weeks later, all skin changes except the follicular xanthoma had disappeared. The large yellow papules remained unchanged for 3 months, but started to regress slowly after 5 months of follow-up.

### DISCUSSION

We present a clinically distinctive perifollicular xanthomatous skin reaction of yellowish papules arising in an otherwise typical EGFR inhibitor-induced acneiform skin reaction, which occurred in a 43-year-old Caucasian colorectal cancer patient.

Since EGFR is expressed in skin and especially in proliferating, undifferentiated keratinocytes of the basal layers of the epidermis and outer root sheath of the hair follicle, it is not surprising that the use of EGFR inhibitors leads to the development of cutaneous side-effects (5).

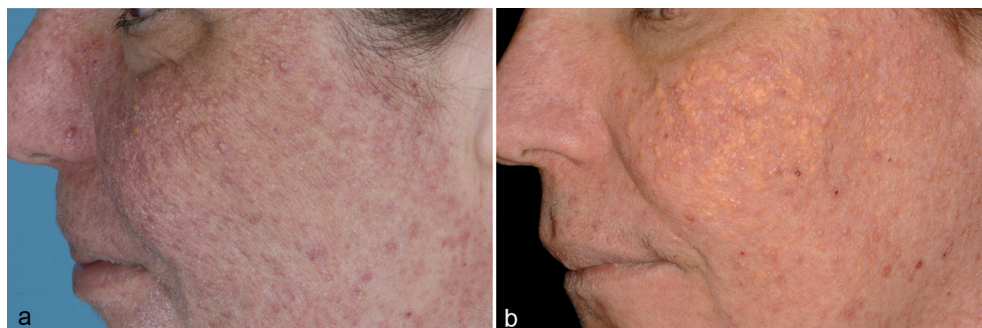


Fig. 1. (a) The patient's early phase acneiform reaction induced by cetuximab and late phase perifollicular xanthomatous reaction, presenting as (b) yellowish papules on the left cheek.

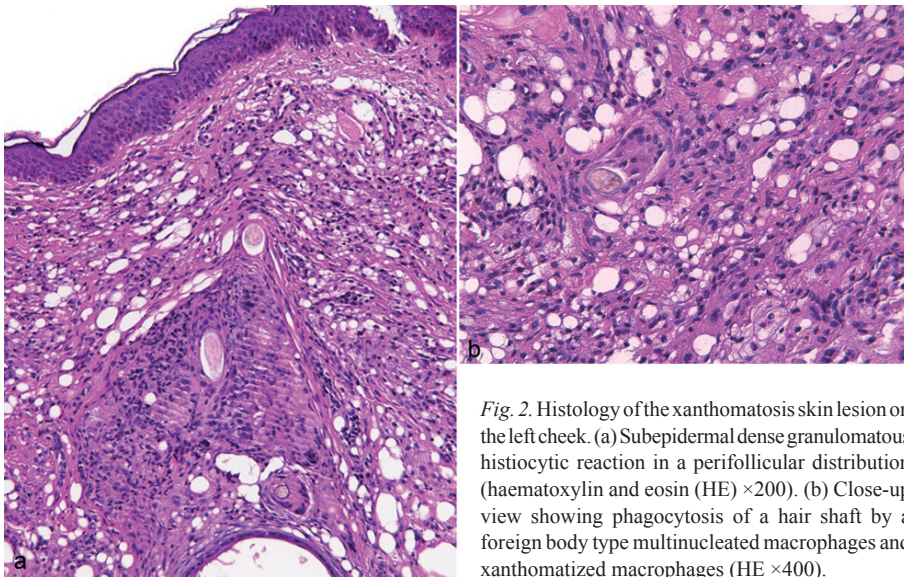


Fig. 2. Histology of the xanthomatous skin lesion on the left cheek. (a) Subepidermal dense granulomatous histiocytic reaction in a perifollicular distribution (haematoxylin and eosin (HE)  $\times 200$ ). (b) Close-up view showing phagocytosis of a hair shaft by a foreign body type multinucleated macrophages and xanthomatized macrophages (HE  $\times 400$ ).

Acneiform skin eruptions are the most frequent cutaneous side-effects of an EGFR blockade and are therefore well characterized. In most patients, this acneiform eruption is more or less confined to the seborrhoeic areas. These follicular skin lesions are not preceded by visible comedones and therefore cannot be considered as acne vulgaris. In contrast to acneiform eruptions caused by other drugs, EGFR inhibitor-induced skin lesions may be accompanied by pruritus (1).

Other recognized skin toxicities following EGFR inhibition are xerosis, teleangiectasia, hyperpigmentation, fissures on hands and feet, mucositis including intraoral aphthosis and stomatitis, hair changes (e.g. curlier, finer hair on scalp, growth and curling of eyelashes and eyebrows) and nail changes, such as paronychia. Urticarial and anaphylactoid reactions have also been observed during intravenous administration of cetuximab, but are rarely reported in Europe (5, 7, 8).

The exact mechanism of the skin reactions after EGFR inhibitors is unknown, although most experts will agree on the consequence of inhibition of EGFR signalling on epidermal and adnexal epithelium (8). Increased apoptosis, altered keratinocyte differentiation, thinning of the stratum corneum and an inflammatory infiltrate, as well as enlarged hair follicles and keratin plugs are well-described histological features of EGFR-induced skin eruptions (5). EGFR-targeted therapies may directly affect the immune system by unblocking cutaneous chemokine production, resulting in leukocyte chemotaxis and infiltration in the skin (1).

We only can speculate about the pathogenesis of our patient's distinctive reaction pattern. We assume a destructive absceding folliculitis, with a rupture of the acroinfundibulum as the initial event, corresponding to the clinical appearance of an acneiform eruption. Sustained by the patient's refusal of systemic therapeutic intervention, the destructive inflammatory process con-

tinued until complete destruction of the affected follicular sebaceous unit. Resorption of the destroyed epithelial tissue and sebaceous glands requires accumulation of macrophages, ultimately resulting in a histiocytic, partly xanthomatous clearing reaction. This xanthomatous clearing reaction causes the clinically distinctive, yellowish appearance. The time course of events suggests panitumumab as the main causative agent for this reaction, but other factors, such as the preceding cetuximab treatment or intermittent topical therapy, are also possible.

Differential diagnosis for our patient, if the clinical context allowed any, would be eruptive xanthoma. This would also comprise the closest histological differential diagnoses, but eruptive xanthoma is neither perifollicular localized nor predominantly present on the cheeks. Potential treatment options for the disseminated follicular xanthomas would be ablative lasers such as CO<sub>2</sub>- and Er:YAG-laser, or the semi-selective coagulating argon-laser.

## REFERENCES

1. Segart S, van Cutsem E. Clinical signs, pathophysiology and management of skin toxicity during therapy with epidermal growth factor receptor inhibitors. *Ann Oncol* 2005; 16: 1425–1433.
2. Klein E, Tietze J, Wollenberg A. Cutaneous side effects of EGFR inhibitors and their management. *Allergo J* 2006; 15: 559–565.
3. Bierhoff E, Seifert HW, Dirschka T. Hautveränderungen nach Blockade des Epidermal-growth-factor-Rezeptors. *Pathologe* 2006; 27: 53–56.
4. Melosky B, Burkes R, Rayson D, Alcindor T, Shear N, Lacoutre M. Management of skin rash during EGFR-targeted monoclonal antibody treatment for gastrointestinal malignancies: Canadian recommendations. *Curr Oncol* 2009; 16: 16–26.
5. Segart S, Taberner J, Chosidow O, Dirschka T, Elsner J, Mancini L, et al. The management of skin reactions in cancer patients receiving epidermal growth factor receptor targeted therapies. *J Dtsch Dermatol Ges* 2005; 3: 599–606.
6. Bunn PA, Frankling W. Epidermal growth factor receptor expression, signal pathway, and inhibitors in non-small cell lung cancer. *Semin Oncol* 2002; 29: 38–44.
7. Braun-Falco M, Holtmann C, Lordick F, Ring J. Follikuläre Arzneimittelreaktion auf Cetuximab. *Hautarzt* 2006; 57: 701–704.
8. Agero ALC, Dusza SW, Benvenuto-Andrade C, Busam KJ, Myskowski P, Halpern AC. Dermatologic side effects associated with the epidermal growth factor receptor inhibitors. *J Am Acad Dermatol* 2006; 55: 657–670.
9. Gutzmer R, Wefel T, Kapp A, Elsner J. Kutane Nebenwirkungen einer EGF-Rezeptor-Blockade und deren Management. *Hautarzt* 2006; 57: 509–513.