

Photodynamic Therapy for Distal and Lateral Subungual Toenail Onychomycosis Caused by *Trichophyton rubrum*: Preliminary Results of a Single-centre Open Trial

Eleni Sotiriou¹, Thalia Koussidou-Ermonti², George Chaidemenos², Zoi Apalla¹ and Demetris Ioannides¹

¹First Dermatology Department, Aristotle University Thessaloniki, ²State Hospital for Skin and Venereal Diseases, 8, Papakyriazi Str., GR-54645 Thessaloniki, Greece. E-mail: elenasotiriou@yahoo.gr

Accepted October 19, 2009.

Sir,

Onychomycosis of the toenails is a widespread and chronic disease, especially in the elderly. The causative agent in approximately 90% of cases is *Trichophyton rubrum*. A combination of topical and systemic therapies seems to be the ideal approach in the treatment (1). However, as many patients have conditions that contraindicate the administration of systemic anti-fungals, and as topical treatments alone are able to control cases of only mild to moderate severity, it is necessary to develop new safe and effective strategies for the treatment of onychomycosis.

The use of photodynamic therapy (PDT) has extended in many fields, including that of antimicrobial chemotherapy (1). *In vitro* studies have demonstrated that *T. rubrum* is able to metabolize 5-aminolevulinic acid (ALA) to protoporphyrin IX, and that PDT leads to significant reduction in its growth (2–5).

The objective of the present study was to evaluate the efficacy of ALA-PDT in the treatment of distal and lateral subungual onychomycosis (DLSO) of the toenails caused by *T. rubrum*.

PATIENTS AND METHODS

Thirty Caucasians (20 men, 10 women) patients were enrolled in the study (mean age 59.6 years, range 41–81). Eligibility requirements for enrolment were: (i) clinical features of distal and lateral subungual toenail onychomycosis, (ii) positive direct microscopic examination for fungal elements, (iii) identification of *T. rubrum* in cultures of Sabouraud dextrose agar and (iv) concomitant conditions that did not allow systemic treatment with anti-fungal agents.

The nail plate was treated for 10 consecutive nights with 20% urea ointment under occlusion and could thus be removed easily with the use of forceps. Patients underwent the following therapeutic procedure: 20% 5-aminolevulinic acid (MEDAC GmBH Hamburg) was applied under an occlusive dressing topically on the entire nail bed – after nail plate and subungual hyperkeratosis removal – that was treated 3 h later with red light (570–670 nm) from a non-coherent light source (Waldmann PDT 1200, Waldmann-Medizin-Technik, Villingen-Schwenningen, Germany) at a light dose of 40 J/cm² and a fluence rate of 40 mW/cm². Prior to PDT, ALA-induced protoporphyrin IX fluorescence was confirmed each time by UV irradiation, using Woods light. A total of three treatments were performed at 2-weekly intervals. Only one toenail per subject was treated.

Pain during treatment was assessed by the patients using a 10-cm visual analogue scale (VAS) from 0 (no pain) to 10 (unbearable pain).

Clinical and mycological evaluations were performed by the same investigators 12 and 18 months after the last treatment. Criteria for cure were either 100% absence of clinical signs

of onychomycosis or subungual hyperkeratosis, leaving less than 10% of the nail plate affected combined with negative mycological laboratory results (negative direct microscopic examination). At the end of treatment and during the follow-up period no systemic treatment was allowed nor any additional topical treatment on the nails treated with PDT. However, topical treatment was allowed in patients with more than one affected toenail on the toenail not treated with PDT. This was to try to limit the risk of re-infection of the PDT-treated nail.

All patients gave written consent to participate after having received detailed information on the purpose and design of the study. The study was approved by the local ethics committee.

RESULTS

All 30 patients completed the study. Twenty-two patients (73.3%) had onychomycosis of the great toenail and 8 (26.6%) had onychomycosis of one toenail other than that of the great toe. Five of the 22 patients with great toenail involvement had involvement of an additional nail.

PDT reactions recorded during light treatment were a burning sensation and pain in all patients. Pain management included the use of a fan or of cooling sprays in patients who felt intense pain and discomfort. Despite these measures, treatment had to be interrupted for 5–10 min in 12, 8 and 10 patients during the first, second and third sessions, respectively. A clinical example before and after PDT is shown in Fig. 1.

The mean VAS score of PDT-associated pain was 6.8 for the first session, 6.4 for the second and 6.5 for the third session.

Local phototoxic reactions included moderate erythema (30/30), oedema (28/30) and blistering (14/30) of the nail bed. These reactions were well tolerated, did not demand additional treatment, and resolved within 7–15 days without further complications.

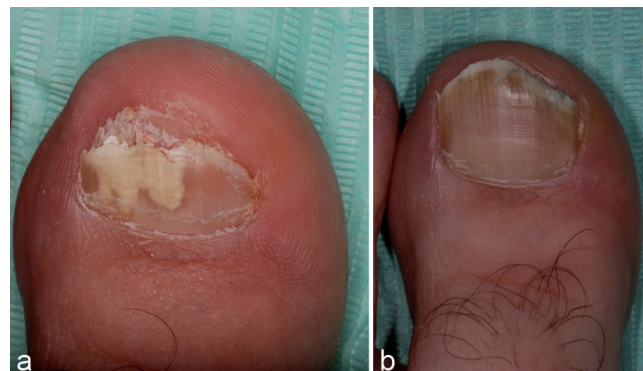


Fig. 1. (a) Patient 14 before treatment, and (b) 18 months after treatment.

After one year, 13 patients (43.3%) were cured, according to our criteria. Only 5 (16.6%) patients showed complete absence of clinical signs, while 8 (26.6%) patients showed residual changes affecting less than 10% of the nail plate and negative mycological laboratory results. The remaining patients had changes compatible with dermatophyte infection covering more than 10% of the nail plate, as well as positive direct microscopic examination.

At month 18, the cure rate dropped to 36.6%. Only 11 of the cured patients at the first follow-up visit had persistent clearance, while clinical and mycological recurrence was seen in 2 of the patients, with minor residual clinical changes and negative laboratory results at month 12.

The remaining patients had a persistent infection that deteriorated as no additional treatment was allowed during the follow-up period (Table I).

DISCUSSION

In our study, ALA-PDT provided a cure rate of 43.3% 12 months after treatment, which reduced to 36.6% 18 months after treatment. These results are not in agreement with previous literature reporting clinical and mycological cure in all patients treated with PDT. However, it is important to mention that different light sources, or different photosensitizing agents, as well as more therapeutic cycles, were used in those individuals (6, 7).

There are several possible explanations for the unsatisfactory outcome in our patients. *In vitro* studies demonstrated that formation of PpIX was restricted to selected parts of the fungal mycelium, leading to a significant but not higher than 50% growth inhibition of *T. rubrum*. Thus, according to the investigators, the growth of *T. rubrum* seems to be only time-delayed by PDT (2).

Smijs et al. (5) hypothesize that, although PDT inactivates both hyphae and spores, better fungicidal effect could be achieved by application of a second treatment within 24–48 h, a time interval in which hyphal tip morphology could not change into more resistant globular structures.

Another possible limiting factor could be the adequate ALA uptake under *in vivo* conditions. Conditions

such as temperature, humidity or pH of the biological environment could induce a poor uptake of ALA or a deficient biosynthesis of PpIX.

We believe that removal of the nail-plate and the nail-bed hyperkeratosis is necessary, as it is difficult to achieve sufficient ALA concentrations in the nail-plate, unless several modifications are made (8). In addition, it is possible that urea improves the effect of topical anti-fungal agents, possibly via structural disintegration of the corneocyte, thus enhancing the therapeutic potential of ALA-PDT. Moreover, urea and nail removal alone may have a significant role in halting fungal nail infection.

In conclusion, PDT of onychomycosis could be considered as an alternative therapeutic option in patients contra-indicated for systemic anti-fungal treatment. It is minimally invasive, and only locally active, with no damage to healthy tissues or systemic side-effects. Moreover, there are no reports of fungal resistance, and the lack of cumulative or mutagenic effects allows repeated treatments (9). On the other hand, the discomfort reported by the patients during illumination, as well as the subsequent local phototoxic reactions, although transient, do not allow wide use of the method.

The authors declare no conflict of interest.

REFERENCES

1. Calzavara-Pinton PG, Venturini M, Sala R. A comprehensive overview of photodynamic therapy in the treatment of superficial fungal infections of the skin. *J Photochem Photobiol* 2005; 78: 1–6.
2. Kamp H, Tietz HJ, Lutz M, Piazena H, Sowyrda P, Lademann J, et al. Antifungal effect of 5-aminolevulinic acid PDT in *Trichophyton rubrum*. *Mycoses* 2005; 48: 101–107.
3. Smijs TG, van der Haas RN, Lugtenburg J, Liu Y, de Jong RLP, Schuitmaker HJ. Photodynamic treatment of the dermatophyte *T. rubrum* and its microconidia with porphyrin photosensitizers. *Photochem Photobiol* 2004; 80: 197–202.
4. Smijs TGM, Bouwstra JA, Schuitmaker HJ, Talebi M, Pavel S. A novel ex vivo skin model to study the susceptibility of the dermatophyte *Trichophyton rubrum* to photodynamic therapy in different growth phases. *J Antimicrob Chemother* 2007; 59: 433–440.
5. Smijs TGM, Mulder AATA, Pavel S, Onderwater JJM, Koerten HK, Bouwstra JA. Morphological changes of the dermatophyte *Trichophyton rubrum* after photodynamic treatment: a scanning electron microscopy study. *Med Mycol* 2008; 46: 315–325.
6. Piraccini BM, Rech G, Tosti A. Photodynamic therapy of onychomycosis caused by *Trichophyton rubrum*. *J Am Acad Dermatol* 2008; 59: 75–76.
7. Watanabe D, Kawamura C, Masudo Y, Akita Y, Tamada Y, Matsumoto Y. Successful treatment of toenail onychomycosis with photodynamic therapy. *Arch Dermatol* 2008; 144: 19–21.
8. Donnelly RF, McCarron PA, Lightowler JM. Bioadhesive patch-based delivery of 5-aminolevulinic acid to the nail for photodynamic therapy of onychomycosis. *J Control Release* 2005; 103: 381–392.
9. Donnelly RF, McCarron PA, Tunney MM. Antifungal photodynamic therapy. *Microbiol Res* 2008; 163: 1–12.

Table I. Results of treatment

Parameter	Outcome	
Clinical evaluation	Clinical cure, <i>n</i> (%)	No clinical cure, <i>n</i> (%)
12 m	13 (43)	17 (57)
18 m	11 (37)	29 (63)
Mycological examination	Neg, <i>n</i> (%)	Pos, <i>n</i> (%)
12 m	13 (43)	17 (57)
18 m	11 (37)	29 (63)

Neg: negative direct microscopic examination; Pos: positive direct microscopic examination.