

Successful Treatment of Nail Lichen Planus with Topical Tacrolimus

Hideyuki Ujiie, Akihiko Shibaki, Masashi Akiyama and Hiroshi Shimizu

Department of Dermatology, Hokkaido University Graduate School of Medicine, North 15 West 7, Kita-ku, Sapporo 060-8638, Japan. E-mail: h-ujiie@med.hokudai.ac.jp

Accepted November 4, 2009.

Sir,

Nail lichen planus (NLP) is characterized by thinning, longitudinal ridging and distal splitting of the nail plate (1, 2). Although mild NLP is usually asymptomatic, deformation of the fingernails is cosmetically distressing. Failure to treat NLP results in nail loss or permanent nail dystrophy in some cases. Therefore the condition should be treated effectively in its early stage. NLP is usually resistant to topical corticosteroid therapy, but successful treatment has been reported with intralesional or systemic administration of corticosteroids (2–4). However, some patients are unable to tolerate the side-effects of systemic corticosteroids.

Topical tacrolimus has been reported as a safe, effective therapy for cutaneous (5, 6), oral (7–9) and vulvar lichen planus (LP) (9–11), even in patients whose lesions have shown recalcitrance to other treatments (7, 10). However, topical tacrolimus treatment for NLP has never been reported. We report here five cases of NLP treated successfully with tacrolimus ointment.

CASE REPORTS

Five Japanese patients with NLP were treated with 0.1% tacrolimus ointment. The mean age of the five patients (4 males and 1 female) was 40.2 years (age range 11–58 years). All of the patients were diagnosed with NLP on the basis of clinical history, typical clinical appearance and histopathological features. No patient had any symptoms suggesting lupus erythematosus or photosensitivity. There was no history of nail matrix trauma, or drug intake that could cause lichenoid drug eruption. All of these cases demonstrated multiple nail lesions on the fingers and/or toes. In one patient, the disease affected all 20 nails. All the fingernails were affected in three other patients, including two cases that presented with additional nail lesions on both big toes. The most common clinical signs were thinning of nails and onycholysis, which were observed in all of the patients. Longitudinal ridging and onychorrhexis were present in four cases. The NLP was not associated with any objective symptom, such as burning, itching or pain, in any of the cases. A 58-year-old patient had concomitant localized reticular oral LP, although no patient had cutaneous, otic or genital lesions at any time during the follow-up. An 11-year-old patient had mild atopic dermatitis; the four adult patients had no other dermatological conditions. The clinical diagnosis was confirmed by histopathological examination in all cases. Biopsy specimens taken from the affected nail matrix demonstrated band-like lymphocyte infiltration in the nail matrix and the nail bed dermis, as well as hyperkeratosis, acanthosis and hypergranulosis of the epidermis, which are histopathological features typically observed in NLP.

The mean duration of the disease prior to the topical tacrolimus treatment was 24 months (range 4–84 months). We followed up all the patients for at least 15 months (mean 39.0 months; range 15–71 months). Four of the patients had been treated with

topical corticosteroids, with no or slight improvement, before the tacrolimus therapy. In all the cases, 0.1% topical tacrolimus (Protopic ointment 0.1%, Astellas Pharma Inc., Tokyo, Japan) was administered twice a day on one side of the nail plates and periungual regions of the fingers and/or toes, and a topical corticosteroid (from the classification “very strong” or “strongest”) was simultaneously started on the other side for a comparison of relative efficacy. In all cases, the affected nails treated with topical tacrolimus began to improve within 6 months after the initiation of treatment (mean 2.8 months; range 1–6 months), whereas no obvious changes, or only slight improvement, were observed in the nails treated with topical corticosteroids, suggesting that tacrolimus ointment had higher therapeutic efficacy than topical corticosteroids (Fig. 1). All the lesions were then treated uniformly with topical tacrolimus. All of the patients showed marked improvement (Fig. 2). Mild onycholysis and splitting of the nails remained in some of the patients. Reticular oral LP observed in a 58-year-old patient remained after his NLP lesions had improved. Two patients who discontinued topical tacrolimus application showed no exacerbation of their lesions at 16 and 36 months of follow-up, respectively. Two other patients continue to use topical tacrolimus once or twice daily as a supportive treatment, which keeps their lesions stable. The remaining patient stopped visiting our clinic after remission. No adverse effects were noted in any of the cases.

DISCUSSION

Topical corticosteroid therapy is commonly considered as a first-line treatment for NLP, although it is usually ineffective. Oral prednisone and intramuscular triamcinolone acetonide have been reported as effective against NLP (2–4), but prolonged or repeated use of

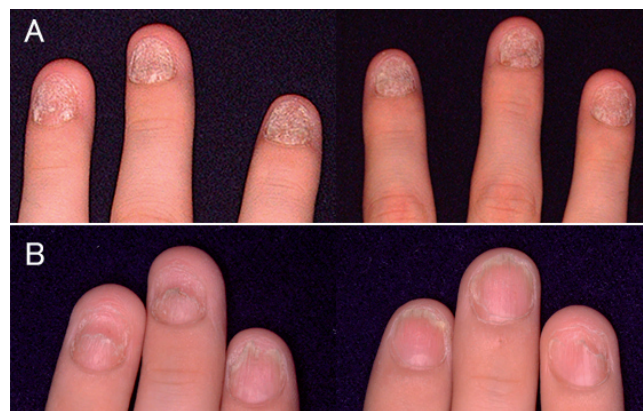

Fig. 1. (A) Nail lichen planus in an 11-year-old male patient before treatment. The fingernails show very severe thinning. The right-hand fingernails were treated with topical tacrolimus and the left-hand ones with diflucortolone valerate ointment twice daily (comparative application). (B) The same patient after 5 months of comparative application. Significant clinical improvement of the right-hand fingernails (right) was noted compared with the left-hand ones (left).

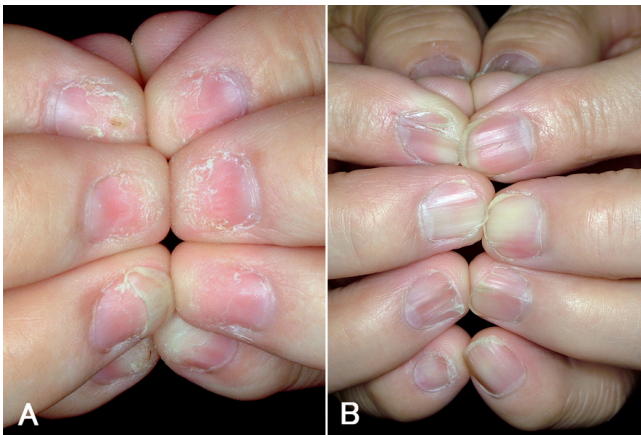


Fig. 2. (A) Nail lichen planus in a 58-year-old male patient. The fingernails show severe distal thinning and onycholysis before treatment. (B) Significant improvement after 18 months of topical tacrolimus treatment.

systemic corticosteroids may cause considerable side-effects.

Tacrolimus is a macrolide immune modulator that produces strong immunosuppression by inhibiting T-cell activation. It interacts with a cyclophilin-like cytoplasmic protein, FK506 binding protein, and this complex interferes with the phosphatase activity of calcineurin, resulting in the inhibition of proinflammatory cytokine genes transcription. Because activated T cells are likely to play a central role in the pathogenesis of LP (1, 12, 13), topical tacrolimus has been tried for the treatment of LP. Previous studies have reported that topical tacrolimus is effective for 88–100% of cases of oral LP (7–9) and 94% of cases of vulvar LP (10). Based on these data, we speculated that topical tacrolimus could also be effective against NLP. In this study, all five cases with NLP responded fairly well to topical tacrolimus, even though 4 had intractable lesions that had shown resistance to topical corticosteroids. Comparative study of the efficacy of topical tacrolimus and topical corticosteroids revealed that topical tacrolimus was more effective than topical corticosteroids in all of the cases.

Recent studies demonstrated that nail dystrophy associated with chronic paronychia (14) and eczema (15) improved with topical tacrolimus, which suggests that topical tacrolimus could penetrate the periungual skin enough to improve the nail dystrophy. In addition, the remarkable thinning of the nails and onychorrhexis seen in most of our NLP cases make it possible that the tacrolimus ointment penetrated the damaged nail plates.

The majority of oral LP and vulvar LP cases respond to topical tacrolimus within one month (7–11), whereas the present NLP patients required several months to start to regress (mean 2.8 months).

At present, two out of the five patients have been continuing once- or twice-daily application for 35 and 63 months, respectively, to keep their lesions under con-

trol. Two other patients have been stable without topical tacrolimus for more than one year. However, we should be aware of the possibility that NLP can recur, because previous reports have mentioned that oral or vulvar LP lesions usually returned after withdrawal of topical tacrolimus (7, 10). Further analysis with longer follow-up is required to confirm the long-term prognosis of NLP after the cessation of topical tacrolimus therapy.

The authors declare no conflict of interest.

REFERENCES

1. Boyd AS, Neldner KH. Lichen planus. *J Am Acad Dermatol* 1991; 25: 593–619.
2. Tosti A, Peluso AM, Fanti PA, Piraccini BM. Nail lichen planus: clinical and pathologic study of twenty-four patients. *J Am Acad Dermatol* 1993; 28: 724–730.
3. Evans AV, Roest MA, Fletcher CL, Lister R, Hay RJ. Isolated lichen planus of the toe nails treated with oral prednisolone. *Clin Exp Dermatol* 2001; 26: 412–414.
4. Tosti A, Piraccini BM, Cambiaghi S, Jorizzo M. Nail lichen planus in children: clinical features, response to treatment, and long-term follow-up. *Arch Dermatol* 2001; 137: 1027–1032.
5. Al-Khenaizan S, Al Mubarak L. Ulcerative lichen planus of the sole: excellent response to topical tacrolimus. *Int J Dermatol* 2008; 47: 626–628.
6. Fortina AB, Giullioni E, Tonin E. Topical tacrolimus in the treatment of lichen planus in a child. *Pediatr Dermatol* 2008; 25: 570–571.
7. Byrd JA, Davis MD, Bruce AJ, Drage LA, Rogers RS, 3rd. Response of oral lichen planus to topical tacrolimus in 37 patients. *Arch Dermatol* 2004; 140: 1508–1512.
8. Olivier V, Lacour JP, Mousnier A, Garraffo R, Monteil RA, Ortonne JP. Treatment of chronic erosive oral lichen planus with low concentrations of topical tacrolimus: an open prospective study. *Arch Dermatol* 2002; 138: 1335–1338.
9. Vente C, Reich K, Rupprecht R, Neumann C. Erosive mucosal lichen planus: response to topical treatment with tacrolimus. *Br J Dermatol* 1999; 140: 338–342.
10. Byrd JA, Davis MD, Rogers RS, 3rd. Recalcitrant symptomatic vulvar lichen planus: response to topical tacrolimus. *Arch Dermatol* 2004; 140: 715–720.
11. Kirtschig G, Van Der Meulen AJ, Ion Lipan JW, Stoof TJ. Successful treatment of erosive vulvovaginal lichen planus with topical tacrolimus. *Br J Dermatol* 2002; 147: 625–626.
12. Shiohara T, Moriya N, Nagashima M. The lichenoid tissue reaction. A new concept of pathogenesis. *Int J Dermatol* 1988; 27: 365–374.
13. Shiohara T, Nickoloff BJ, Moriya N, Gotoh C, Nagashima M. In vivo effects of interferon-gamma and anti-interferon-gamma antibody on the experimentally induced lichenoid tissue reaction. *Br J Dermatol* 1988; 119: 199–206.
14. Rigopoulos D, Gregoriou S, Belyayeva E, Larios G, Kontochristopoulos G, Katsambas A. Efficacy and safety of tacrolimus ointment 0.1% vs. betamethasone 17-valerate 0.1% in the treatment of chronic paronychia: an unblinded randomized study. *Br J Dermatol* 2009; 160: 858–860.
15. Lee DY, Kim WS, Lee KJ, Kim JA, Park JH, Cho HJ, et al. Tacrolimus ointment in onychodystrophy associated with eczema. *J Eur Acad Dermatol Venereol* 2007; 21: 1137–1138.