

Non-pigmenting Fixed Drug Eruption Induced by Sorafenib

Kenichi Tanabe¹, Yasuyuki Amoh¹, Sumiyuki Mii¹, Hiromitsu Eto¹, Masatsugu Iwamura² and Kensei Katsuoka¹

¹Departments of Dermatology and ²Urology, Kitasato University School of Medicine, 1-15-1 Kitasato, Sagami-hara, Kanagawa 228-8555, Japan. E-mail: kenichi0922t@yahoo.co.jp

Accepted December 3, 2009.

Sorafenib (Nexavar[®], Bayer, Osaka, Japan) is an oral multi-kinase inhibitor with effects on tumour cell proliferation and tumour angiogenesis. Hand-foot skin reactions caused by sorafenib have been reported. We present here a case of an elderly patient with renal cell carcinoma who developed fixed drug eruption due to sorafenib.

CASE REPORT

On 17 July 2008, a 70-year-old Japanese man was started on sorafenib treatment for stage IV renal cell carcinoma. Six hours after the first dose he noticed erythema on his knee and forearm. The following day the patient was referred to us for consultation. Examination revealed two slightly tender erythematous lesions approximately 10 cm in diameter on his left knee and right distal forearm regions. After discontinuing sorafenib the erythema disappeared. Five days later, following re-administration of one dose of sorafenib, the erythema reappeared in the same locations. The lesions were scarlet-coloured and oedematous with a distinct border (Fig. 1). A biopsy from his forearm showed mild hyperkeratosis and lymphocyte migration into the epidermis. A diffuse lymphocytic infiltration was detected in the upper dermis. There was no pigment incontinence (Fig. 2). Two days after cessation of sorafenib, the erythema improved without residual pigmentation. The patient died from renal cell carcinoma before a patch test could be performed.

DISCUSSION

Sorafenib is unique in targeting the Raf/Mek/Erk pathway (1). In a phase II placebo-controlled randomized discontinuation trial of sorafenib in patients with metastatic renal cell cancer, dermatological adverse

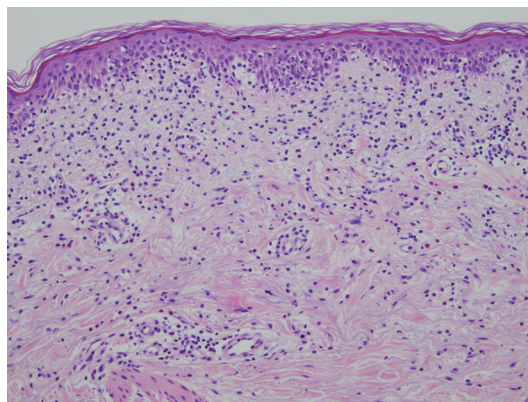


Fig. 2. Histological examination showed mild hyperkeratosis and lymphocyte migration into the epidermis. A diffuse lymphocytic infiltration was observed in the upper dermis. $\times 100$.

effects, including hand-foot skin reactions, alopecia, stomatitis, facial and scalp erythema, and subungual splinter haemorrhages, were reported in more than 90% of patients, with hand-foot skin reaction among the more frequent adverse reactions (2).

In 1937, Abramowitz & Noun (3) reviewed fixed drug eruptions. They noted that the term “fixed” refers neither to the duration of the lesion nor to the residual pigmentation at the site, but only to the recurrence of the eruption in a previously affected area of skin. Shelley & Shelley in 1987 (4), described a non-pigmenting variant of fixed drug eruptions that consisted of symmetrical, tender, large, erythematous plaques. We diagnosed the present case as non-pigmenting fixed drug eruption because the erythema appeared in the same area shortly after drug re-administration and improved without residual pigmentation.

The authors declare no conflict of interest.

REFERENCES

1. Wilhelm S, Chien CD. Bay 43-9006: preclinical data. *Curr Pharm Des* 2002; 8: 2255–2257.
2. Ratain MJ, Eisen T, Stadler WM, Flaherty KT, Kaye SB, Rosner GL, et al. Phase II placebo-controlled randomized discontinuation trial of sorafenib in patients with metastatic renal cell carcinoma. *J Clin Oncol* 2006; 24: 2505–2512.
3. Abramowitz EW, Noun MH. Fixed drug eruptions. *Arch Dermatol Syphil* 1937; 35: 875–892.
4. Shelley WB, Shelley ED. Nonpigmenting fix drug eruption as a distinctive reaction pattern: examples caused by sensitivity to pseudoephedrine hydrochloride and tetrahydrozoline. *J Am Acad Dermatol* 1987; 17: 403–407.

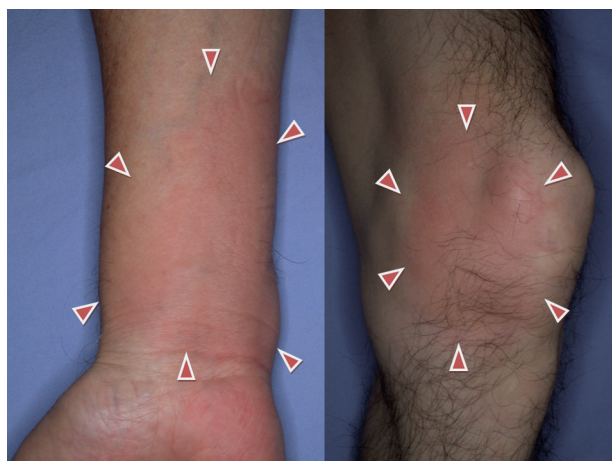

Fig. 1. Scarlet-coloured, oedematous lesions approximately 10 cm in diameter with a distinct border were observed on the patient's right distal forearm and left knee.