

Primary Localized Cutaneous Amyloidosis in Patients with Scleroderma

Nobuyuki Kikuchi, Erika Sakai, Akiko Nishibu, Mikio Ohtsuka and Toshiyuki Yamamoto

Department of Dermatology, Fukushima Medical University, Fukushima 960-1295, Japan. E-mail: nobuyuk@fmu.ac.jp

Accepted February 4, 2010.

Primary localized cutaneous amyloidosis (PLCA) is a relatively rare condition characterized by amyloid deposition exclusively in the dermis without involving the internal organs. Clinically, papular, macular and tumefactive forms are presented. Although PLCA may sometimes overlap with collagen vascular diseases, association with scleroderma is rare. We report here two cases of PLCA developing in patients with scleroderma.

CASE REPORTS

Case 1. A 70-year-old Japanese woman was referred to our department with swollen fingers on both hands. One year previously she had noticed pale, chilly and oedematous fingers and Raynaud's phenomenon. Physical examination revealed oedematous fingers (Fig. 1a), while skin sclerosis was not noted on either the dorsa of the hands or the forearms. Telangiectasia was found on her cheeks. Detailed physical examination revealed dotted pigmented papules on the upper back (Fig. 1b). Laboratory examination was positive for anti-nuclear antibody (1:2560, centromere pattern), but negative for antibodies against scleroderma-70 (Scl-70), ribonucleoprotein (RNP), SS-A and Jo-1. Skin biopsies were taken from the left middle finger, left lateral forearm and back. Histological features of specimens from the finger showed dermal sclerosis with thickened and homogenous collagen bundles in the mid-to-lower dermis (Fig. 1c), and those from the forearm showed a mild sclerosis with oedematous stage. Histological features of the specimen from the back showed amorphous deposits in the papillary dermis. Congo-red and Dylon staining showed positive findings in the papillary dermis (Fig. 1d).

Case 2. A 62-year-old man was referred to our department with skin stiffness and pigmentation of both forearms. He stated that hyperpigmentation with itching had occurred one year previously, and that skin sclerosis had been present for more than 6 months. He was a builder and had been engaged in construction work, tiling roofs, and had used organic solvents containing silicon adhesives. Physical examination revealed that his fingers were pale and oedematous (Fig. 2a), and severe sclerosis with hyperpigmentation was observed on his forearms, the dorsa of his hands, and his fingers. Neither large nor small pinching was possible. Furthermore, multiple hyperkeratotic whitish papules were localized on the lateral aspects of both forearms (Fig. 2b). Erythema and pigmentation was also seen on his abdomen and back, but without skin sclerosis. Laboratory examination for anti-nuclear antibody was positive (1:160, homogeneous and speckled), and anti-double-strand DNA antibody was 40.8 IU/ml (normal <10 IU/ml). Results for antibodies against RNP, Scl-70, SS-A, and SS-B were all negative. Respiratory examination showed slight ventilation disorder, and computed tomography (CT) showed slight fibrosis in the lower lungs. Echocardiography revealed left ventricular hypertrophy and aortic regurgitation. Skin biopsy from the left lateral forearm revealed irregular hyperkeratosis in the epidermis and dermal sclerosis with thickened and homogeneous collagen bundles in the thickened dermis. Congo-red and Dylon staining revealed amyloid deposition in the papillary and upper dermis (Fig. 2c).

DISCUSSION

Until now, only a few cases of PLCA associated with scleroderma have been reported mainly from Japan

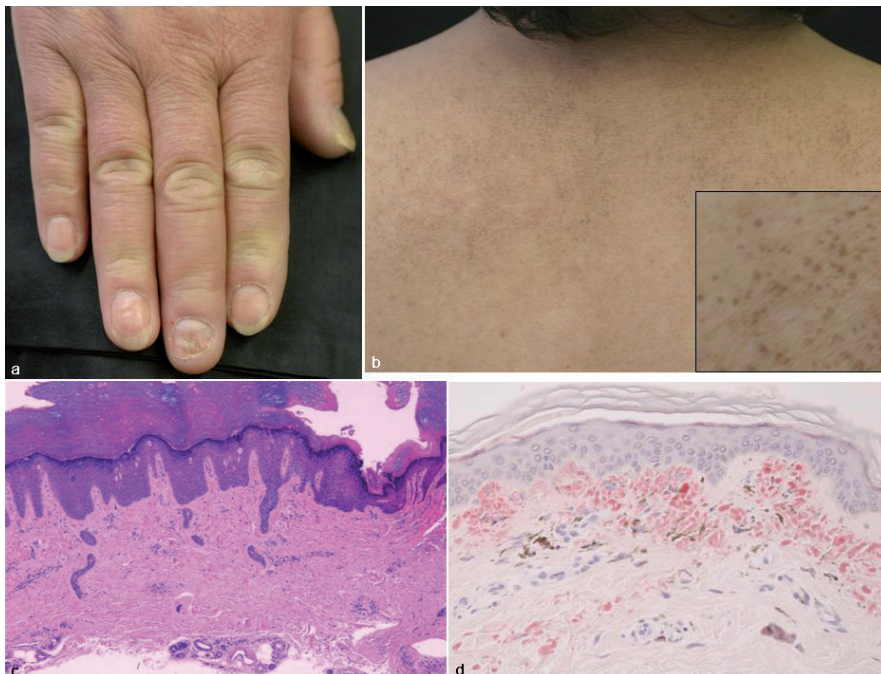


Fig. 1. (a) Swollen fingers in Case 1. (b) Spotted brownish papules on the upper back. Insert: higher magnification. (c) Histological features showing dermal sclerosis. (d) Amyloid deposition in the papillary dermis (Dylon) ($\times 100$).

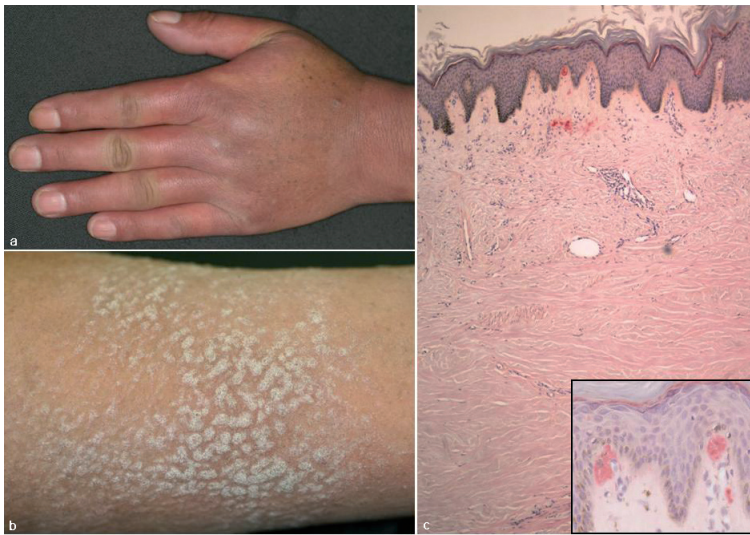

Fig. 2. (a) Raynaud's phenomenon in Case 2. (b) Multiple keratotic papules on the sclerotic forearms. (c) Histological features of irregular hyperkeratosis and amyloid deposition in the stratum papillary layers of the epidermis (*insert*) and the upper dermis of the overlying sclerotic dermis (Dylon) ($\times 40$).

(1–6). Ogiyama et al. (5) reported 6 cases of cutaneous amyloidosis with scleroderma, 4 females and 2 males, and the involved sites were the upper back in all cases. Looi (2) reviewed 85 patients with PLCA, and revealed one scleroderma patient with papular amyloidosis. Summers & Kendrick (6) reported an unusual case that showed multiple nodular amyloidosis in a patient with CREST syndrome (calcinosis, Raynaud's phenomenon, esophageal dysmotility, sclerodactyly, and telangiectasia). Moreover, cases of sclerodermatomyositis (7) and generalized morphea-like scleroderma (8) exhibiting coexistence of PLCA have been reported.

Systemic amyloidosis was excluded by detailed investigation in both of our cases. Case 1 had limited-type scleroderma, and PLCA occurred on the upper back where no dermal sclerosis was found. Amyloid deposits may be derived from degenerated epithelial keratinocytes (9), possibly through filamentous degeneration or apoptosis (10). The patient had no features of cutaneous amyloidosis other than on the back, and she denied rubbing the upper back with a nylon towel when taking baths. By contrast, there was lichen amyloidosis on the extensor aspects of the bilateral sclerotic forearms in Case 2. The patient reported itching on the forearms and frequent scratching. Indeed, the keratotic papules on the forearms were flattened significantly by simple wrapping with wide adhesive.

It is noteworthy that Case 1 presented a unique clinical appearance of PLCA on the upper back. Lesions were pigmented discrete spotty papules and did not present as hyperkeratotic papules like those of lichen amyloidosis. Although these unusual clinical features did not assume

macular lesions with a rippled pattern, Case 1 was thought to be macular amyloidosis.

Case 2 was thought to be generalized morphea-like scleroderma, a condition first described by Yamakage & Ishikawa (11). Such patients quite often have a history of exposure to organic solvents. However, very few cases have been reported in the English literature since the original report (8, 12). Case 2 had a long-term history of close contact with organic solvents, including silicon-based compounds, and showed rapid progression, severe skin sclerosis with diffuse hyperpigmentation, and internal organ involvements (lungs and heart). It is possible that such manifestations exist mainly in Japan, but a further accumulation of similar cases is needed to study this in more detail.

The authors declare no conflict of interest.

REFERENCES

- Black MM. Widespread atypical lichen amyloidosis, primary biliary cirrhosis and scleroderma. *Br J Dermatol* 1974; 89: 42–45.
- Looi LM. Primary localized cutaneous amyloidosis in Malaysians. *Australas J Dermatol* 1991; 32: 39–44.
- Chanoki M, Suzuki S, Hayashi Y, Ishii M, Hamada T. Progressive systemic sclerosis associated with cutaneous amyloidosis. *Int J Dermatol* 1994; 33: 648–649.
- Azon-Masoliver A. Widespread primary localized cutaneous amyloidosis (macular form) associated with systemic sclerosis. *Br J Dermatol* 1995; 132: 163–165.
- Ogiyama Y, Hayashi Y, Kou C, Matsumoto Y, Ohashi M. Cutaneous amyloidosis in patients with progressive systemic sclerosis. *Cutis* 1996; 57: 28–32.
- Summers EM, Kendrick CG. Primary localized cutaneous nodular amyloidosis and CREST syndrome: a case report and review of the literature. *Cutis* 2008; 82: 55–59.
- Orihara T, Yanase S, Furuya T. A case of sclerodermatomyositis with cutaneous amyloidosis. *Br J Dermatol* 1985; 112: 213–219.
- Sumi K, Yamamoto T, Yokozeki H, Nishioka K. Amyloid deposition associated with generalized morphea-like scleroderma. *Eur J Dermatol* 2003; 13: 509–511.
- Chang YT, Liu HN, Wang WJ, Lee DD, Tsai SF. A study of cytokeratin profiles in localized cutaneous amyloids. *Arch Dermatol Res* 2004; 296: 83–88.
- Maeda H, Ohta S, Saito Y, Nameki H, Ishikawa H. Epidermal origin of the amyloid in localized cutaneous amyloidosis. *Br J Dermatol* 1982; 106: 345–351.
- Yamakage A, Ishikawa H. Generalized morphea-like scleroderma in people exposed to organic solvents. *Dermatology* 1982; 165: 186–193.
- Nagai Y, Igarashi N, Ishikawa O. Generalized morphea-like systemic sclerosis: a subtype of diffuse cutaneous systemic sclerosis presenting with unusual cutaneous features. *Eur J Dermatol* 2008; 18: 715–716.