

## Dermochondrocorneal Dystrophy (Francois' Syndrome)

Jane Baumgartner-Nielsen<sup>1</sup>, Jesper Hjortdal<sup>2</sup> and Karsten Fogh<sup>1\*</sup>

Departments of <sup>1</sup>Dermatology and <sup>2</sup>Ophthalmology, Aarhus University Hospital, DK-8000 Aarhus C, Denmark. \*E-mail: karsfogh@rm.dk  
Accepted December 7, 2009.

Sir,

Dermochondrocorneal dystrophy (of Francois) is a rare inherited disease. The mode of inheritance is uncertain and both autosomal recessive and dominant traits have been suggested (1). The disease is characterized by corneal dystrophy, and xanthomatous nodules of the hands, elbows and nose, together with deformity of the hands and feet. In addition, ocular changes are present, leading to reduced vision. The disease was initially described in 1949 by Francois (2). The histopathology of the disease is described as a proliferation of fibroblasts, and analysis of metabolites from urinary collagen has suggested increased production of type III collagen (3, 4). Only a few cases have been reported in the literature (5–7). We report here the case of a man presenting with classical skin changes.

### CASE REPORT

A 59-year-old man was referred to the department of dermatology from the general practitioner for laser therapy of cutaneous chondromes. Since early childhood he had had firm xanthomatous nodules in the skin, located in the nasal area and upper extremities (Fig. 1a). From time to time these nodules had been removed surgically. His hands and feet were enlarged compared with his arms and legs (Fig. 1b). In addition to the skin symptoms there had been a gradual reduction in vision due to attempts to treat corneal opacities. The corneal opacities, originally presenting as a progressive vascularized pannus, were treated by repeated corneal grafts in the mid-1960s. The surgeries were later complicated with retinal detachment, cataract formation, glaucoma, and chronic uveitis. The right eye was enucleated in

the 1970s. Vision in the remaining left eye was markedly reduced (1/60). The patient's parents were first cousins, but there was no positive family history of similar symptoms.

### Histology

Biopsy specimen from a cutaneous nodule on the upper lip presented a well-defined nodular lesion with chondrocytes in an eosinophilic matrix (Fig. 2). There was a negative proliferation-marker (anti human ki-67 antigen, clone MIB-1) and no suspicion of malignancy.

### Treatment

At the department of dermatology the patient was treated with CO<sub>2</sub> laser therapy under local anaesthesia for cosmetic reasons. The treatment was successful, with a marked reduction in cutaneous chondromes. At the department of ophthalmology, the patient has been followed regularly since 1985. The corneal transplant on the remaining left eye is covered with a fine fibrovascular pannus of conjunctival epithelium. Normal corneal epithelium is not present.

### DISCUSSION

We demonstrate here a rare case in the field of inherited dermatological diseases. Our patient presented with classical skin changes, but had already been diagnosed with dermo-chondro-corneal dystrophy at the department of ophthalmology at the age of 7 years (6). There may be an underestimation of cases due to the fact that the corneal opacities and the blurred and reduced

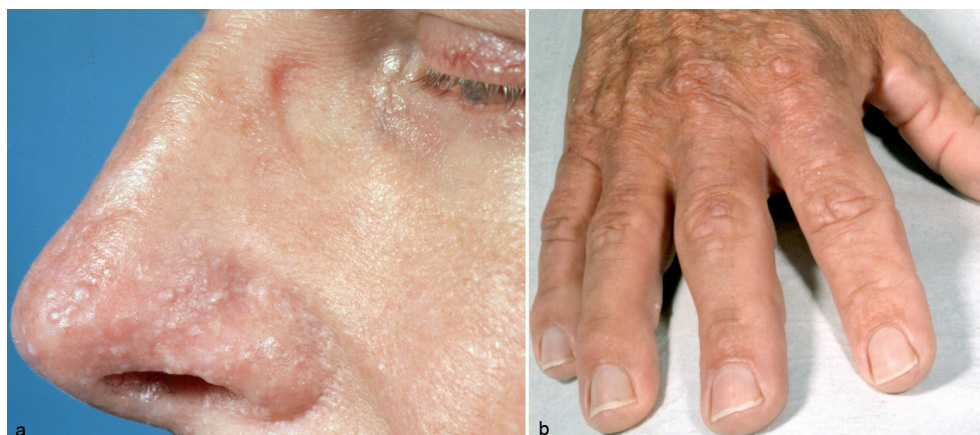


Fig. 1. (a) Typical skin changes of the nose (papular lesions consistent with chondromes). (b) Chondromes of the fingers.

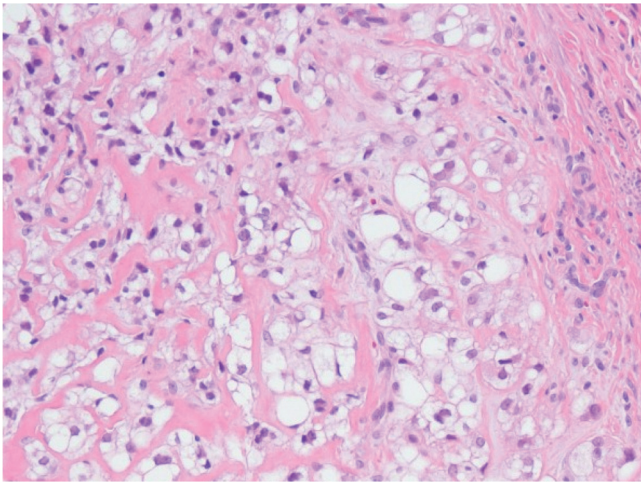


Fig. 2. Skin biopsy specimen from a typical chondrome of the upper lip (haematoxylin and eosin  $\times 400$ ).

vision have a greater impact on quality of life than the cutaneous chondromes and the skeletal deformities. However, our patient was not adversely affected by the skin changes except cosmetically. He was treated with CO<sub>2</sub> laser therapy with a good cosmetic result.

#### ACKNOWLEDGEMENT

The authors wish to thank Mette Ramsing, MD, Department of Pathology, Aarhus University Hospital, for providing the photomicrograph.

#### REFERENCES

1. Strachan IM. Cloudy central corneal dystrophy of Francois. Five cases in the same family. *Br J Ophthalmol* 1969; 53: 192–194.
2. Francois J. Dystrophie dermo-chondro-cornéenne familiale. *Ann Oculist* 1949; 182: 409–441.
3. Caputo R, Sambvani N, Monti M, Cavicchini S, Carrassi A, Ratiglia R. Dermochoncro-corneal dystrophy. (Francois' syndrome). Report of a case. *Arch Dermatol* 1988; 124: 424–428.
4. Caputo R, Cavicchini S, Monti M. Francois syndrome – an ultrastructural study. *Clin Exp Dermatol* 1987; 12: 233.
5. Bierly JR, George SP, Volpicelli M. Dermochondral corneal dystrophy (of Francois). *Br J Ophthalmol* 1992; 76: 760–761.
6. Jensen VJ. Dermo-chondro-corneal dystrophy. *Acta Ophthalmol* 1957; 36: 71–78.
7. Sardella A, Carrassi A, Caputo R, Monti M, Gotte P. Gingival lesions in a patient with dermocondrocorneal dystrophy (Francois syndrome). A case report. *J Clin Periodontol*, 1998; 25: 1047–1049.