

## Solitary Glomus Tumour on the Nostril of a Child: Unusual Clinical Presentation

Yosuke Ishitsuka<sup>1</sup>, Kuniaki Ohara<sup>2</sup> and Fujio Otsuka<sup>1</sup>

Department of Dermatology, <sup>1</sup>Graduate School of Comprehensive Human Sciences, University of Tsukuba, 1-1-1 Ten-nodai, Tsukuba, Ibaraki 305-0006, and <sup>2</sup>Toranomn Hospital, Toranomon, Minato-ku, Tokyo, Japan. E-mail: c0930412@md.tsukuba.ac.jp  
Accepted March 25, 2010.

Glomus tumours are relatively rare neoplasms of the normal glomus body, occurring as painful subcutaneous nodules, frequently located in the subungual area of the digits of adults (1, 2). Such distinctive clinical features often allow diagnosis to be made. We report here a case of glomus tumour that presented as a painless nodule on the nostril of a female child.

### CASE REPORT

A 5-year-old Japanese girl presented with a nodule on her left nostril. The nodule had developed 8 months previously and had been diagnosed as molluscum contagiosum by her local dermatologist. Although she underwent several sessions of cryotherapy, the nodule persisted.

The nodule was 3.5 mm in diameter, flat-topped, slightly red-coloured, with no symptoms such as pain, tenderness, or hypersensitivity to cold (Fig. 1). Although a whitish surface and telangiectasia was seen by dermatoscopy, it did not lead to a diagnosis. Clinically, the initial diagnoses were follicular tumours, such as trichoepithelioma or some other adnexal tumours.

The nodule was excised for diagnosis and treatment. Histopathological examination revealed an intra-dermal tumour without contiguity to the epidermis, with multiple nests of round-to-oval epithelioid cells and stromal myxoid change (Fig. 2). The epithelioid cells had pale eosinophilic cytoplasm and central nuclei without atypia, and partially showed perivascular distribution. Immunostaining revealed strong positivity for vimentin, weak positivity for muscle actin and alpha smooth muscle actin (Fig. 3), and negativity for desmin, S-100, and AE1/AE 3. Based on these findings, a diagnosis of solid glomus tumour was made.

There was no evidence of recurrence after 18 months.

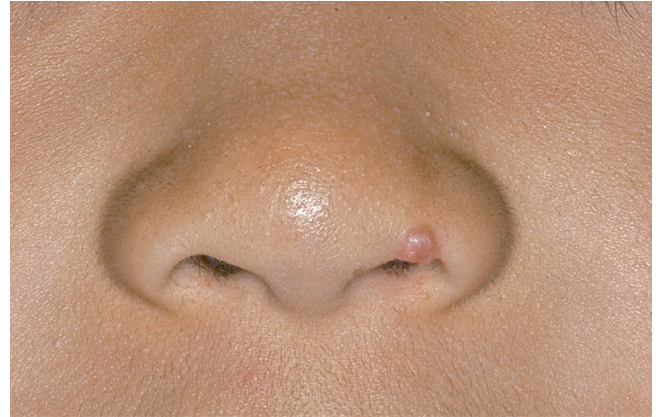

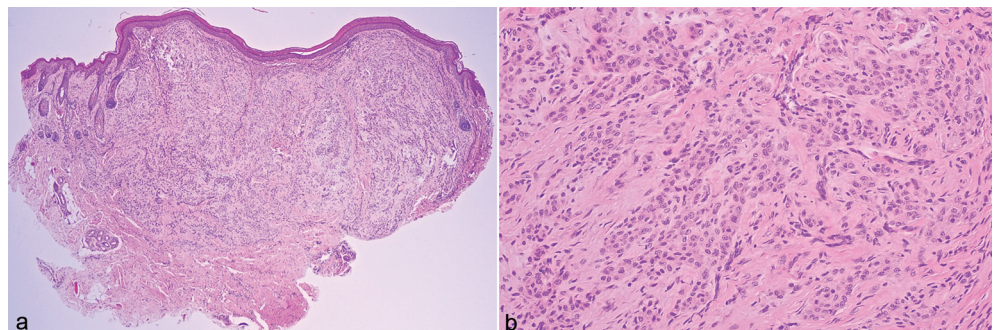
Fig. 1. A 3.5-mm diameter, flat-topped, slightly red-coloured, painless nodule on the left nostril.

### DISCUSSION

Glomus tumours are relatively rare neoplasms of the normal glomus body, occurring as subcutaneous nodules, most frequently in the extremities, and especially in the subungual area of the digits. Classically, they often present with a triad of symptoms: pain, localized tenderness with blunt palpation, and hypersensitivity to cold (1, 2). These distinctive features often allow diagnosis of the tumour.

In the present case, however, the tumour occurred on the nostril of a child as a solitary nodule, and was not accompanied by any classical symptoms. In a study of 56 patients with single extra-digital glomus tumours (3), most tumours (91%) arose on the extremities, and only one (1.8%) was on the nose. As for the symptoms, 48 patients (86%) presented with pain and localized tenderness. In contrast, the number of patients who reported no symptoms was 6 (11%). Moreover, most glomus tumours are solitary (4) and diagnosed during

Fig. 2. Histopathological features seen with haematoxylin and eosin (H&E) staining. (a) Well-circumscribed, intra-dermal tumour without contiguity to the epidermis. The tumour comprises small round cells and stromal myxoid change. (b) Round-to-oval epithelioid cells that have pale eosinophilic cytoplasm and central nuclei without atypia form the small nests ( $\times 100$ ).



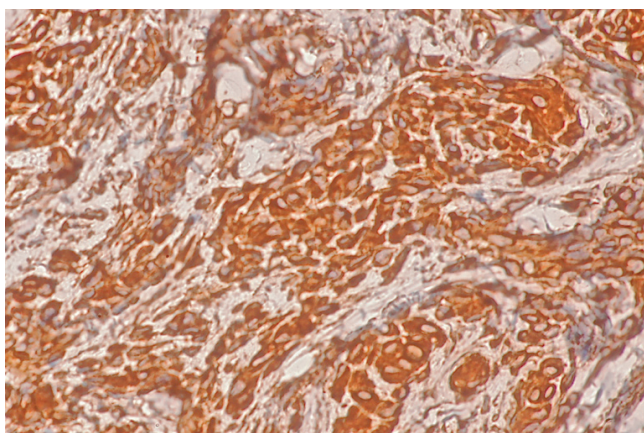


Fig. 3. Histopathological features of immunostaining. The tumour cells show strong cytoplasmic positivity for vimentin.

adult life (3, 5, 6); reported cases occurring in childhood are generally presented in multiple forms that are congenital and hereditary (7–9). Therefore, our patient showed unusual clinical features.

Histopathologically, one of the differential diagnoses based on haematoxylin and eosin (H&E) staining was mixed tumour of the skin, because of the epithelioid features of the tumour cells and the stromal myxoid change. Finally, myoid differentiation, proven by immunostaining, led to the definitive diagnosis (10).

In conclusion, we reported here a case of extra-digital solitary glomus tumour with uncommon clinical fea-

tures that deviated from the typical ones. Such a case poses a diagnostic challenge.

## REFERENCES

1. Van Geertruyden J, Lorea P, Goldschmidt D, de Fontaine S, Schuind F, Kinnen L, et al. Glomus tumours of the hand: a retrospective study of 51 cases. *J Hand Surg* 1996; 21: 257–260.
2. Masson P. Le glomus neuroarteriel des régions tactiles et ses tumeurs. *Lyon Chir* 1924; 21: 257–280.
3. Schiefer TK, Parker WL, Anakwenze OA, Amadio PC, Inwards CY, Spinner RJ. Extradigital glomus tumors: a 20-year experience. *Mayo Clin Proc* 2006; 81: 1337–1344.
4. Anakwenze OA, Parker WL, Schiefer TK, Inwards CY, Spinner RJ, Amadio PC. Clinical features of multiple glomus tumors. *Dermatol Surg* 2008; 34: 884–890.
5. Maxwell GP, Curtis RM, Wilgis EF. Multiple digital glomus tumors. *J Hand Surg* 1979; 4: 363–367.
6. Weiss SW, Goldblum JR. *Enzinger and Weiss's soft tissue tumors*. St Louis; Mosby: 2001: 985–1001.
7. Anakwenze OA, Parker WL, Schiefer TK, Inwards CY, Spinner RJ, Amadio PC. Clinical features of multiple glomus tumors. *Dermatol Surg* 2008; 34: 884–890.
8. Pepper MC, Laubenheimer R, Cripps DJ. Multiple glomus tumors. *J Cutan Pathol* 1977; 4: 244–257.
9. Wood WS, Dimmick JE. Multiple infiltrating glomus tumors in children. *Cancer* 1977; 40: 1680–1685.
10. Porter PL, Bigler SA, McNutt M, Gown AM. The immunophenotype of hemangiopericytomas and glomus tumors, with special reference to muscle protein expression: an immunohistochemical study and review of the literature. *Mod Pathol* 1991; 4: 46–52.