

## A Case of Primary Idiopathic Cutaneous Pustular Vasculitis

Yoshihide Asano<sup>1,2</sup>, Kenzo Kaji<sup>1,3</sup>, Takeo Idezuki<sup>1</sup> and Atsuyuki Igarashi<sup>1</sup>

Department of Dermatology, <sup>1</sup>Kanto Medical Center NTT EC, Shinagawa-ku, <sup>2</sup>Faculty of Medicine, University of Tokyo, 7-3-1 Hongo, Bunkyo-ku, Tokyo 113-8655 and <sup>3</sup>Kanazawa University Graduate School of Medical Science, Kanazawa, Ishikawa, Japan. E-mail: yasano-ty@umin.ac.jp  
Accepted January 21, 2009.

Primary idiopathic cutaneous pustular vasculitis (PICPV) is a rare clinical entity, which was first reported by McNeely et al. in 1986 (1). The disease is characterized by tender, purpuric pustules that recur several times over a period of 3–4 months, histological findings of Sweet's-like vasculitis, the presence of circulating immune complexes, deposit of immune complex in blood vessels, and the absence of other diseases associated with pustular lesions. We report here a second case with clinical manifestations compatible with this disease.

### CASE REPORT

A 31-year-old Japanese man presented at our hospital with asymptomatic pustules on his trunk and extremities. He had developed several asymptomatic pustules on the abdomen 10 years previously, which had disappeared spontaneously within 2 weeks. The eruptions recurred periodically every 3 or 4 months. In each episode the lesions persisted for approximately 10–14 days and resolved without scarring. He had no accompanying symptoms of fever, arthritis, arthralgia, myalgia, other cutaneous or mucosal lesions, pharyngitis, diarrhoea, or other abdominal symptoms. The extension of the rash gradually increased with the duration of the disease.

He had had no prior illnesses, surgery, medication, or hospitalizations that would explain the condition. On physical examination the patient appeared to be healthy, except for multiple cutaneous lesions distributed on the trunk, thighs and upper arms. The lesions were 2–5 mm in size, each with a faint erythematous base and pustular centre (Fig. 1). The lymph nodes were not palpable, and there were no other abnormal findings on physical examination. Routine haematological and biochemical investigations revealed no abnormalities. The erythrocyte sedimentation rate (ESR) was 4 mm/h. On serological examination, C3d-containing circulating immune complexes were found to be increased, while C1q-containing immune complex and anti-streptolysin-O (ASO) were within normal limits. Antinuclear antibodies were negative. Chest roentgenogram and urinalysis were normal. Throat and rectal swabs were negative for streptococcus and neisserial species. Skin biopsy was obtained from a faint erythema, which appeared to be in its early stage (Fig. 2). Histological examination showed no abnormalities in the epidermis. However, from the papillary dermis to the reticular dermis small dermal blood vessels were infiltrated by neutrophils accompanied by occasional lymphocytes. There was minimal leukocytoclasia without fibrinoid degeneration

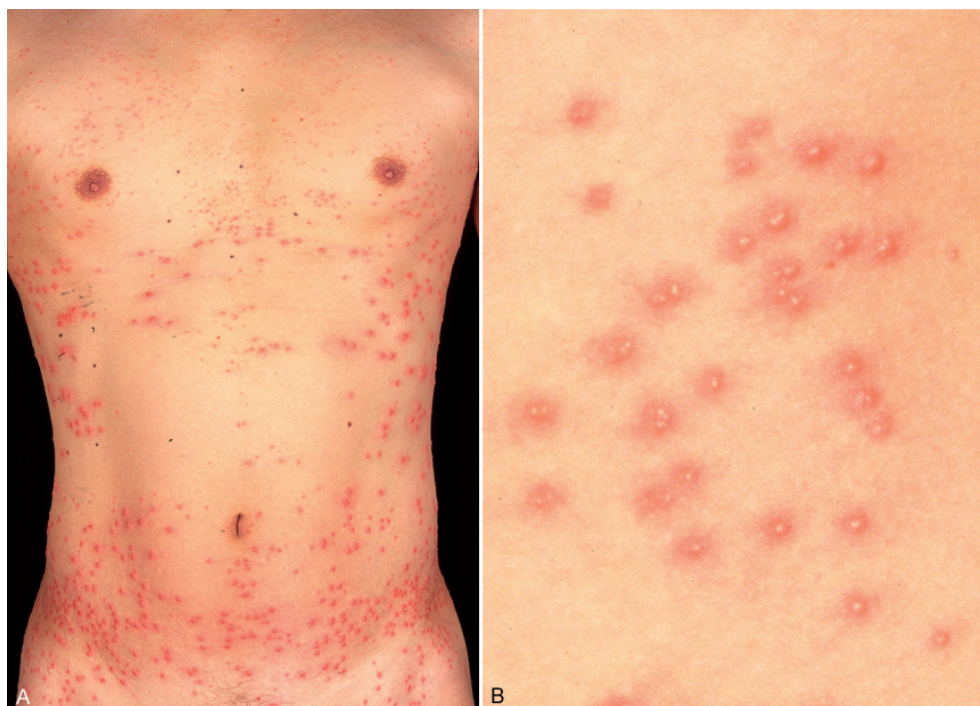

Fig. 1. Clinical manifestation. (A) Discrete pustules on the trunk. (B) Close up. Each eruption has a faint erythematous base and pustular centre.

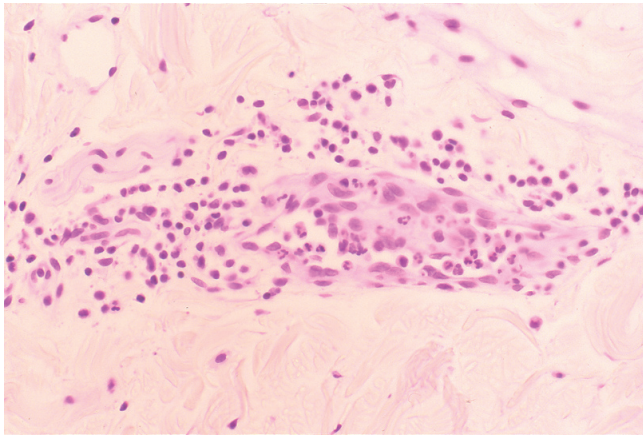


Fig. 2. A biopsy specimen from a faint erythema that appeared to be in its early stage shows Sweet's-like vasculitis (H&E  $\times 200$ ).

of the vessel walls. Small numbers of extravasated erythrocytes were also observed. Immunofluorescence of a dermal section revealed deposits of IgM, C3 and C1q around the small vessel walls in the reticular dermis. Based on these clinical manifestations, laboratory data, and histopathological features, we diagnosed this patient as having PICPV. At his request, the patient was observed without any treatment.

## DISCUSSION

Cutaneous pustular vasculitis includes a heterogeneous group of disorders characterized by pustules on purpuric bases. Although the cause of this group of conditions is diverse, the histopathological picture of the lesions is the same; a Sweet's-like or leukocytoclastic vasculitis. These distinctive lesions have been reported in the following diseases: Behçet's syndrome (2), bowel-associated dermatosis-arthritis syndrome (3), acute generalized pustular bacterid (AGPB) (4), and disseminated neisserial infections, such as gonococcal dermatosis-arthritis syndrome and chronic meningococcaemia, caused by *Neisseria gonorrhoeae* and *N. meningitidis*, respectively (5, 6). PICPV is a new clinical entity of cutaneous pustular vasculitis that lacks any underlying systemic disease. According to the original report (1), pustular lesions are distributed predominantly on the trunk and recur periodically every 3–4 months. Histological examination reveals Sweet's-like vasculitis, which is characterized by the following findings: (i) leukocytoclasia is minimal or absent, (ii) fibrinoid necrosis does not occur, (iii) extravasated erythrocytes are found in fewer numbers, and (iv) neutrophils, lymphocytes, and occasional eosinophils are infiltrated in and around the walls of small dermal vessels. Since the present case shares these clinical and

histopathological features with the original case, we diagnosed the patient as having PICPV. To the best of our knowledge, this is only the second published case of this disease.

Although PICPV is clinically different from AGPB, in that it recurs periodically, these two diseases share the clinical feature that other organ involvements, except for skin, are not observed. The deposition of immune complex in dermal small vessels is a remarkable characteristic of PICPV and AGPB (1, 7). In general, the small vessel vasculitides related to the deposition of immune complex, such as microscopic polyangiitis (8) and Henoch-Schönlein purpura (9), have the highest frequency of clinically significant renal involvement of any category of vasculitis. Based on this concept, the high specificity of PICPV and AGPB to the skin may be explained by the dermal-specific expression of chemokines, which recruit neutrophils. Further investigation of such factors may help to elucidate the pathogenesis of these diseases.

Considering that no similar cases have been reported for more than 20 years since the original report of PICPV, this clinical entity may be rare. However, this disease with mild clinical manifestation may be misdiagnosed, and it is postulated that the disease may be present more frequently than recognized. Therefore, the history of periodic recurrence should be investigated in patients with cutaneous pustular vasculitis.

## REFERENCES

1. McNeely MC, Jorizzo JL, Solomon AR Jr, Schmalstieg FC, Cavallo T. Primary idiopathic cutaneous pustular vasculitis. *J Am Acad Dermatol* 1986; 14: 939–944.
2. Ghatge JV, Jorizzo JL. Behçet's disease and complex aphthosis. *J Am Acad Dermatol* 1999; 40: 1–18.
3. Stein HB, Schlappner OL, Boyko W, Gourlay RH, Reeve CE. The intestinal bypass: arthritis-dermatitis syndrome. *Arthritis Rheum* 1981; 24: 684–690.
4. Tan RS. Acute generalized pustular bacterid. An unusual manifestation of leukocytoclastic vasculitis. *Br J Dermatol* 1974; 91: 209–215.
5. Benoit FL. Chronic meningococcaemia. Case report and review of the literature. *Am J Med* 1963; 35: 103–112.
6. Rompalo AM, Hook EW 3rd, Roberts PL, Ramsey PG, Handsfield HH, Holmes KK. The acute arthritis-dermatitis syndrome. The changing importance of *Neisseria gonorrhoeae* and *Neisseria meningitidis*. *Arch Intern Med* 1987; 147: 281–283.
7. Miyachi Y, Danno K, Yanase K, Imamura S. Acute generalized pustular bacterid and immune complexes. *Acta Derm Venereol* 1980; 60: 66–69.
8. Seo P, Stone JH. The antineutrophil cytoplasmic antibody-associated vasculitides. *Am J Med* 2004; 117: 39–50.
9. Fogazzi GB, Pasquali S, Moriggi M, Casanova S, Damilano I, Mihatsch MJ, et al. Long-term outcome of Schönlein-Henoch nephritis in the adult. *Clin Nephrol* 1989; 31: 60–66.