

Painful Buruli Ulcer in a Malian Visitor to France

Khaled Ezzedine¹, Thierry Pistone², Véronique Guir³ and Denis Malvy²

¹Dermatology Department, Hôpital St-André, 1, Rue Jean Burguet, FR-33075 Bordeaux, ²Travel Clinics and Tropical Disease Unit, Department of Internal and Tropical Medicine, University Hospital Center, Bordeaux, and ³Internal Medicine Department, Saint-Nazaire Hospital Center, Saint-Nazaire, France. E-mail: khaled.ezzedine@chu-bordeaux.fr
Accepted February 4, 2010.

Buruli ulcer, a skin disease caused by infection with *Mycobacterium ulcerans*, has been reported rarely in visitors to Western industrialized countries (1).

We describe here a case of a 44-year-old Malian man who visited France for a training course in firefighting.

CASE REPORT

The patient presented on 13 November 2007 with a 2-month history of a necrotic ulcer with a seropurulent discharge. He came from Niore, Mali, near the frontier with Mauritania, and he had never travelled abroad before visiting France. He reported walking in the mud with bare feet and legs when farming. The lesion began during the rainy season as a subcutaneous nodule on his right leg, which developed into a small, centrally crusted ulcer over a one-month period. The ulcer subsequently enlarged, becoming painful. On examination, he was found to have pyrexia at 38.3°C. There was gross pitting oedema to the mid-calf of his right leg, obliterating the peripheral leg pulses, and two skin necrotic ulcers with undermined edges and seropurulent discharge over the external side of his lower right leg (5 × 3 × 1 cm) and the lateral malleolus (5 × 5 × 4 cm) (Fig. 1). Laboratory investigations were within normal limits, except for a white cell count of 18.7 × 10⁹/l (neutrophils 80%), erythrocyte sedimentation rate of 70 mm/h and a C-reactive protein level of 120 mg/l (normal <5 mg/l). Blood cultures were negative. Initial wound swabs grew *Candida tropicalis*. Biopsies were taken from the wrist ulcer. Histological examination revealed dermal inflammation with necrotizing, granulomatous tissue, suggesting an infection with atypical *Mycobacterium*. Stains for acid-fast bacilli and fungi were negative. Biopsy culture with Lowenstein-Jensen medium (at 31°C for *M. ulcerans*) remained negative. DNA analysis using specific probes for the insertion sequence 2404 and the keratoreductase B domain (gene KRT) confirmed the presence of *M. ulcerans* DNA.

An oral antibiotic regimen (rifampicine 600 mg/day and clarithromycin 1000 mg twice a day for 2 months) complemented with antifungal therapy was started, and the ulcers were dressed regularly. The patient decided to return to Mali at the beginning of December 2007 (20 days after the start of therapy) and was

recommended to consult a surgeon for complementary exeresis of the lesion.

DISCUSSION

Buruli ulcer, *M. ulcerans* infection, is primarily a disease of the subcutaneous fat, which has been reported in over 30 tropical and sub-tropical countries (1). West Africa is the most affected region. Rare cases have also been reported in non-tropical areas, usually among immigrants from endemic areas (2). To date, there has been no formal report of the disease from the north of Mali, although neighbouring countries to the south, such as Burkina Faso, are known to be endemic for the infection. The disease usually occurs in localized areas near lakes or slow-moving rivers (3). The mechanism of transmission is thought to be through infection of simple grazes on the skin by water from rivers, ponds or mud, the rainy season being the time when most infections occur (4). Moreover, migratory birds may be involved in the dissemination of the disease between wetlands, leading to the appearance of new foci (5). Differential diagnosis for *M. ulcerans* infection should include other causes of tropical ulcers. In particular phagedenic or tropical ulcer, a painful, rapidly growing, sloughing ulcer, usually located on the leg should be ruled out (6).

An instructive aspect of this case is the painful character of the ulcerative form of the illness, whereas it is usually described as painless. Moreover, it is noteworthy that this case of Buruli ulcer came from the area of the Sahelian region at the frontier between Mali and Mauritania, where there is less evidence for favourable environmental factors for the pathogen.

REFERENCES

1. World Health Organization (WHO). Buruli ulcer disease. *Mycobacterium ulcerans* infection: an overview of reported cases globally. *Wkly Epidemiol Rec* 2004; 79: 194–200.
2. Evans M, Mawdsley J, Bull R, Lockwood DN, Thangaraj H, Shanahan D, et al. Buruli ulcer in a visitor to London. *Br J Dermatol* 2003; 149: 907–909.
3. Hayman J. Postulated epidemiology of *Mycobacterium ulcerans* infection. *Int J Epidemiol* 1991; 20: 1093–1098.
4. Wansbrough-Jones M, Phillips R. Buruli ulcer: emerging from obscurity. *Lancet* 2006; 367: 1849–1858.
5. Eddyani M, Ofori-Adjei D, Teugels G, De Weirtd D, Boakye D, Meyers WM, et al. Potential role for fish in transmission of *Mycobacterium ulcerans* disease (Buruli ulcer): an environmental study. *Appl Environ Microbiol* 2004; 70: 5679–5681.
6. Lupi O, Madkan V, Trying SD. Tropical dermatology: bacterial tropical diseases. *J Am Acad Dermatol* 2006; 54: 559–578.

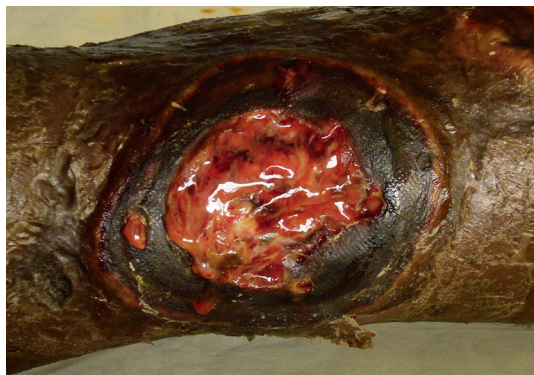


Fig. 1. Necrotic skin ulcer, with undermined edges and seropurulent discharge, over the external side of the lower right leg in a Malian visitor to France.