

Procalcitonin as a Biomarker for Toxic Shock Syndrome

Madoka Kato^{1,2}, Sakae Kaneko², Kenji Takagaki², Yoshitaka Kohayagawa², Tessin Watanabe¹, Yuichi Yoshida¹ and Osamu Yamamoto¹

¹Division of Dermatology, Department of Medicine of Sensory and Motor Organs, Faculty of Medicine, Tottori University, 86 Nishi-cho, Yonago, Tottori, 683-8503 and ²Department of Dermatology and Emergency and Critical Care Medicine, Shimane Prefectural Central Hospital, Shimane, Japan. E-mail: tessin@grape.med.tottori-u.ac.jp

Accepted February 18, 2010.

Toxic shock syndrome (TSS) is a type of systemic inflammatory response syndrome (SIRS) induced by a superantigen of *Staphylococcus aureus* (1–3). Procalcitonin is thought to be a highly specific and sensitive biological marker for severe bacterial infections (4). We report here a case of a 35-year-old woman with TSS who had a very high level of procalcitonin. To our knowledge, there are no previous reports of association of TSS with procalcitonin level.

CASE REPORT

A 35-year-old woman presented with a 3-day history of skin lesion, fever and vomiting. She had undergone an operation for osmidrosis axillae 10 days previously, and had been treated with cefaclor and loxoprofen for 10 days.

Physical examination revealed generalized erythema (Fig. 1a) with a high fever of 40.2°C, oedema of the extremities, blood pressure of 94/55 mmHg, pulse of 153/

min, congestion of the conjunctiva, nausea, vomiting, headache and rubor of the pharynx. In addition, significant rubor and ulcer with effusion was seen on both axillae. We suspected drug eruption or toxic eruption caused by bacterial infection of the operation site. After admission, her general condition became worse, and dyspnoea and hypotension (80/50 mmHg) developed. Results of laboratory investigation were as follows: white blood cell count, 20000/μl (normal 3300–8800/μl) with 66% neutrophils and 0% eosinophils; red blood cell count, $4.64 \times 10^6/\mu\text{l}$ (normal $3.6\text{--}5.1 \times 10^6$); haemoglobin, 14.1 g/dl (normal 11.0–15.0 g/dl); platelet count, $19.2 \times 10^4/\mu\text{l}$ (normal $12.5\text{--}34.3 \times 10^4$); serum C reactive protein (CRP) level, 26.0 mg/dl (normal <0.2 mg/dl); total bilirubin, 14.1 mg/dl (normal 0.2–1.2 mg/dl); aspartate aminotransferase (AST) level, 95 IU/l (normal 13–33 IU/l); alanine aminotransferase (ALT) level, 259 IU/l (normal 8–42 IU/l); lactate dehydrogenase (LDH) level, 275 IU/l (normal 119–229 IU/l); blood urea nitrogen, 42.2 mg/dl (normal 8–22 mg/dl); creatinine, 0.85 mg/dl (normal 0.4–0.7 mg/dl). The level of procalcitonin was more than 10 ng/ml (normal <0.1 ng/ml). Chest X-ray and echocardiogram showed mild heart failure.

We initially suspected TSS caused by postoperative infection. However, we found that she had used a tampon for menstruation 7 days previously. Culture from blood and the postoperative wound did not reveal any microorganisms, but methicillin-resistant *S. aureus* (MRSA) was detected on the tampon. Based on these findings, we diagnosed TSS induced by MRSA.

In addition to standard care for shock, she was treated with a combination of antibiotics (vancomycin, meropenem and clindamycin). Her general condition improved within one week and erythemas disappeared with pigmentation. Lamellar desquamation of the acral lesions was seen one week after the disappearance of erythema (Fig. 1b). Her procalcitonin level decreased to less than 0.5 ng/ml after 2 weeks, along with improvement of symptoms. CRP levels decreased in parallel with procalcitonin levels. In addition, staphylococcal enterotoxin-A (SEA) was later identified from her serum (the measurement of SEA was supported by Toray Industries, Inc.).

DISCUSSION

TSS is a severe staphylococcal infectious disease with high fever, rash, hypotension and multi-organ failure

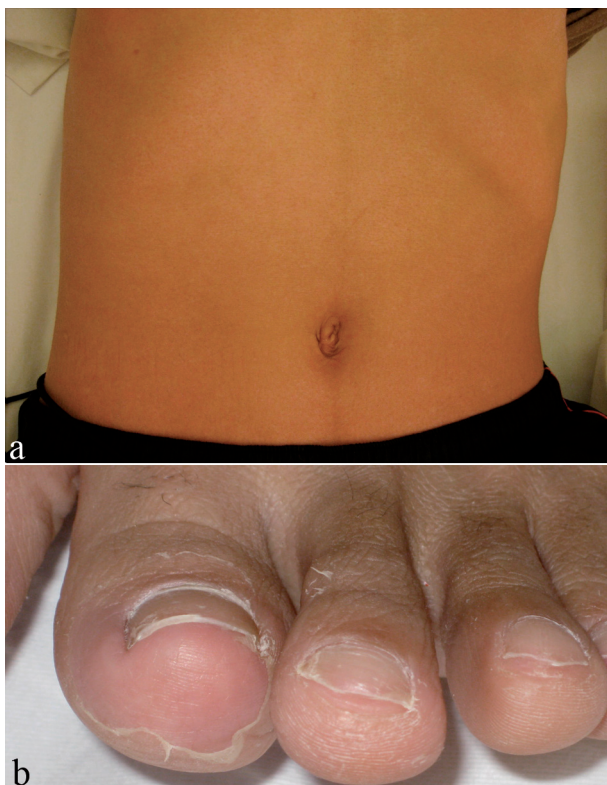


Fig. 1. (a) Erythema on the trunk. (b) Lamellar desquamation on the toes.

(1, 5). The term “systemic inflammatory response syndrome”(SIRS) was coined to describe the common systemic response to a wide variety of insults. It is characterized by two or more of the following clinical manifestations: (i) body temperature $>38^{\circ}\text{C}$ or $<36^{\circ}\text{C}$; (ii) heart rate >90 beats/min; (iii) tachypnoea, as manifested by a respiratory rate >20 beats/min; (iv) alteration of the white blood count of $>12,000$ cell/ mm^3 , <4000 cell/ mm^3 , or the presence of $>10\%$ immature neutrophils. When SIRS is the result of a confirmed infectious process, it is recognized as sepsis (2, 3). Therefore, we consider the aetiology of TSS to be sepsis. Predisposing conditions for TSS include post-operative state, burn and tampon usage for menstruation in young women (1, 5). Recently, there have been some reports of TSS induced by MRSA (5). TSS-associated MRSA isolates were shown to possess seven types of superantigen genes (5). Skin lesions usually develop generalized erythema and desquamation on the palms and soles 2 week later. Differential diagnosis of TSS includes streptococcal scarlet fever, staphylococcal scaled skin syndrome, measles and severe drug eruption (e.g. drug rash with eosinophilia and systemic symptoms (DRESS)) (6, 7). TSS without some diagnostic criteria such as hypotension is defined as “probable TSS” (8). At first, we suspected drug eruption as a differential diagnosis because of lack of hypotension. However, eosinophilia was not seen in our patient and all diagnostic criteria for TSS were finally satisfied after admission. Procalcitonin is considered to be a highly specific and sensitive biological marker for severe bacterial infections. Under normal conditions, very low concentrations of procalcitonin (<0.1 ng/ml) are observed in serum. In severe sepsis, procalcitonin level is very high (>10 ng/ml) (2, 4). Although procalcitonin is increased in some non-infectious diseases, including severe DRESS, the level is less than 5 ng/ml (9). In

the present case, we used a semi-quantitative method with immunochromatography (BRAHMS PCT[®]-Q-Diagnostica GmbH, Henningsdorf, Germany) for a procalcitonin assay, which gave a rapid result (30 min) (10). In addition, the procalcitonin level in our patient decreased along with improvement of symptoms. It is often difficult to differentiate “probable TSS” from other non-bacterial systemic cutaneous infections and drug eruption. Therefore, we consider that procalcitonin is a potential early diagnostic and therapeutic marker for TSS and probable TSS.

REFERENCES

1. Todd J, Fishaut M, Kapral F, Welch T. Toxic-shock syndrome associated with phage-group-I staphylococci. *Lancet* 1978; 25: 1116–1118.
2. Mitaka C. Clinical laboratory differentiation of infectious versus non-infectious systemic inflammatory response syndrome. *Clin Chim Acta* 2005; 351: 17–29.
3. Marik PE. Definition of sepsis. *Crit Care Med* 2002; 30: 706–708.
4. Brunkhorst FM, Wegscheider K, Forycki ZF, Brunkhorst R. Procalcitonin for early diagnosis and differentiation of SIRS, sepsis, severe sepsis, and septic shock. *Intensive Care Med* 2000; 26: 148–152.
5. Lappin E, Ferguson AJ. Gram-positive toxic shock syndromes. *Lancet Infect Dis* 2009; 9: 281–290.
6. Todd JK. Toxic shock syndrome. *Clin Microbiol Rev* 1988; 1: 432–446.
7. Passeron T, Ndir MC, Aubron C, Hovette P. Drug rash with eosinophilia and systemic symptoms (DRESS) due to streptomycin. *Acta Derm Venereol* 2004; 84: 92–93.
8. Tofte RW, Williams DN. Toxic-shock syndrome. Evidence of a broad clinical spectrum. *JAMA* 1981; 246: 2163–2167.
9. Sfia M, Boeckler P, Lipsker D. High procalcitonin levels in patients with severe drug reactions. *Arch Dermatol* 2007; 143: 1591.
10. Fioretto JR, Borin FC, Bonatto RC, Ricchetti SM, Kurokawa CS, de Moraes M et al. Procalcitonin in children with sepsis and septic shock. *J Pediatr* 2007; 83: 323–328.