

## Two Cases of Severe Refractory Chronic Idiopathic Urticaria Treated with Omalizumab

Christian Vestergaard and Mette Deleuran

Department of Dermatology, Aarhus University Hospital, PP Oerumsgade 11, DK-8000 Aarhus C, Denmark. E-mail: Chr-vest@post9.tele.dk  
Accepted March 11, 2010.

Treatment of chronic idiopathic urticaria (CIU) may pose a problem in daily clinical practice when patients do not respond either to standard treatment with antihistamines or to other treatments, such as mycophenolate mofetil, cyclosporine or immunoglobulins, as recommended by the guidelines of the European Academy of Allergy and Clinical Immunology/Global Allergy and Asthma European Network/European Dermatology Forum (EAACI/GA<sup>2</sup>LEN/EDF) (1). From the paradigm of biological therapies using specific targeted antibodies, the use of IgG-anti-IgE-antibodies against allergic asthma has emerged, and has been shown to have a beneficial effect on chronic urticaria, both with increased and normal serum IgE levels.

We report here two cases of very severe CIU that did not respond to any kind of therapy except omalizumab, to which they responded excellently as measured by daily quality of life index (DQLI) (2) and urticaria activity score over 7 days (UAS7) (3).

### CASE REPORTS

#### Case 1

A 33-year-old woman presented to our urticaria clinic with a 3-year history of severe CIU. She had daily flares of urticaria and severely impaired quality of life. She had normal thyroid parameters, no signs of infection, normal IgE levels, negative histamine release (HR) test, negative breath test for *H. pylori*, and no signs of physical urticaria. She did, however, have a history of fibromyalgia treated by rheumatologists. She had undergone treatment with antihistamines in up to four-fold doses of the recommended dose, alone and in combination with azathioprine, cyclosporine and mycophenolate mofetil with no effect on the disease.

By the time of her referral to our clinic she was being treated with prednisolone 80 mg daily and mycophenolate mofetil 1.5 g twice daily.

We decided initially to treat the patient with intravenous immunoglobulins (IVIG) 1 g/kg bodyweight daily for 2 days. However, after the first day of treatment the patient developed symptoms of meningitis (severe headache, photophobia and neck stiffness). She was immediately treated with intravenously penicillin and referred to the department of infectious diseases. The cerebrospinal fluid showed very high counts of white blood cells, but no bacteria could be cultured or detected by PCR, and we therefore assumed that she had aseptic meningitis, a well-known side-effect of treatment with IVIG (4). Since this side-effect has a very high rate of recurrence we did not try this treatment again.

The patient was then offered treatment with omalizumab, 300 mg subcutaneously, every fourth week based on body weight and serum IgE level. At the beginning of the treatment the patient's DQLI index was 25 and the urticaria activity score for the preceding 7 days (UAS7) was 35. After the first 4 weeks the DQLI was 2 and UAS7 was 8, and after another 4 weeks both had fallen to 0 (Fig. 1). We began to taper both prednisolone and mycophenolate mofetil, and the patient now receives 7.5 mg of prednisolone, because of her fibromyalgia only, and 500 mg of mycophenolate twice daily, and still has no symptoms of urticaria.

#### Case 2

A 57-year-old woman presented with a 10-year history of severe idiopathic urticaria and severely impaired quality of life. The patient had had a positive HR test in 2001, but a negative test in 2007. She had normal thyroid parameters, increased IgE of 616 IU (normal

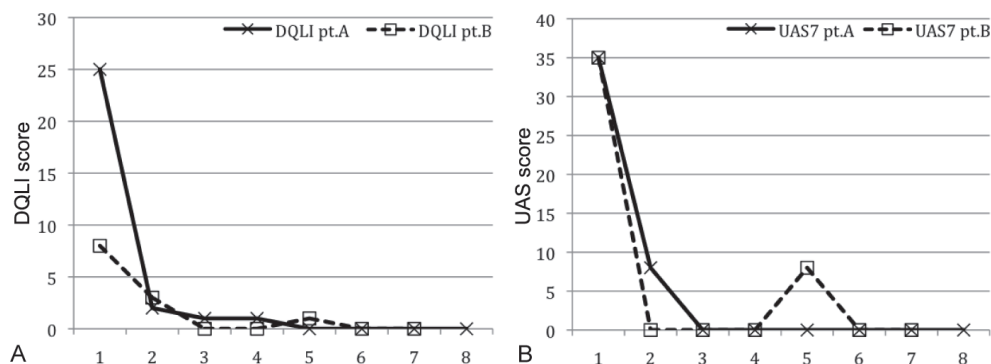


Fig. 1. (A) Development of daily quality of life index (DQLI) in patients 1 and 2. x-axis: visit number (visits at 4 week intervals, except for a period of 6 weeks between patient 2's visits 4 and 5 due to the patient's holidays). (B) Development of the urticaria activity score over 7 days (UAS7) for patients A and B. The increase in UAS7 for patient B at visit 5 is due to the above-mentioned 2-week delay.

< 150), negative hepatitis screening, negative *H. pylori* antibodies, negative cultures for intestinal parasites, negative *Borrelia* antibody titre, negative ANA, negative SSA and SSB and negative physical testing (warmth, cold, pressure and exercise).

Before referral to our urticaria clinic the patient had been treated with antihistamines, up to four-fold dose of the recommended dose, azathioprine, cyclosporine, methotrexate, mycophenolate mofetil, plasmapheresis and rituximab (anti-CD20), all in combination with antihistamine, but without any effect.

Based on body weight and serum IgE the patient should, according to the recommendations for asthma treatment, have been treated with 300 mg omalizumab every fourth week. However; since our first patient had experienced abdominal side-effects (as described above) we decided to treat with 150 mg omalizumab subcutaneously every fourth week, and this had a remarkable effect. Before treatment the patient had a DQLI of 8 and a UAS7 of 35. After the first 4 weeks of treatment DLQI was reduced to 3 and UAS7 was reduced to 0. On the following 2 visits both DLQI and UAS7 were 0. However, at visit 5 UAS7 had increased to 8, probably due to the fact that the patient had to postpone this visit 2 weeks, thereby increasing the interval for injection to 6 weeks. This demonstrates that the patient, although well-treated with omalizumab, still has CIU. This patient receives no other treatment.

## DISCUSSION

The use of omalizumab, a humanized IgG1 $\kappa$  anti-IgE antibody, in CIU and angioedema has been described previously (5, 6), and a study on a small population of patients with autoimmune urticaria has been published (7). It is therefore well established that treatment with anti-IgE-antibodies may be useful in patients with chronic urticaria. The first drugs of choice for the treatment of chronic urticaria are antihistamines, and it is still our

opinion that if these are not effective even in a four-fold dose of the recommended dose, the EAACI/GA<sup>2</sup>LEN/EDF guidelines (1) should be followed. Even then, however, a few cases may still not respond to therapy. It has been speculated that the reduction in IgE due to treatment with anti-IgE-IgG-antibodies, may lead to a secondary downregulation of the Fc $\epsilon$ RI on the basophils, and this has been demonstrated to lead to a downregulation of functional IgG antibodies directed against this epitope (7). However, as shown in case 1, omalizumab also has an effect in patients with negative HR-test, although the mechanism for this is unclear. The two cases described here suggest that omalizumab treatment should have its place in the treatment of these severely affected patients with refractory CIU, and that the treatment is effective even for longer periods of time, as measured through the patient's DQLI and UAS7.

## REFERENCES

1. Zuberbier T, Bindslev-Jensen C, Canonica W, Grattan CE, Greaves MW, Henz BM, et al. EAACI/GA<sup>2</sup>LEN/EDF guideline: management of urticaria. *Allergy* 2006; 61: 321–331.
2. Finlay AY, Khan GK. Dermatology Life Quality Index (DLQI) – a simple practical measure for routine clinical use. *Clin Exp Dermatol* 1994; 19: 210–216.
3. Mlynek A, Zalewska-Janowska A, Martus P, Staubach P, Zuberbier T, Maurer M. How to assess disease activity in patients with chronic urticaria? *Allergy* 2008; 63: 777–780.
4. Sekul EA, Cupler EJ, Dalakas MC. Aseptic meningitis associated with high-dose intravenous immunoglobulin therapy: frequency and risk factors. *Ann Intern Med* 1994; 121: 259–262.
5. Sands MF, Blume JW, Schwartz SA. Successful treatment of 3 patients with recurrent idiopathic angioedema with omalizumab. *J Allergy Clin Immunol* 2007; 120: 979–981.
6. Spector SL, Tan RA. Effect of omalizumab on patients with chronic urticaria. *Ann Allergy Asthma Immunol* 2007; 99: 190–193.
7. Kaplan AP, Joseph K, Maykut RJ, Geba GP, Zeldin RK. Treatment of chronic autoimmune urticaria with omalizumab. *J Allergy Clin Immunol* 2008; 122: 569–573.