

QUIZ SECTION

Cystic Nodules Affecting Sexual Activity: A Quiz

Aleksandra Batycka-Baran¹, Wojciech Baran¹, Joanna Maj¹ and Jacek C. Szepietowski^{1,2}

¹Department of Dermatology, Venereology and Allergology, Wrocław Medical University, ul. Chalubinskiego 1, 50-368 Wrocław, and ²Ludwig Hirschfeld Institute of Immunology and Experimental Therapy, Polish Academy of Sciences, Wrocław, Poland. E-mail: jszepiet@derm.am.wroc.pl

A 38-year-old woman with a 25-year history of numerous cystic nodules and papules localized on the face, neck, chest, axillae, inguinal regions and vulva was referred to our department. Her mother, brother, sister and daughter had similar, but fewer lesions. In the last few years new cysts had appeared in the inguinal region and on the vulva impairing her sexual activity (Fig. 1) (Dermatology Life Quality Index (DLQI) score = 16 points). She was concerned about being seen in public, feeling physically unattractive and sometimes depressed.

Histopathology of the lesion excised from the axillary fold demonstrated a folded cystic lesion located in the mid-

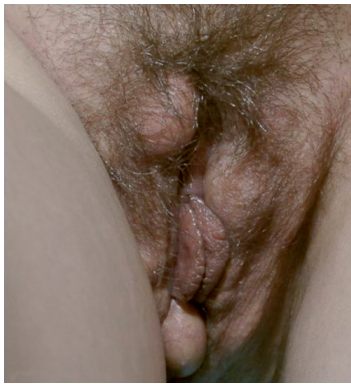

Fig. 1. Large, soft nodules on the vulva.

dermis (Fig. 2). In some parts of the lumen a small amount of eosinophilic horny material was present. No connection between the cyst wall and overlying epidermis was found. Immunohistochemical study showed the presence of keratin 17 in upper layer cells in the cyst wall.

What is your diagnosis?

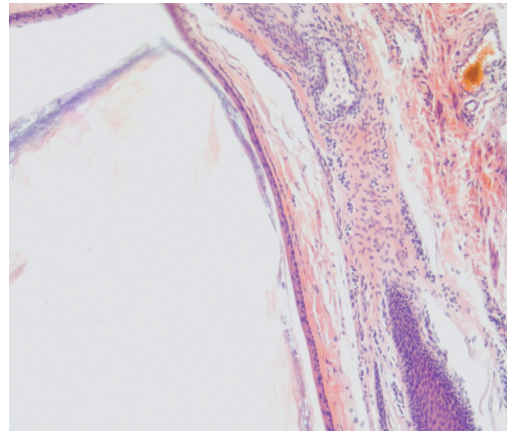


Fig. 2. Thin-walled cyst located in the mid-dermis. There is a small amount of eosinophilic horny material in the lumen. The wall of the cyst is lined with stratified squamous epithelium, without a granular cell layer (haematoxylin and eosin, original magnification $\times 200$). doi: 10.2340/00015555-0825

Cystic Nodules Affecting Sexual Activity: Comment

Acta Derm Venereol 2010; 90: XX–XX (contd)

Diagnosis: Steatocystoma multiplex

Steatocystoma multiplex (SM) is an uncommon disorder characterized by development of numerous dermal cysts, which are benign nevoid pilosebaceous gland tumours. Although the condition is inherited in an autosomal dominant fashion, many sporadic cases have also been reported. The onset of SM tends to occur during adolescence or early adulthood, and there is no evidence of any predilection as to gender or ethnicity. Clinically, the lesions appear as smooth, round, skin-coloured to yellowish papules or nodules, especially in the axillae, as in this patient (Fig. 3). The cyst may exude an oily or creamy fluid when punctured. Cysts range in diameter from a few millimetres to several centimetres, and are typically located in areas where the pilosebaceous apparatus is well developed (1, 2). Cases of SM with predominantly acral and vulvar distribution have also been reported (3–5). The lesions are usually asymptomatic, but may become inflamed, rupture and heal with scarring, as was reported by our patient.

The histopathology of SM is characterized by the presence of empty cyst formed by a thin wall of stratified squamous epithelium without a granular layer. Sebaceous

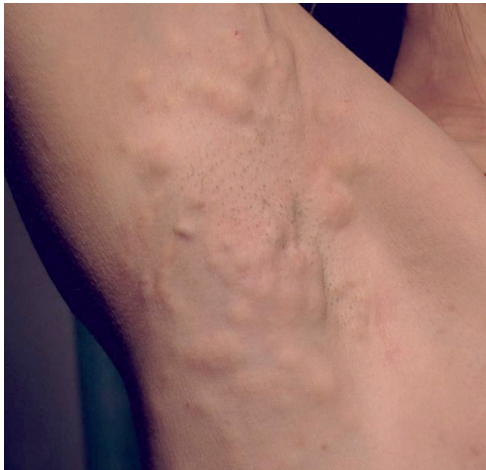

Fig. 3. Numerous smooth-surfaced, skin-coloured nodules in the axillary fold.

glands or atrophic sebaceous elements are presented adjacent to or within the cyst wall (1, 2, 6).

The origin of SM is uncertain, but it is probably derived from either transformed sebaceous ducts or cells differentiating toward the sebaceous duct because of comparable keratin expression (7). Immunohistochemical study reveals the presence of keratin 17 in upper layer cells in the cyst wall, whereas basal and parabasal layers are positive for keratin 14 (7). Treatment is not usually required, but in many cases the disease affects the psychological well-being of the patients. Surgical care, e.g. aspiration, excision, carbon dioxide laser therapy or liquid nitrogen cryotherapy, performed for cosmetic reasons, is sufficient in less severe cases. In the present case surgical excision of all the vulvar cysts was performed successfully. At follow-up after 4 weeks, the patient reported an improvement in the quality of her sex life. The DLQI score decreased from 16 to 7 points. In inflammatory type of SM oral antibiotics and isotretinoin could be used, but this treatment is not fully effective (1, 2, 8).

REFERENCES

1. Plewig G, Wolf HH, Braun-Falco O. Steatocystoma multiplex, anatomic reevaluation, electron microscopy and autoradiography. *Arch Dermatol Res* 1982; 272: 363–380.
2. Cho S, Chang SE, Choi JH, Sung KJ, Moon KC, Koh JK. Clinical and histological features of 64 cases of steatocystoma multiplex. *J Dermatol* 2002; 29: 152–156.
3. Rongioletti F, Cattarini G, Romanelli P. Late onset vulvar steatocystoma multiplex. *Clin Exp Dermatol* 2002; 27: 445–447.
4. Rollins T, Levin RM, Heymann WR. Acral steatocystoma multiplex. *J Am Acad Dermatol* 2000; 43: 396–399.
5. Yangi T, Matsumura T. Steatocystoma multiplex presenting as acral subcutaneous nodules. *Acta Derm Venereol* 2006; 86: 374–375.
6. Yamada A, Saga K, Jimbow K. Acquired multiple pilosebaceous cysts on the face having the histopathological features of steatocystoma multiplex and eruptive vellus hair cysts. *Int J Dermatol* 2005; 44: 861–863.
7. Kurokawa I, Nishijima S, Kusumoto K, Senzaki H, Shikata N, Tsubura A. Cytokeratin expression in steatocystoma multiplex. *Br J Dermatol* 2002; 146: 534–536.
8. Kaya TI, Ikizoglu G, Kokturk A, Tursen U. A simple surgical technique for the treatment of steatocystoma multiplex. *Int J Dermatol* 2001; 40: 785–788.