

CLINICAL REPORT

Hydroa Vacciniforme with Mucosal Involvement and Recalcitrant Periodontitis and Multiple Virus Re-activators after Sun-exposure

Aya NISHIZAWA, Takahiro SATOH, Kaoru TAKAYAMA and Hiroo YOKOZEKI
Department of Dermatology, Graduate School, Tokyo Medical and Dental University, Tokyo, Japan

An 8-year-old boy presented with hydroa vacciniforme with recurrent oral mucosal ulcers and treatment-resistant gingivitis/periodontitis. Symptoms of oral mucosal involvement and gingivitis/periodontitis mirrored the severity of the skin lesions in sun-exposed areas. Although Epstein-Barr virus was negative in the skin lesions, Epstein-Barr virus DNA was detected in the gingival lesions when skin disease activity increased. Human herpes viruses-6 and -7 were also positive in the gingival lesions. Notably, human parvovirus B19 DNA was detected in both skin and gingival lesions. Impairment of systemic immunity was not detected. This report describes a rare case of hydroa vacciniforme with mucosal involvement and periodontal disease accompanied by multiple local virus re-activation. **Key words:** Epstein-Barr virus; human herpes virus; human parvovirus B19; ultraviolet light.

(Accepted April 8, 2010.)

Acta Derm Venereol 2010; 90: 498–501.

Takahiro Satoh, Department of Dermatology, Graduate School, Tokyo Medical and Dental University, 1-5-45 Yushima, Bunkyo-ku, Tokyo 113-8519, Japan. E-mail: tasa-1688.derm@tmd.ac.jp

Hydroa vacciniforme (HV) is a rare disorder characterized by papulovesicles on sun-exposed areas, such as the face and dorsal surfaces of the hands. The pathological mechanisms of HV are uncertain, but activation of Epstein-Barr virus (EBV) may contribute to the development of skin symptoms (1, 2). Successful treatment with antiviral agents, such as acyclovir/valacyclovir, has been reported in some cases of HV (3). We report here a case of HV with recurrent oral ulcers and gingivitis/periodontitis that were aggravated after sun exposure in parallel with the skin lesions. Although the skin lesions were negative for EBV, the amount of EBV DNA in gingival lesions increased with disease activity. Additional analyses of the re-activation of various viruses with respect to the skin and gingival symptoms were also performed.

CASE REPORT

An 8-year-old boy presented with a 1-month-history of repeated eruptions on the face after sun exposure. He had had refractory gingivitis/periodontitis for 3 years. A physical examination revealed multiple small papules and blisters on the cheeks and auricles with scarring (Fig. 1). He also had oral erosions/ulcers on the lower lip (Fig. 2A

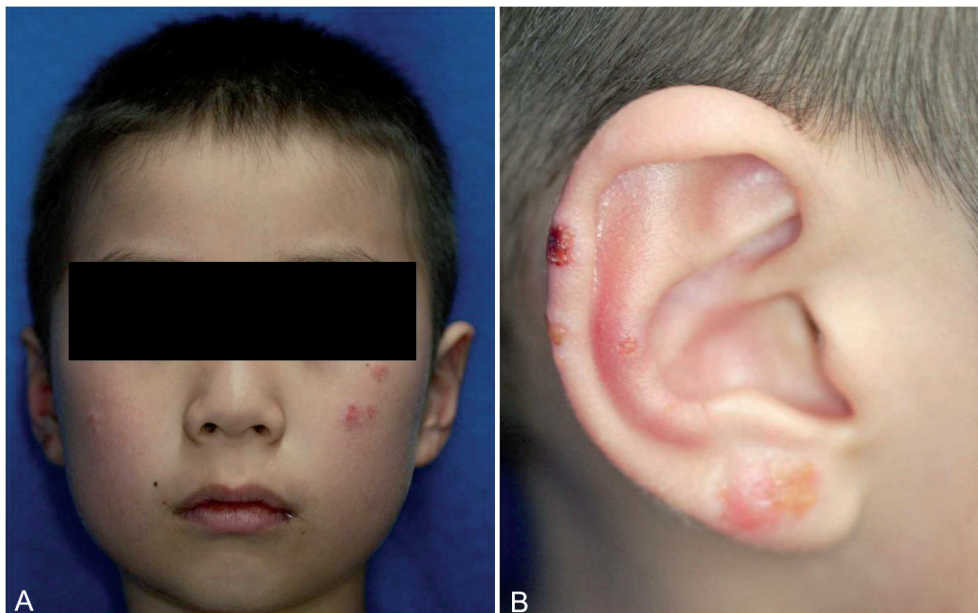

Fig. 1. Clinical manifestations on the face. Crusted papules and blisters are scattered on the cheek and auricles, with atrophic scarring.

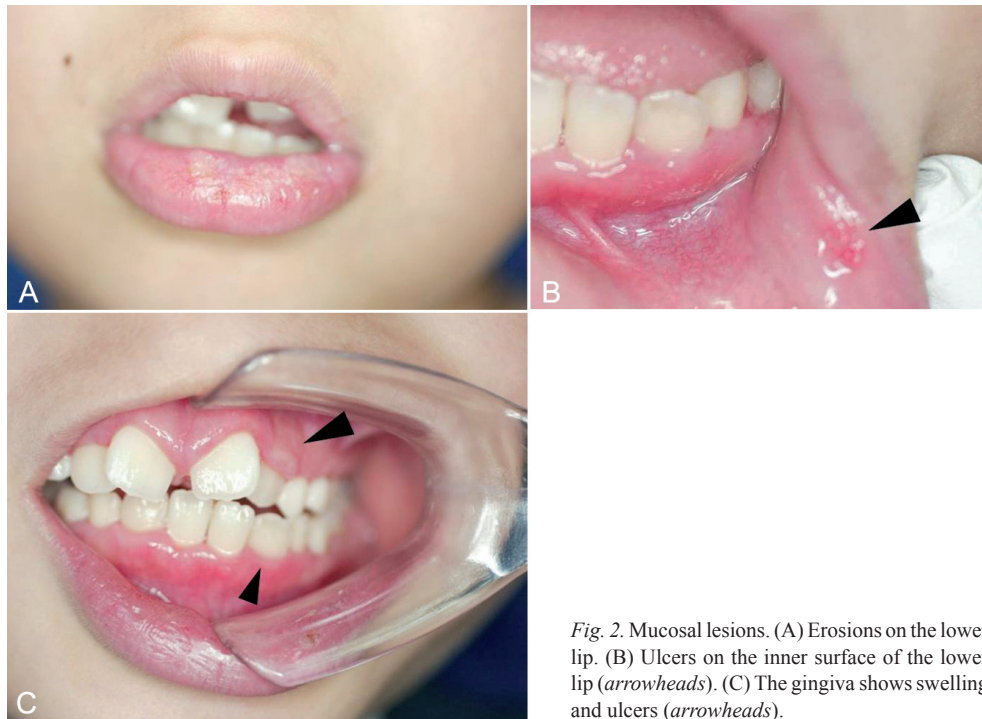


Fig. 2. Mucosal lesions. (A) Erosions on the lower lip. (B) Ulcers on the inner surface of the lower lip (arrowheads). (C) The gingiva shows swelling and ulcers (arrowheads).

and B) and buccal mucosa. The gingiva were swollen, and ulcers were present (Fig. 2C). The patient did not have a history of severe hypersensitivity to mosquito bites. None of his relatives had similar symptoms.

The laboratory findings, including blood cell counts and liver function tests, were within normal limits. Erythrocyte protoporphyrin levels were not elevated. The phototest revealed no abnormal reaction to ultraviolet A (UVA), and the minimal erythema dose to UVB was not decreased. Photoprovocation testing by repetitive UVA irradiation (10 J/cm²) for 4 consecutive days was negative. Bacterial cultures from the gingiva demonstrated *Capnocytophaga* species and *Bacillus subtilis*.

The blood CD4/CD8 lymphocyte ratio was 1:1. Serum antibody titres for EBV were: EBV nuclear antigen (EBNA) Ab 1:10; VCA (viral capsid antigen)-IgG 1:20; VCA-IgM < 1:10. EBV DNA levels in peripheral blood mononuclear cells and serum were below the detection limits. The patient did not have abnormalities in cellular immunity as detected by the lymphocyte proliferation assay in response to phytohemagglutinin and/or concanavalin A. Neutrophil bactericidal and phagocytic activities were normal.

Histological examination of a skin lesion revealed the formation of intraepidermal bullae, and a dense cellular infiltrate in the entire dermis (Fig. 3A). The infiltrates consisted largely of lymphocytes with no nuclear atypia. Immunohistochemical analyses showed marked infiltration of CD4 (+) cells and, to a lesser extent, of CD8 (+) cells (Fig. 3B and C). The number of CD4 (+) cells was

approximately twice that of CD8 (+) cells. There were a number of cells expressing granzyme B- and/or T-cell intercellular antigen-1 (TIA-1) (Fig. 3D and E). A small number of CD20 (+) cells was also observed (Fig. 3F), but infiltration of CD56 (+) cells was sparse. Staining for latent membrane protein (LMP)-1 and EBNA was negative. EBV-encoded small nuclear RNA-1 (EBER-1) was not detected by *in situ* hybridization methods. Histological changes of gingival lesions were similar to those of skin lesions (data not shown).

Although the photoprovocation test was negative, the skin lesions frequently recurred after sun exposure. The recurrence of skin symptoms was accompanied by moderate fever, buccal mucosal ulcers, and aggravation of gingivitis, characterized by gingival bleeding, swelling, and ulcers.

While repeated examinations for EBV DNA in the blood and skin lesions were negative during the course of the disease, EBV DNA was detected in the samples from gingival lesions obtained by swabs when skin, oral, and gingival symptoms were aggravated (Fig. 4). Human herpes virus (HHV)-6 and -7 DNAs were also positive in gingival lesions, but they did not necessarily parallel the symptoms. Unexpectedly, human parvovirus B19 (HPV B19) DNA was detected from both skin and gingival lesions. On the other hand, herpes simplex virus (HSV)-1, HSV-2, and cytomegalovirus were not detected during the course of the disease.

The patient was followed up for 2 years with no antiviral therapy (3). No improvements were noted.

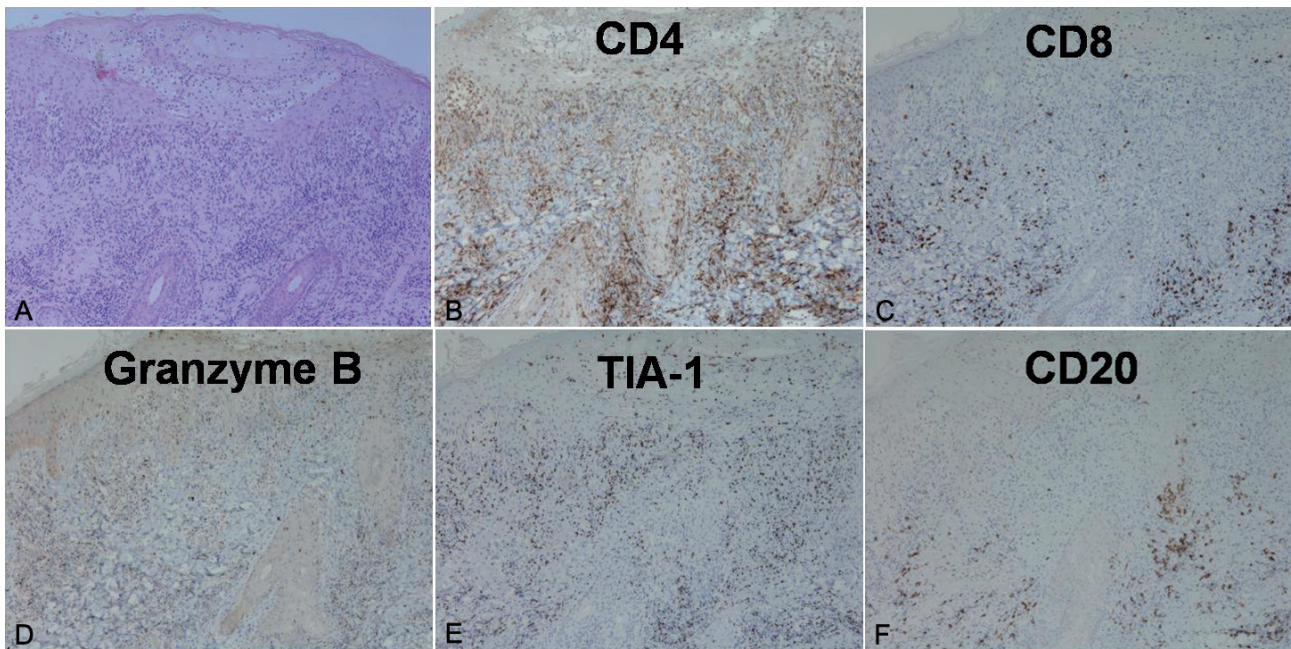


Fig. 3. Histological examination of skin lesions. (A) The epidermis shows degeneration and bulla formation. A dense cellular infiltrate consisting of lymphocytes is found in the dermis (haematoxylin and eosin, original magnification, $\times 100$). (B–F) Immunohistochemical staining of cellular infiltrates (diaminobenzidine, original magnification, $\times 100$).

DISCUSSION

HV is considered a photosensitive disorder, and sunlight exposure usually aggravates skin symptoms, although photoprovocation testing does not necessarily induce skin lesions. The patho-aetiology of skin lesions in HV is unknown, but recent findings have demonstrated the close link between EBV infection and HV (1, 2). EBER-positive cells are frequently observed in both typical HV and severe HV; severe HV has a high risk of progressing to EBV-associated malignant complications. In the present case, EBV DNA or EBER-positive cells were not detected in either peripheral blood or skin lesions, despite the fact that the case was clinically and histologically compatible with typical HV.

Mucosal involvement in HV is rare. It affects the lips and tip of the tongue, both of which are potentially photo-exposed areas (4, 5). The present case was peculiar, in that recurrent ulcers were observed on the inner surface of the lower lip and buccal mucosa. The patient also had treatment-resistant gingivitis/periodontitis; these oral symptoms mirrored the severity of the skin symptoms. In addition, EBV DNA was detected from gingival ulcer lesions and/or gingival pockets when systemic symptoms were prominent. Local DNA levels increased generally in association with the gingivitis and other symptoms (Fig. 4). Several lines of evidence have implicated herpes viruses, such as EBV and cytomegalovirus, in the pathogenesis of periodontal diseases, such as chronic periodontitis, juvenile periodontitis, and acute necrotizing ulcerative gingivitis (6–10). Both HHV-6 and -7 were also detected in the present case, and they have often been found in lesions of periodontitis, particularly in the lesions of HIV-infected patients (11). Pathogenic bacterial infection in periodontal tissues possibly promotes re-activation of viruses, which in turn may suppress periodontal immune defences and result in the overgrowth of periodontal bacterial pathogens (8, 12–13). In the present case, the aetiological relevance of the EBV found in the gingival lesions to the skin symptoms is uncertain. Nevertheless, the clinical evidence that the gingivitis/periodontitis was aggravated in association with the skin lesions after sun-exposure suggests a close pathogenic link between these lesions. CD8 (+) cytotoxic T cells activated by EBV in gingival lesions may participate in the development of papulovesicular lesions on sun-exposed areas, although we were unable to rule out the




Fig. 4. Clinical course and detection of viruses. ND: not detected.

possibility that virus-associated gingivitis/periodontitis only coincidentally affected the present patient with HV. Notably, a recent report described recurrent gingivitis and gum ulcers in a patient with HV (3).

It is intriguing that HPV B19 DNA was detected from both skin and gingival lesions, but it was not found in the peripheral blood. Primary infection of HPV B19 in children manifests as erythema infectiosum. In adults, HPV B19 infections cause more severe disease than in children with respect to systemic and cutaneous symptoms (14, 15). HPV B19 is also known as a causative agent in some cases of papular purpuric gloves and socks syndrome (16). HPV B19 can be re-activated in immunocompromised patients (17). The case presented herein had a history of erythema infectiosum 4 years before admission, and, it was thus likely that HPV B19 DNA was observed due to local re-activation during the course of disease. The present patient showed no impairment of systemic immune function. At present, we are unable to provide an exact explanation for the re-activation of HPV B19 and its involvement in the skin and gingival symptoms. Solar UV radiation may contribute to the re-activation of the virus, as seen in re-activation of HSV during recurrence of skin symptoms after sun exposure (18, 19).

This case illustrates a rare occurrence of mucosal involvement and gingivitis/periodontitis in a patient with HV. Further study is needed to elucidate whether the re-activation of several viruses, such as EB, HHV-6, -7, and HPV B19, in gingival tissues is related to the skin symptoms of HV.

The authors declare no conflicts of interest.

REFERENCES

- Iwatsuki K, Satoh M, Yamamoto T, Oono T, Morizane S, Ohtsuka M, et al. Pathogenic link between hydroa vacciniforme and Epstein-Barr virus-associated hematologic disorders. *Arch Dermatol* 2006; 142: 587–595.
- Iwatsuki K, Xu Z, Takata M, Iguchi M, Ohtsuka M, Akiba H, et al. The association of latent Epstein-Barr virus infection with hydroa vacciniforme. *Br J Dermatol* 1999; 140: 715–721.
- Lysell J, Wiegleb Edstrom D, Linde A, Carlsson G, Malmros-Svennilson J, Westermark A, et al. Antiviral therapy in children with hydroa vacciniforme. *Acta Derm Venereol* 2009; 89: 393–397.
- Yesudian PD, Sharpe GR. Hydroa vacciniforme with oral mucosal involvement. *Pediatr Dermatol* 2004; 21: 555–557.
- Wierzbicka E, Malthieu F, Villers A, Guillet G. Oral involvement in hydroa vacciniforme. *Arch Dermatol* 2006; 142: 651.
- Contreras A, Nowzari H, Slots J. Herpesviruses in periodontal pocket and gingival tissue specimens. *Oral Microbiol Immunol* 2000; 15: 15–18.
- Idesawa M, Sugano N, Ikeda K, Oshikawa M, Takane M, Seki K, et al. Detection of Epstein-Barr virus in saliva by real-time PCR. *Oral Microbiol Immunol* 2004; 19: 230–232.
- Kamma JJ, Contreras A, Slots J. Herpes viruses and periodontopathic bacteria in early-onset periodontitis. *J Clin Periodontol* 2001; 28: 879–885.
- Michalowicz BS, Ronderos M, Camara-Silva R, Contreras A, Slots J. Human herpesviruses and porphyromonas gingivalis are associated with juvenile periodontitis. *J Periodontol* 2000; 71: 981–988.
- Ting M, Contreras A, Slots J. Herpesvirus in localized juvenile periodontitis. *J Periodontol Res* 2000; 35: 17–25.
- Mardrossian A, Contreras A, Navazesh M, Nowzari H, Slots J. Herpesviruses 6, 7 and 8 in HIV- and non-HIV-associated periodontitis. *J Periodontol Res* 2000; 35: 278–284.
- Contreras A, Slots J. Herpesviruses in human periodontal disease. *J Periodontol Res* 2000; 35: 3–16.
- Sugano N, Ikeda K, Oshikawa M, Idesawa M, Tanaka H, Sato S, et al. Relationship between porphyromonas gingivalis, Epstein-Barr virus infection and reactivation in periodontitis. *J Oral Sci* 2004; 46: 203–206.
- Amano K, Takeuchi T. Parvovirus B 19 infection in adults. *Intern Med* 2002; 41: 247–248.
- Hayakawa H, Tara M, Niina K, Osame M. A clinical study of adult human parvovirus B19 infection. *Intern Med* 2002; 41: 295–299.
- McNeely M, Friedman J, Pope E. Generalized petechial eruption induced by parvovirus B19 infection. *J Am Acad Dermatol* 2005; 52 (5 Suppl 1): S109–113.
- Parsyan A, Candotti D. Human erythrovirus B19 and blood transfusion – an update. *Transfus Med* 2007; 17: 263–278.
- Goade DE, Nofchissey RA, Kusewitt DF, Hjelle B, Kreisel J, Moore J, et al. Ultraviolet light induces reactivation in a murine model of cutaneous herpes simplex virus-1 infection. *Photochem Photobiol* 2001; 74: 108–114.
- Ichihashi M, Nagai H, Matsunaga K. Sunlight is an important causative factor of recurrent herpes simplex. *Cutis* 2004; 74 (5 Suppl): 14–18.