

## Primary Cutaneous Aspergillosis

Keiko Nakashima, Nanako Yamada, Yuichi Yoshida and Osamu Yamamoto

Division of Dermatology, Department of Medicine of Sensory and Motor Organs, Faculty of Medicine, Tottori University, 36-1 Nishicho, Yonago, Tottori 683-8504, Japan. E-mail: kei2510@grape.med.tottori-u.ac.jp

Accepted February 4, 2010.

Cutaneous aspergillosis has been described as primary or secondary to haematogenous dissemination (1). Primary cutaneous aspergillosis usually follows local trauma and appears as a purplish oedematous lesion at the site of inoculation (2). We present here a rare case of primary cutaneous aspergillosis, which manifested as intractable nodules.

### CASE REPORT

A 66-year-old Japanese woman was referred to our clinic for evaluation of an asymptomatic nodule on the tip of her right thumb, which had appeared 1 month previously. Physical examination revealed a purplish nodule, 16 × 11 mm in size, with necrosis at the centre (Fig. 1). Her medical history was unremarkable. Results of routine laboratory examinations were within normal limits.

The patient had engaged in flower gardening as a hobby for the past 3 years, but had experienced no trauma. She had worn gloves on her hands whenever she had touched vegetables and flowers. The lesion was clinically suspected to be a granuloma teleangiectaticum.

Histopathologically, there was massive epidermal necrosis and dermal necrobiosis. The periphery of the lesion showed dermal infiltration of lymphocytes. Numerous fungal elements were easily identified in the area of epidermal necrosis (not shown).

Grocott staining revealed septate hyphae with branches at the superficial necrotic areas and rarely in the dermal necrobiosis

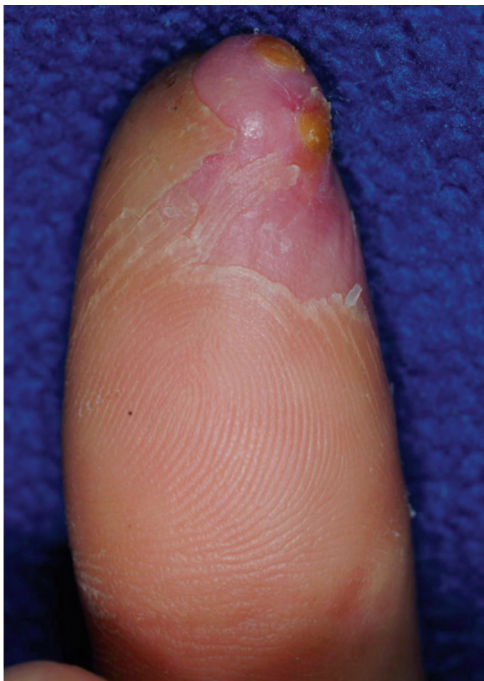

Fig. 1. A purplish nodule on the apex of the right thumb.

(Fig. 2). *Aspergillus flavus* was isolated by fungal culture from the biopsied specimen 2 weeks later. Based on these findings, a diagnosis of primary cutaneous aspergillosis, caused by *A. flavus*, was made.

The patient was treated with daily topical ketoconazole for 1 month, but this had no effect on the lesion. She was then treated with oral itraconazole, 100 mg daily for 1 month. However, the response was poor and the dosage of itraconazole was increased to 200 mg daily. This treatment resulted in complete healing of the lesion 13 weeks after the initiation of treatment.

### DISCUSSION

Primary cutaneous aspergillosis is comparatively rare (3, 4). It usually develops in relation to local trauma (intravenous injection site, injury or burns) (2). Clinically, it is characterized by the presence of violaceous macules, papules, haemorrhagic bullae, ulcerations with central necrosis, and pustules or subcutaneous abscess (5). The occurrence of varying clinical manifestations of fungal diseases has been demonstrated in patients with altered host defences (4). Immunocompromised patients with primary cutaneous aspergillosis occasionally present with solitary non-ulcerated nodules (6, 7). Our case showed a purplish skin nodule with no deficiency of immunological function or any severe diseases associated with fungal infection. To our knowledge, such a case has been reported only once so far (3). The patient developed oedematous, nodular lesions on her face, ears and scalp, and *A. niger* was isolated from the skin lesions (3).

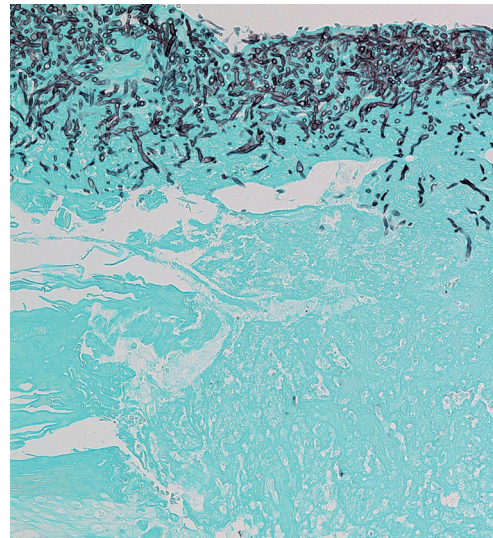


Fig. 2. Septate hyphae with branches, demonstrated by Grocott staining (×200). The staining disclosed dead hyphae within the superficial necrotic debris.

Fungi of the genus *Aspergillus* are widely distributed in the environment, particularly in soil and decomposed vegetation. The most frequent organisms causing cutaneous aspergillosis are *A. flavus* and *A. fumigatus*. Primary cutaneous aspergillosis, manifesting as a nodule on the finger, is predominantly caused by *A. flavus*, as in the present case. Although the patient reported that she had had no preceding trauma, we speculate that *A. flavus* was probably inoculated with a piece of wood or soil.

We believe the lesion to be primary aspergillosis because the fungal elements were found not only in the epidermal necrosis but also in the dermal necrobiosis. This is supported by the successful systemic antifungal therapy.

Recommended treatment for primary cutaneous aspergillosis includes voriconazole, itraconazole and amphotericin B. First-line therapy for such patients was previously intravenous amphotericin B (2). However, recent studies have suggested that a significant portion of *Aspergillus* species could be resistant to conventional treatment (8). Voriconazole has been shown to be statistically superior to amphotericin B as a treatment for aspergillosis in adults (9). Barret et al. (10) reported the usefulness of topical nystatin combined with systemic itraconazole. In the present case, oral administration of itraconazole (200 mg/day) was effective. It is therefore important for clinicians to consider the possibility of primary cutaneous aspergillosis, even if the patient is not immunocompromised.

## REFERENCES

- Galimberti R, Kowalczyk A, Hidalgo Parra I, Gonzalez Ramos G, Flores V. Cutaneous aspergillosis: a report of six cases. *Br J Dermatol* 1998; 139: 522–526.
- Isaac M. Cutaneous aspergillosis. *Dermatol Clin* 1996; 14: 137–140.
- Cahill KM, Mofty AM, Kawaguchi TP. Primary cutaneous aspergillosis. *Arch Dermatol* 1967; 96: 545–547.
- Carlile JR, Millet RE, Cho CT, Vats TS. Primary cutaneous aspergillosis in a leukemic child. *Arch Dermatol* 1978; 114: 78–80.
- Zhang QQ, Li L, Zhu M, Zhang CY, Wang JJ. Primary cutaneous aspergillosis due to *Aspergillus flavus*: a case report. *Chin Med J* 2005; 118: 255–257.
- Richards KA, Mancini AJ. A painful erythematous forearm nodule in a girl with Hodgkin disease. Diagnosis: primary cutaneous aspergillosis. *Arch Dermatol* 2000; 136: 1165–1170.
- Cornely OA, Pels H, Bethe U, Seibold M, Toepelt K, Soehngen D, et al. A novel type of metastatically spreading subcutaneous aspergillosis without epidermal lesions following allogenic stem cell transplantation. *Bone Marrow Transplant* 2001; 28: 899–901.
- Woodruff CA, Hebert AA. Neonatal primary cutaneous aspergillosis: case report and review of the literature. *Pediatr Dermatol* 2002; 19: 439–444.
- Herbrecht R, Denning DW, Patterson TF, Bennett JE, Greene RE, Oestmann JW, et al. Voriconazole versus amphotericin B for primary therapy of invasive aspergillosis. *N Engl J Med* 2002; 347: 408–415.
- Barret JP, Ramzy PI, Hegggers JP, Villareal C, Herndon DN, Desai MH. Topical nystatin powder in severe burns: a new treatment for angioinvasive fungal infections refractory to other topical and systemic agents. *Burns* 1999; 25: 505–508.