

CD8⁺ CD56⁺ Mycosis Fungoides with an Indolent Clinical Behaviour: Case Report and Literature Review

Yu Sawada¹, Kazunari Sugita¹, Rieko Kabashima¹, Ryosuke Hino¹, Motonobu Nakamura¹, Chizuko Koga² and Yoshiki Tokura¹

¹Department of Dermatology, University of Occupational and Environmental Health, 1-1 Iseigaoka, Yahatanishi-ku, Kitakyushu 807-8555, and ²Kokura Memorial Hospital, Kitakyushu, Japan. E-mail: long-ago@med.uoeh-u.ac.jp
Accepted December 3, 2009.

Mycosis fungoides (MF) is characterized by epidermotropic skin infiltration by atypical T lymphocytes. Although most cases of MF exhibit CD4⁺ tumour cells, cases of CD8⁺ MF are rare (1, 2). CD8⁺ MF may be further categorized into two groups by means of the expression of CD56, as CD8⁺ CD56⁺ and CD8⁺ CD56⁻ subtypes. Whereas rapid progression has been attributed to CD8 positivity in primary cutaneous CD8⁺ aggressive epidermotropic cytotoxic T-cell lymphoma (3), CD8⁺ MF shares the clinical behaviour with CD4⁺ MF. However, the clinical prognosis of CD8⁺ CD56⁺ MF is unknown. We report here a case of CD8⁺ CD56⁺ MF with an indolent clinical course and review the literature in order to investigate the prognosis further.

CASE REPORT

A 68-year-old Japanese woman presented with a 20-year history of an erythematous eruption. She was otherwise healthy and took no medication. Physical examination revealed scaly, erythematous, atrophic patches with hypo- and hyperpigmentation on her bilateral upper arms, left breast and right thigh (Fig. 1A–C). In addition to these poikilodermatous lesions, there were several indurated plaques. A full blood cell count and biochemical studies were normal, except for the presence of atypical lymphocytes in the peripheral blood (3.0%) and a slightly high level of lactate dehydrogenase (238 IU/l; normal 0–170 IU/l). Soluble IL-2 receptor was normal and human T-cell lymphotropic virus antigen was negative. A biopsy specimen taken from her right thigh revealed a dense infiltrate of small or medium-sized atypical lymphocytes with occasional mitotic figures in the dermis, with prominent epidermotropism (Fig. 1D). Southern blot analysis showed monoclonal rearrangement

of the T-cell receptor (TCR) β gene (C β 1). Immunohistochemical study revealed that atypical lymphocytes were positive for CD2, 3, 8, 56 and TIA-1, but negative for CD4, 7, 20, 30 and granzyme B (Fig. 2A). A flow cytometric analysis of skin-infiltrating lymphocytes, obtained by teasing of an indurated lesion, confirmed the presence of tumour cells positive for CD3, CD8 and CD56, but negative for CD4, CD25 and CD38 (Fig. 2B). *In situ* hybridization assay for EBEB-1 disclosed no Epstein Barr virus in the skin specimen. Computed tomography and gallium scintillation studies showed no involvement of internal organs or lymph nodes. The patient was diagnosed as having CD8⁺ CD56⁺ MF at Stage 1A (T1N0M0B0). She was treated with narrowband ultraviolet B (total 12,600 mJ/cm²) therapy, followed by oral psoralen plus ultraviolet A (PUVA) (total 49 J/cm²) for 6 months with clinical improvement. She is currently healthy without recurrence of skin eruptions.

DISCUSSION

Although the prognosis of MF is primarily defined by the clinical stage, there remains a possibility that the T-cell phenotype affects the clinical behaviour of MF. The neoplastic cells in MF have a mature CD4⁺ memory T-cell phenotype. In rare cases of otherwise classical MF, a CD4⁻ CD8⁺ mature T-cell phenotype may be seen (1). However, the prognosis of CD8⁺ CD56⁺ MF has not been well characterized. We reviewed the reported cases of CD8⁺ CD56⁺ MF and related cutaneous T-cell lymphomas, as shown in Table I (4–8). It is notable that all three cases presented as poikiloderma, a result of CD8⁺ CD56⁺ cells producing T-cell intracellular antigen-1 (TIA-1) and attacking epidermal cells. Since the three patients all responded

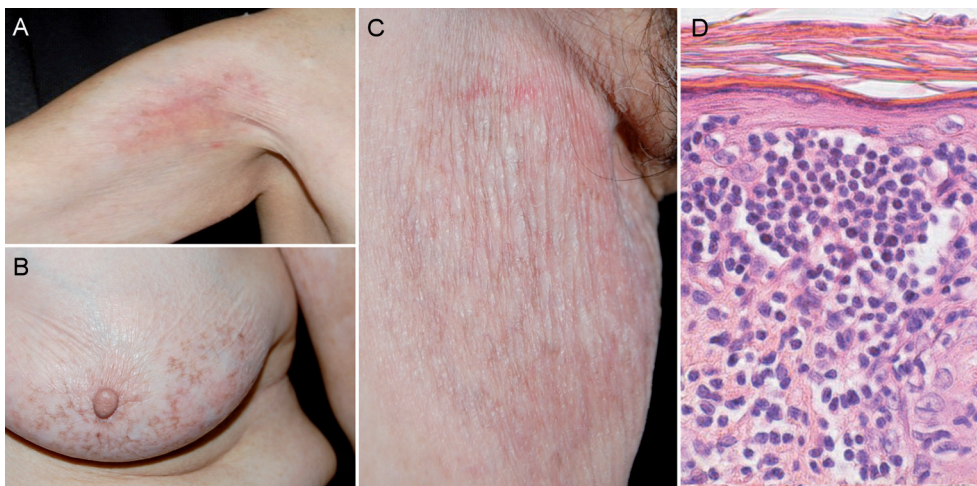


Fig. 1. Clinical appearance of patient, with poikilodermatous plaques on (A) upper arm, (B) left breast, and (C) right thigh. (D) Histopathology, showing epidermotropism and Pautrier's microabscesses. Haematoxylin and eosin stain; original magnification $\times 100$.

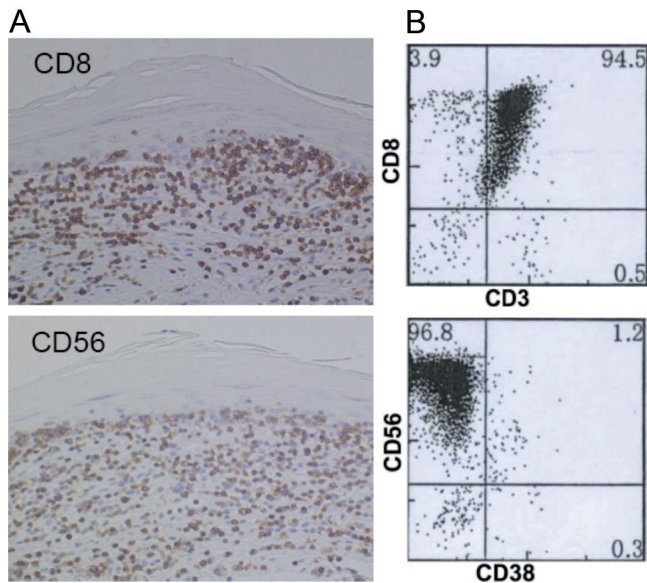


Fig. 2. (A) Immunohistochemical stain and (B) flow cytometry of skin-infiltrating cells from upper arm lesion showing atypical lymphocytes positive for CD3, CD8 and CD56, but negative for CD38.

fairly well to therapy, it seems that CD8⁺ CD56⁺ MF have the same clinical behaviour as CD4⁺ cases (1). As seen in our report, CD7 negativity might be associated with the indolent prognosis, because normal cytotoxic T cells express CD7. Likewise, CD8⁺ CD56⁺ Sézary syndrome appears to be non-aggressive, although only one case has been reported (5). Additionally, CD8⁺ CD56⁺ lymphomatoid papulosis exhibited a good

prognosis (6, 7). Our case confirmed that CD8⁺ CD56⁺ MF should not be considered as different from CD4⁺ MF and CD8⁺ MF.

REFERENCES

1. Willemze R, Jaffe ES, Burg G. WHO-EORTC classification for cutaneous lymphomas. *Blood* 2005; 105: 3768–3785.
2. Santucci M, Pimpinelli N, Massi D, Kadin ME, Meijer CJ, Müller-Hermelink HK, et al. Cytotoxic/natural killer cell cutaneous lymphomas: report of the EORTC cutaneous lymphoma task force workshop. *Cancer* 2003; 97: 610–627.
3. Diwan H, Ivan D. CD8-positive mycosis fungoides and primary cutaneous aggressive epidermotropic CD-8 positive cytotoxic T-cell lymphoma. *J Cutan Pathol* 2009; 36: 390–392.
4. Wain EM, Orchard GE, Mayou S, Atherton DJ, Misch KJ, Russell-Jones R. Mycosis fungoides with a CD56⁺ immunophenotype. *J Am Acad Dermatol* 2005; 53: 158–163.
5. Ohshima A, Tokura Y, Misawa J, Yagi H, Takigawa M. Erythrodermic cutaneous T-cell lymphoma with CD8⁺CD56⁺ leukemic T cells in a young woman. *Br J Dermatol* 2003; 149: 891–893.
6. Wu WM, Tsai HJ. Lymphomatoid papulosis histopathologically simulating angiocentric and cytotoxic T-cell lymphoma: a case report. *Am J Dermatopathol* 2004; 26: 133–135.
7. Flann S, Orchard GE, Wain EM, Russell-Jones R. Three cases of lymphomatoid papulosis with a CD56⁺ immunophenotype. *J Am Acad Dermatol* 2006; 55: 903–906.
8. Nikolaou VA, Papadavid E, Katsambas A, Stratigos AJ, Marinos L, Anagnostou D, et al. Clinical characteristics and course of cytotoxic variant of CD8⁺ cytotoxic variant of mycosis fungoides: a case series of seven patients. *Br J Dermatol* 2009; 161: 826–830.

Table I. Characteristics of reported cases of CD8⁺ CD56⁺ mycosis fungoides (MF) and related cutaneous T-cell lymphoma (CTCL)

Clinical diagnosis	Age (years)/Sex	Skin eruption	Treatment	Clinical course	Authors
Mycosis fungoides	45/F	Poikiloderma	Radiotherapy, topical steroid	Limited response	Wain, et al. (4)
	37/F	Poikiloderma, tumour	PUVA, excision	Good response	Wain, et al. (4)
	43/F	Poikiloderma	PUVA	Good response	Nikolaou, et al. (8)
	68/F	Poikiloderma	NB-UVB, oral PUVA	Good response	Our case
Erythrodermic CTCL	26/F	Erythroderma	Etoposide	Limited response	Ohshima, et al. (5)
Lymphomatoid papulosis	40/F	Necrotic papules	Methotrexate	Good response	Wu, et al. (6)
	29/M	Eroded papules	ND	ND	Flann, et al. (7)
	23/M	Itchy papules	Methotrexate	Good response	Flann, et al. (7)
	47/F	Crusted papules	Methotrexate PUVA	Limited response	Flann, et al. (7)

NB-UVB: narrowband ultraviolet B; PUVA: psoralen plus ultraviolet A; ND: not described.