

MINI-REVIEW AND DEBATE

Pleomorphic Ichthyosis: Proposed Name for a Heterogeneous Group of Congenital Ichthyoses with Phenotypic Shifting and Mild Residual Scaling

Anders VAHLQUIST*

Department of Medical Sciences, Uppsala University, Uppsala, Sweden

Congenital ichthyosis is often associated with typical neonatal phenotypes, “Collodion baby” and “Harlequin foetus”, later transforming into severe lamellar or erythrodermic ichthyosis. However, in a minority of cases the skin condition will improve spontaneously after birth, although slight scaling, xerosis, hypohidrosis and keratoderma usually persist. Some of these patients will eventually be diagnosed as suffering from self-improving collodion ichthyosis, ichthyosis prematurity syndrome, or other, even rarer, forms of ichthyosis also characterized by a phenotypic shift in early childhood. This paper summarizes newly described aetiologies for some of these diseases and discusses difficulties encountered when trying to distinguish them clinically from other types of autosomal recessive congenital ichthyosis. To remind health providers about this heterogeneous group of partially transient disorders of cornification, a new umbrella term, “pleomorphic ichthyosis”, is proposed. Key words: genodermatosis; disorders of keratinization; autosomal recessive disease.

(Accepted June 22, 2010.)

Acta Derm Venereol 2010; 90: 454–460.

Anders Vahlquist, Department of Medical Sciences, Uppsala University Hospital, SE-751 85 Uppsala, Sweden. E-mail: anders.vahlquist@medsci.uu.se

Autosomal recessive congenital ichthyosis (ARCI) is a collective name for a large group of inherited disorders of cornification, which are apparent at birth (1). The prevalence of ARCI is generally agreed to be approximately 1:100,000 (1). The two major subtypes of ARCI are lamellar ichthyosis (LI) and erythrodermic ichthyoses (EI), also known as non-bullous congenital ichthyosiform erythroderma (CIE) (Fig. 1a and b). Approximately 20–30% of patients with ARCI have milder skin symptoms (Fig. 1c), which experts may find incompatible with LI or EI, leading to the use of more awkward terms, such as non-LI/non-CIE, congenital ichthyosis with fine or focal

scaling (CIFS) and CI with mild scaling (CIMS) (1). In addition, there are many syndromic forms of congenital ichthyosis, e.g. neurocutaneous diseases, which are not discussed further here.

THE NEONATAL CLASSIFICATION OF ARCI

The usefulness of a clinical subclassification of ARCI is particularly obvious when examining a baby with ichthyosis for the first time, because a diagnostic laboratory test may take months to perform (if it is available at all) and parents will want a preliminary diagnosis, including some prognostic information. The most severe phenotype with the worst prognosis is Harlequin ichthyosis (HI), in which the baby is covered with an armour of hyperkeratosis, causing severe ectropion and eclabium, and high perinatal mortality (2). Later in life this very rare phenotype changes into a very severe EI/CIE with associated alopecia, growth retardation and malformed ears and digits, clearly separating HI-related, adult ARCI from “ordinary” LI and EI/CIE (Fig. 1d). A more common neonatal phenotype is “collodion baby”, which is characterized by a glue-like membrane covering the entire body surface. This membrane is usually shed within 2–3 weeks, revealing an underlying LI or EI. However, in some cases the skin becomes almost normal after a few weeks; a phenotype called “self-healing collodion baby” (SHCB) (3) (Fig. 1e), or preferably “self-improving congenital ichthyosis (SICI)” when encountered in children and adults, often with remaining signs of mild ichthyosis (4). Another self-improving condition is ichthyosis prematurity syndrome (IPS), in which babies are born with severe asphyxia and a massive hyperkeratosis on the scalp and some other parts of the body, which later develops into a mild follicular ichthyosis (“toad skin”) (5). IPS is sometimes associated with atopy and eosinophilia, but it is doubtful whether it represents a true syndrome with extracutaneous manifestations. A third variant of ARCI with phenotypic shift in childhood and characteristic skin symptoms thereafter is keratosis linearis with ichthyosis congenita and keratoderma (KLICK) (6). Yet another variable form is bathing-suit ichthyosis (BSI) in which large scales remain only in those skin areas with high skin temperature, e.g. under tight clothing (7); however, this subtype is due to TGM1 mutations and is closely related

*The Editor-in-Chief has not had the responsibility for this article and it has been handled fully by one of the Associate Editors who has made the decision for acceptance.

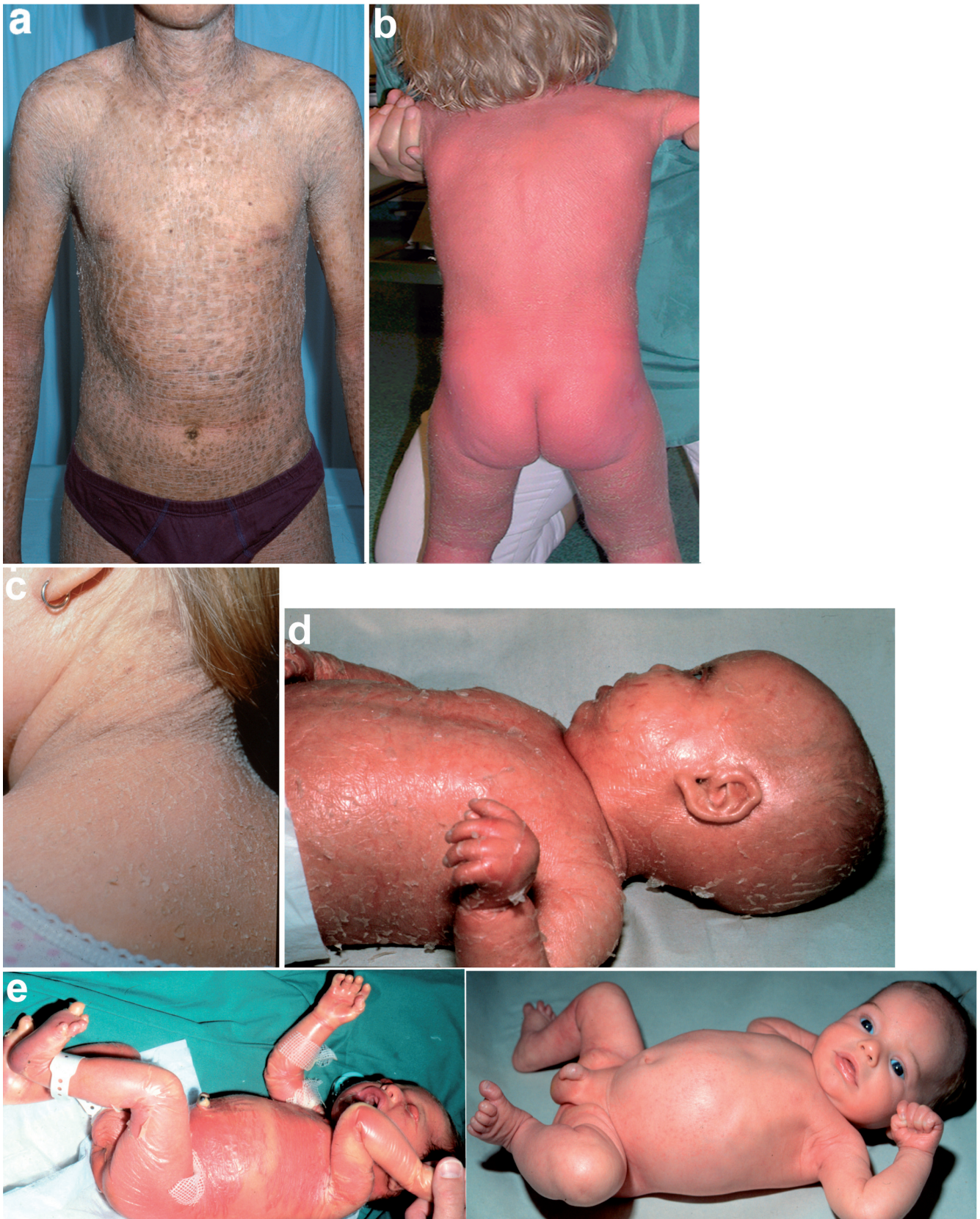

Fig. 1. Clinical characteristics of a) lamellar ichthyosis (LI), b) congenital ichthyosiform erythroderma (CIE) or erythrodermic ichthyosis (EI), c) congenital ichthyosis with fine or focal scaling (CIFS), d) Harelquin ichthyosis (HI)-related phenotype in infancy after shedding of the armour of scales covering the body at birth (note the malformed fingers and ear), and e) self-healing collodion baby (SHCB) soon after birth (*left*) and at 2 month of age (*right*). Later in life this boy showed dry skin and a very fine scaling on some parts of the body, i.e. self-improving collodion ichthyosis (SICI). From ref 4 with permission.

to LI (1), and thus outside the scope of this review. A final example, also not discussed here, is trichothiodystrophy (TTD), which, in most cases, represents a syndromic disease, although a small percentage of patients are born as collodion babies whose condition later changes into mild ichthyosis without the photosensitivity or extracutaneous features typical of other cases of TTD (8).

Needless to say, ARCI subtypes with highly variable features from birth to adulthood are particularly difficult to diagnose early without the aid of more sophisticated methods and may be missed in adult patients because of the limited skin involvement. A further nosological problem is the lack of established terminology to distinguish this group of heterogeneous and fairly mild diseases from other, more severe, subgroups of ARCI, such as LI, EI/CIE and HI.

The purpose of this review is to highlight recent aetiological findings for SICI, IPS and KLICK, beginning with a short overview of ARCI aetiopathogenesis in general, and ending with a proposal for a new umbrella term for ARCI diseases that are characterized by marked phenotypic shifting in early childhood and mild, non-LI/non-EI skin symptoms remaining into adulthood.

AETIOPATHOGENETIC SPECTRUM OF ARCI

ARCI is associated with mutations in several genes of importance for proper functioning of the intercellular lipid layer and cornified cell envelope. To date, eight genes are known to be incriminated in ARCI; *TGMI* (see refs in 9), *ABCA12* (10, 11), the two lipoxygenase genes *ALOXE3* and *ALOX12B* (12, 13), *CGI-58* (14), *Ichthyin* (15, 16) *CYP4F22* (17) and *SLC27* (18). Furthermore, linkage analysis has established at least two additional ARCI loci on chromosomes 12p11.2–q13 and 19p13.2–p13.1 (19, 20).

The most common cause of LI/CIE is inactivating mutations in the *TGMI* gene, which encodes transglutaminase-1, an enzyme that cross-links proteins in the cornified cell envelope (21). Other ARCI-associated genes encode enzymes or transport proteins involved in epidermal lipid metabolism, e.g. the lipoxygenase pathway producing metabolites essential for a proper deposition of lipids between the horny cells (22, 23). Interestingly, different types of mutations in one and the same gene may be associated with very different phenotypes. For example, whereas truncating mutations in *ABCA12* leading to a complete lack of the protein will cause HI (2, 11), less deleterious point mutations in the same gene will only reduce the function of *ABCA12* protein and cause milder forms of LI or EI (10).

Although ARCI is genetically heterogeneous, all diseases share a common pathogenic feature of defective epidermal barrier function (24). Irrespective of cause, such a defect elicits a cascade of homeostatic mechanisms aimed at repairing the skin barrier. In ARCI this is

a continuously ongoing process, which results in chronic hyperkeratosis, hyperproliferation and cutaneous inflammation, often presenting a greater problem to the patient than the barrier defect *per se*. It is noteworthy in this context that the removal of hyperkeratosis and scales is a purely symptomatic treatment, which may in fact worsen the underlying barrier defect in ARCI (25). It is hoped that, based on the results of recent genetic research, more pathogenesis-oriented treatments will soon be available. This also applies to SICI, IPS and KLICK, which are the focus of the following review.

SELF-IMPROVING COLLODION ICHTHYOSIS

In approximately 10–25% of all collodion babies the membrane is shed without residual signs of prominent ichthyosis, i.e. showing the characteristic SHCB/SICI phenotype (Fig. 1e) (3, 26). The first gene to be associated with this condition was *TGMI*; two unusual point mutations in *TGMI* reducing the enzyme activity *in utero* but not *in vivo* have been reported (27). Harting et al. (28) later described two American cases of SHCB/SICI with novel mutations in the *ALOX12B* gene. More recently, we studied the genotype-phenotype relationship in 15 Scandinavian cases (4). On DNA sequencing of 11 Swedish and 4 Danish patients, *ALOX12B* mutations were found in 8 cases, *ALOXE3* mutations in 3 cases, and *TGMI* mutation in just one case. In three patients we could not find mutations in the examined ARCI genes (*ALOX12B*, *ABCA12*, *ALOXE3*, *TGMI*, *ICHTHYIN* and *CYP4F22*), implying that the aetiology of SHCB/SICI involves additional gene loci. When examined at 2–37 years of age, all patients exhibited skin xerosis, fine or focal scaling (Fig. 1c), palmar hyperlinearity or keratoderma, and frequent occurrence of red cheeks, i.e. consistent with a mild persistent ichthyosis also described by Harting et al. (28). Interestingly, despite a mild ichthyosis, anhidrosis (and heat-intolerance) was reported by most of our patients, suggesting that sweat gland suppression is not directly related to the degree of hyperkeratosis.

Although the term SHCB is useful when describing a severe phenotype in newborn babies with a good prognosis, it is, for obvious reasons, not a suitable diagnosis when the patients grow older. Furthermore, the word “self-healing” spuriously implies that the patient’s skin will always look normal after the collodion has been shed. We therefore proposed an alternative name, “self-improving collodion ichthyosis (SICI)”, as a better term for all patients with the initial appearance of SHCB (4).

ICHTHYOSIS PREMATURETY SYNDROME

IPS is another self-improving condition that is relatively frequent in the Scandinavian population (5, 29), but has also been described from Italy and France (30, 31).

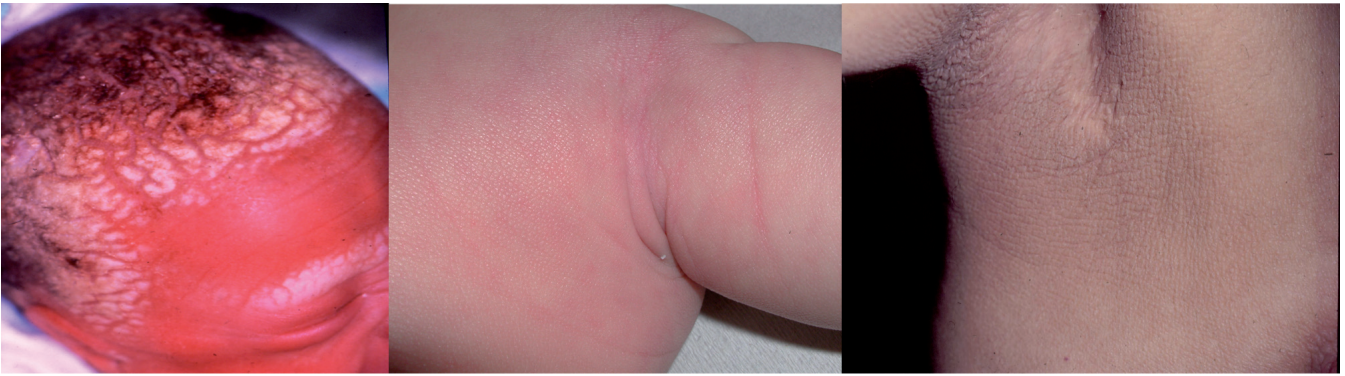

Fig. 2. Clinical characteristics of ichthyosis prematurity syndrome (IPS) soon after birth 6 weeks before term (*left*) and at 3 months of age showing a toad-like hyperkeratosis especially in the skin folds (*middle*). A similar appearance in the axillae of a 50-year-old man who was born with typical IPS (*right*). From refs 18 and 41 with permission.

Key features of IPS are complications in the second trimester of pregnancy, premature birth of a child with thick caseous epidermis especially on the scalp, respiratory complications (asphyxia) probably due to foetal aspiration of amniotic skin debris (seen on ultrasound!), and transient eosinophilia (Fig. 2). After a general recovery during the first months of life, patients will have only slight skin problems, in the form of a non-scaly ichthyosis, sometimes associated with mild atopic manifestations; however, the atopic diathesis might simply reflect a defective skin barrier and enhanced penetration of allergens, similar to atopy associated with ichthyosis vulgaris due to filaggrin mutations.

Several years ago it was reported that IPS, or ichthyosis congenita type IV according to electron microscopy classification (5), is associated with a specific gene locus (9q33.3–34.13) (29). We have recently shown that this locus contains the *SLC27* gene, encoding the fatty acid transport protein 4 (FATP4), which is absent in individuals with IPS, thus explaining an accumulation of abnormal lipid masses in the upper epidermis and a defective skin barrier (18). Skin cells derived from IPS patients also show reduced activity of very long chain fatty acids (VLCFA)-CoA synthetase and a specific reduction in the

incorporation of VLCFA into cellular lipids (18), indicating a dual function of FATP4 as both fat transporter and enzyme. The human phenotype is consistent with *Fatp4* deficiency in mice, characterized by a severe skin phenotype, a defective permeability barrier function and perturbed VLCFA metabolism (32, 33).

The exact reason for the spontaneous improvement of IPS soon after birth is unknown; hypothetically it might be related to an adaptation of the offspring to extra-uterine life, with increased expression of other genes that partially compensate for missing FATP4 in the skin.

KERATOSIS LINEARIS WITH ICHTHYOSIS CONGENITA AND KERATODERMA

KLICK (MIM #601952) is a rare disorder of keratinization of the skin, characterized by mild ichthyosis, sclerosing palmoplantar keratoderma with constricting bands around fingers, flexural deformities of fingers and keratotic papules in a linear manner on the flexural side of large joints (Fig. 3). Affected individuals are usually born with a generalized EI of mild to moderate type, which soon changes into a mild CIFS, but the linear lesions and keratodermas progress gradually

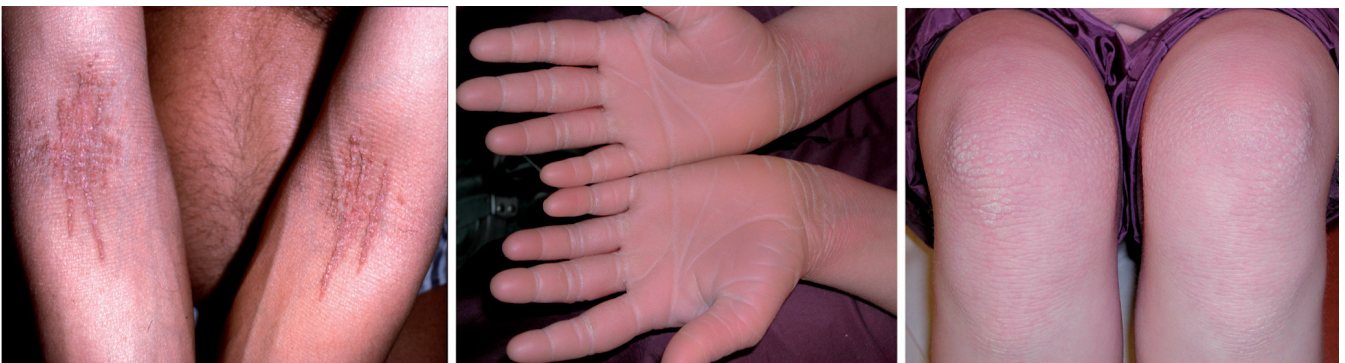

Fig. 3. Clinical characteristics of keratosis linearis, ichthyosis congenita, and keratoderma in a male aged 30 and in a woman aged 20 with mild ichthyosis on the extremities clearly accentuated on the knees and elbows. They were both born with generalized ichthyosis. From ref 6 with permission and from the author's files.

until becoming stable from late childhood and onwards. Histological examination of the skin shows hypertrophy and hyperplasia of the spinous, granular and corneal epidermal layers (6, 34); ultrastructurally the abundant keratohyaline granules are enlarged and abnormally shaped in differentiated keratinocytes (6).

KLICK shares some features with striate palmoplantar keratoderma (MIM #148700), lorincrin keratoderma, and Vohwinkel's syndrome (MIM #604117, #124500). All these phenotypically related disorders are caused by mutations in genes involved in intercellular communication (e.g. connexins) or formation of lipids and cornified envelopes (e.g. lorincrin) (35–37), whereas KLICK is clearly unrelated to these genes. By studying a large kindred of Spanish KLICK patients, as well as isolated cases from Scandinavia, Holland and Italy, we recently found a DNA locus with high lod score on chromosome 13q (38). Sequence analysis of 10 candidate genes revealed a single-nucleotide deletion in the region 5' of the proteasome maturation protein (POMP) gene, in all probands. POMP is a ubiquitously expressed protein and functions as a chaperone for proteasome maturation (39). Immunohistochemical analysis revealed an altered epidermal distribution of POMP and the two proteasome subunit proteins $\alpha 7$ and $\beta 5$ in KLICK patients (38). Our results suggest that a single nucleotide deletion in the 5' UTR (untranslated region) of *POMP* results in defective protein degradation in epidermis, explaining the perturbed expression of filaggrin, involucrin and other proteins of importance for terminal differentiation of keratinocytes (38). To the best of our knowledge there are no previous reports of a skin disorder caused by proteasome abnormality.

PROPOSAL FOR A NEW UMBRELLA TERM: PLEOMORPHIC ICHTHYOSIS

Clearly, the diseases described above do not fit into any of the accepted three major subgroups of ARCI, HI, LI and EI/CIE, which are all characterized by more severe and generalized skin symptoms. As mentioned above, no consensus has been reached about a definition or a name for a mild subgroup of ARCI (1), although acronyms such as non-LI/non-CIE, CIFS, CIMS have been used interchangeably in the past (1, 41, 42, H. Traupe, personal communication).

One way of further arguing for a new subgrouping is to illustrate the phenotypic spectrum of patients with ARCI in a graph in which the severity of erythema and scaling are plotted as x and y axes, respectively (Fig. 4). In this graph, LI, EI/CIE and HI (or HI-related in children and adults born as HI) are readily discernible as circles with partially overlapping boundaries. The overlapping is thought to represent "difficult-to-classify" patients or an influence of season and therapy on a phenotype that is shifting. The lower left circle in

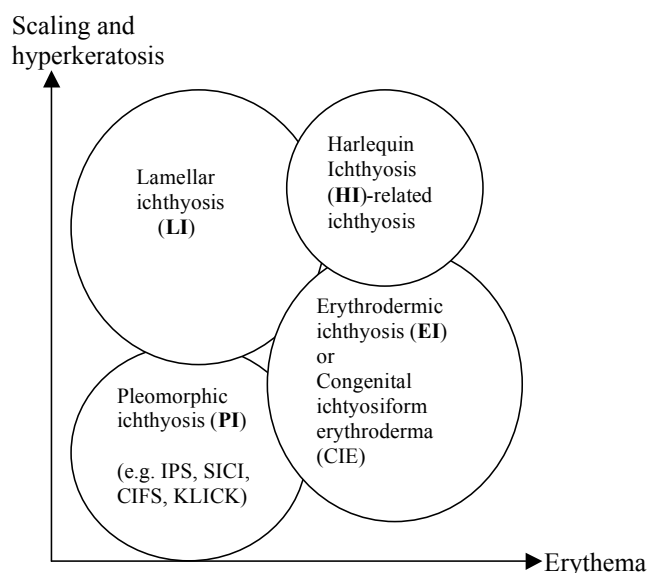


Fig. 4. Proposed distinction of four phenotypic variants of non-syndromic autosomal recessive congenital ichthyosis (ARCI) based on the extent of scaling/hyperkeratosis and erythema as appearing in late childhood or adulthood. Harlequin ichthyosis is by definition a neonatal phenotype but these patients later develop a mature phenotype (HI-related) which is more severe than lamellar ichthyosis (LI) or congenital ichthyosiform erythroderma/erythrodermic ichthyosis (CIE/EI). *Pleomorphic ichthyosis* is a new term for several different diseases with a common feature of mild congenital ichthyosis with fine scaling (CIFS) remaining after initially severe skin symptoms in early childhood. IPS: ichthyosis prematurity syndrome; KLICK: keratosis linearis with ichthyosis congenita and keratoderma.

the diagram represents patients with mild or focal skin symptoms remaining in adulthood (i.e. non-LI/non-CIE, CIFS or CIMS). Needless-to-say, most patients with SICI, IPS and KLICK, and at least some cases of TTD and BSI, will fall into this category once they have passed the infancy period. Since a fluctuating course and a multitude of different aetiologies are also characteristic features of these diseases, an appropriate umbrella term appears to be pleomorphic ichthyosis (PI). The Greek adjective *pleomorphous* (*pleon*, many) has to the best of my knowledge never been used before in connection with ichthyosis, but is established in other medical terms, e.g. pleomorphic adenomas, highlighting a complex tissue composition in a tumour.

A subclassification of ARCI into HI, EI, LI and now also PI might be useful, e.g. in clinical studies where the phenotypic spectrum of the patients needs to be communicated or, in the individual case, when a decision has to be made about which gene tests should be prioritized in a diagnostic work-up (each subgroup has a particular aetiological spectrum).

At least in Scandinavia, these four subtypes of ARCI appear to be numerically related as: LI > EI > PI >> HI (42). The combined prevalence of PI appears to be in the order of 1:500,000 (AV, data on file). However, this figure is probably an underestimate, because some patients with PI will never be correctly diagnosed due

to the mostly transient nature of their skin problems. For example, an elderly person with no detailed knowledge about his or her neonatal history is likely never to be correctly diagnosed as SICI or IPS. Also, when a baby is born in a smaller hospital and there is no dermatological expertise available, a thin collodion membrane associated with SHCB may be misinterpreted as post-term skin dryness or debris of vernix caseosa remaining on the skin. In addition, male infants with x-linked recessive ichthyosis sometimes display a thin collodion membrane at birth that may confuse diagnosis (43).

By defining subsets of patients with ARCI with different phenotype and genotype, such as SICI, IPS and KLICK, it will be easier to make a clinically useful classification of congenital ichthyosis. From a practical point of view, however, when seeing a case of severe neonatal ichthyosis it is essential to make a quick preliminary diagnosis and when suspecting the PI subtype always remembering a good chance of improvement.

Within the PI group, SICI undoubtedly predominates over IPS, which in Scandinavia is more commonly recognized than KLICK (AV, data on file), although this probably reflects a founder effect (29). Perhaps in the future there will be other followers added to the PI family; for example, adult CIFS patients without severe neonatal symptoms and where no aetiology has yet been established.

CONCLUSION

A continued search for new ARCI aetiologies will no doubt increase our understanding of both the pathogenesis of ichthyosis and the biology of human skin. From this perspective, the recent discoveries that IPS is caused by deficiency of a member of the FATP family, and that KLICK is due to a defect in the proteasome maturation protein (POMP), emphasize the importance of fatty acid metabolism and programmed protein degradation, respectively, for normal human epidermal integrity.

In addition, elucidating the mechanisms behind phenotypic shifts in PI might be rewarding in terms of finding new therapeutic approaches to ARCI. For example, in the case of TGM-associated SICI, a changed conformation of the mutated protein due to temperature- or pressure-dependent processes has already been established as a cause of increased enzyme activity (27, 40, 44). A still hypothetical explanation in the case of FATP-4 and lipoxygenases is that a programmed maturation of compensatory mechanisms not expressed *in utero* can substitute for the missing protein in the epidermis later in life.

Without doubt, the aetiological and phenotypic heterogeneity and ample overlapping between different subsets of ARCI represents a diagnostic challenge. It is hoped that the introduction of *pleomorphic ichthyosis* as an umbrella term will facilitate communication about

different ARCI diagnoses and perhaps the combination of acronyms HI, EI, LI, and PI will HELP the clinician to remember the four major phenotypic variants of non-syndromic ARCI.

ACKNOWLEDGEMENTS

This paper represents the author's personal opinions. Valuable discussions with the Scandinavian genodermatosis team and individual members of the Ichthyosis Consensus group and the GENESKIN project are gratefully acknowledged.

REFERENCES

- Oji V, Tadani G, Akiyama M, Blanchet-Bardon C, Bodemer C, Bourrat E, et al. Revised nomenclature and classification of inherited ichthyosis: results of the first Ichthyosis Consensus Conference in Sorèze 2009. *J Am Acad Dermatol* 2010 Jul 17 (Epub ahead of print).
- Akiyama M. Harlequin ichthyosis and other autosomal recessive ichthyoses: the underlying genetic defects and pathomechanisms. *J Derm Sci* 2006; 42: 83–89.
- Frenk E, de Techtermann F. Self-healing collodion baby: evidence for autosomal recessive inheritance. *Pediatr Dermatol* 1992; 9: 95–97.
- Vahlquist A, Bygum A, Gånemo A, Virtanen M, Hellstrom-Pigg M, Strauss G, et al. Genotypic and clinical spectrum of self-improving collodion ichthyosis: ALOX12, ALOXE3 and TGM1 mutations in Scandinavian patients. *J Invest Dermatol* 2010; 130: 438–443.
- Niemi KM, Kuokkanen K, Kanerva L, Ignatius J. Recessive ichthyosis congenita type IV. *Am J Dermatopathol* 1993; 15: 224–228.
- Vahlquist A, Ponten F, Pettersson A. Keratosis linearis with ichthyosis congenita and sclerosing keratoderma (KLICK-syndrome): a rare, autosomal recessive disorder of keratohyaline formation? *Acta Derm Venereol* 1997; 77: 225–227.
- Oji V, Hautiier JM, Ahvazi B, Hausser I, Aufenvenne K, Walker T, et al. Bathing suit ichthyosis is caused by transglutaminase-1 deficiency: evidence for a temperature-sensitive phenotype. *Hum Mol Gene* 2006; 15: 3083–3097.
- Morice-Picard F, Cario-André M, Rezvani H, Lacombe D, Sarasin A, Taïeb A. New clinico-genetic classification of trichothiodystrophy. *Am J Med Genet A* 2009; 149: 2020–2030.
- Farasat S, Wei MH, Herman M, Liewehr DJ, Steinberg SM, Bale SJ, et al. Novel transglutaminase-1 mutations and genotype-phenotype investigations of 104 patients with autosomal recessive congenital ichthyosis in the USA. *J Med Genet* 2009; 46: 103–111.
- Lefevre C, Audebert S, Jobard F, Bouadjar B, Lakhdar H, Boughdene-Stambouli O, et al. Mutations in the transporter ABCA12 are associated with lamellar ichthyosis type 2. *Hum Mol Gene* 2003; 12: 2369–2378.
- Kelsell DP, Norgett EE, Unsworth H, Teh MT, Cullup T, Mein CA, et al. Mutations in ABCA12 underlie the severe congenital skin disease harlequin ichthyosis. *Am J Hum Gene* 2005; 76: 794–803.
- Jobard F, Lefevre C, Karaduman A, Blanchet-Bardon C, Emre S, Weissenbach J, et al. Lipoxygenase-3 (ALOXE3) and 12(R)-lipoxygenase (ALOX12B) are mutated in non-bullous congenital ichthyosiform erythroderma (NCIE) linked to chromosome 17p13.1. *Hum Mol Gene* 2002; 11: 107–113.

13. Eckl KM, de Juanes S, Kurtenbach J, Natebus M, Lugassy J, Oji V, et al. Molecular analysis of 250 patients with autosomal recessive congenital ichthyosis: evidence for mutation hotspots in ALOXE3 and allelic heterogeneity in ALOX12B. *J Invest Dermatol* 2009; 129: 1421–1428.
14. Lefevre C, Jobard F, Caux F, Bouadjar B, Karaduman A, Heilig R, et al. Mutations in CGI-58, the gene encoding a new protein of the esterase/lipase/thioesterase subfamily, in Chanarin-Dorfman syndrome. *Am J Hum Genet* 2001; 69: 1002–1012.
15. Lefevre C, Bouadjar B, Karaduman A, Jobard F, Saker S, Ozguc M, et al. Mutations in ichthyin a new gene on chromosome 5q33 in a new form of autosomal recessive congenital ichthyosis. *Hum Mol Genet* 2004; 13: 2473–2482.
16. Dahlqvist J, Klar J, Hausser I, Anton-Lamprecht I, Pigg MH, Gedde-Dahl T, Jr, et al. Congenital ichthyosis: mutations in ichthyin are associated with specific structural abnormalities in the granular layer of epidermis. *J Med Genet* 2007; 44: 615–620.
17. Lefevre C, Bouadjar B, Ferrand V, Tadini G, Megarbane A, Lathrop M, et al. Mutations in a new cytochrome P450 gene in lamellar ichthyosis type 3. *Hum Mol Genet* 2006; 15: 767–776.
18. Klar J, Schweiger M, Zimmerman R, Zechner R, Li H, Torma H, et al. Mutations in the fatty acid transport protein 4 gene cause the ichthyosis prematurity syndrome. *Am J Hum Genet* 2009; 85: 248–253.
19. Mizrahi-Koren M, Geiger D, Indelman M, Bitterman-Deutch O, Bergman R, Sprecher E. Identification of a novel locus associated with congenital recessive ichthyosis on 12p11.2-q13. *J Invest Dermatol* 2005; 125: 456–462.
20. Virolainen E, Wessman M, Hovatta I, Niemi KM, Ignatius J, Kere J, et al. Assignment of a novel locus for autosomal recessive congenital ichthyosis to chromosome 19p13.1-p13.2. *Am J Hum Genet* 2000; 66: 1132–1137.
21. Russell LJ, DiGiovanna JJ, Rogers GR, Steinert PM, Hashem N, Compton JG, et al. Mutations in the gene for transglutaminase 1 in autosomal recessive lamellar ichthyosis. *Nat Genet* 1995; 9: 279–283.
22. Brash AR, Yu Z, Boeglin WE, Schneider C. The heparin connection in the epidermis. *FEBS J* 2007; 274: 3494–3502.
23. Epp N, Furstenberger G, Muller K, de Juanes S, Leitges M, Hausser I, et al. 12R-lipoxygenase deficiency disrupts epidermal barrier function. *J Cell Biol* 2007; 177: 173–182.
24. Schmuth M, Gruber R, Elias PM, Williams ML. Ichthyosis update: towards a function-driven model of pathogenesis of the disorders of cornification and the role of corneocyte proteins in these disorders. *Adv Dermatol* 2007; 23: 231–256.
25. Vahlquist A, Ganemo A, Virtanen M. Congenital ichthyosis: an overview of current and emerging therapies. *Acta Derm Venereol* 2008; 88: 4–14.
26. Van Gysel D, Lijnen RL, Moekti SS, de Laat PC, Oranje AP. Collodion baby: a follow-up study of 17 cases. *J Eur Acad Dermatol Venereol* 2002; 16: 472–475.
27. Raghunath M, Hennies HC, Ahvazi B, Vogel M, Reis A, Steinert PM, et al. Self-healing collodion baby: a dynamic phenotype explained by a particular transglutaminase-1 mutation. *J Invest Dermatol* 2003; 120: 224–228.
28. Harting M, Brunetti-Pierri N, Chan CS, Kirby J, Dishop MK, Richard G, et al. Self-healing collodion membrane and mild nonbullous congenital ichthyosiform erythroderma due to 2 novel mutations in the ALOX12B gene. *Arch Dermatol* 2008; 144: 351–356.
29. Melin M, Klar J, Jr Gedde-Dahl T, Fredriksson R, Hausser I, Brandrup F, et al. A founder mutation for ichthyosis prematurity syndrome restricted to 76 kb by haplotype association. *J Hum Genet* 2006; 51: 864–871.
30. Brusasco A, Gelmetti C, Tadini G, Caputo R. Ichthyosis congenita type IV: a new case resembling mastocytosis. *Br J Dermatol* 1997; 136: 377–379.
31. Léauté-Labreze C, Boralevi F, Cony M, Maleville J, Lacombe D, Surleve-Bazeille J-E, et al. Self-healing congenital verruciform hyperkeratosis. *Am J Med Genet* 2004; 130A: 303–306.
32. Herrmann T, van der Hoeven F, Grone HJ, Stewart AF, Langbein L, Kaiser I, et al. Mice with targeted disruption of the fatty acid transport protein 4 (Fatp 4, Slc27a4) gene show features of lethal restrictive dermopathy. *J Cell Biol* 2003; 161: 1105–1115.
33. Moulson CL, Lin MH, White JM, Newberry EP, Davidson NO, Miner JH. Keratinocyte-specific expression of fatty acid transport protein 4 rescues the wrinkle-free phenotype in Slc27a4/Fatp4 mutant mice. *J Biol Chem* 2007; 282: 15912–15920.
34. Pujol RM, Moreno A, Alomar A, de Moragas JM. Congenital ichthyosiform dermatosis with linear keratotic flexural papules and sclerosing palmoplantar keratoderma. *Arch Dermatol* 1989; 125: 103–106.
35. Rickman L, Simrak D, Stevens HP, Hunt DM, King IA, Bryant SP, et al. N-terminal deletion in a desmosomal cadherin causes the autosomal dominant skin disease striate palmoplantar keratoderma. *Hum Mol Genet* 1999; 8: 971–976.
36. Maestrini E, Monaco AP, McGrath JA, Ishida-Yamamoto A, Camisa C, Hovnanian A, et al. A molecular defect in loricrin, the major component of the cornified cell envelope, underlies Vohwinkel's syndrome. *Nat Genet* 1996; 13: 70–77.
37. Maestrini E, Korge BP, Ocana-Sierra J, Calzolari E, Cambiagli S, Scudder PM, et al. A missense mutation in connexin26, D66H, causes mutilating keratoderma with sensorineural deafness (Vohwinkel's syndrome) in three unrelated families. *Hum Mol Genet* 1999; 8: 1237–1243.
38. Dahlqvist J, Klar J, Tiwari N, Schuster J, Törmä H, Pujol R, et al. A single-nucleotide deletion in the POMP 5' UTR causes a transcriptional switch and altered epidermal proteasome distribution in KLICK genodermatosis. *Am J Hum Genet* 2010; 86: 596–603.
39. Fricke B, Heink S, Steffen J, Kloetzel PM, Kruger E. The proteasome maturation protein POMP facilitates major steps of 20S proteasome formation at the endoplasmic reticulum. *EMBO Rep* 2007; 8: 1170–1175.
40. Aufenvenne K, Oji V, Walker T, Becker-Pauly C, Hennies HC, Stöcker W, et al. Transglutaminase-1 and bathing suit ichthyosis: Molecular analysis of gene/environment interactions. *J Invest Dermatol* 2009; 129: 2068–2071.
41. Vahlquist A, Gånemo A, Pigg M, Virtanen M, Westermark P. The clinical spectrum of congenital ichthyosis in Sweden: a review of 127 cases. *Acta Derm Venereol* 2003; Suppl 213: 34–47.
42. Gånemo A, Pigg M, Virtanen M, Kukk T, Raudsepp H, Rossman-Ringdahl I, et al. Autosomal recessive congenital ichthyosis in Sweden and Estonia: clinical, genetic and ultrastructural findings in eighty-three patients. *Acta Derm Venereol* 2003; 83: 24–30.
43. Hernandez-Martin A, Gonzalez-Sarmiento R, De Unamuno P. X-linked ichthyosis: an update. *Br J Dermatol* 1999; 141: 617–627.
44. Akiyama M, Shimizu H. An update on molecular aspects of the non-syndromic ichthyoses. *Exp Dermatol* 2008; 17: 373–382.