

## CLINICAL REPORT

# Localized Linear IgA/IgG Bullous Dermatitis

Satoko SHIMIZU<sup>1</sup>, Ken NATSUGA<sup>2</sup>, Satoru SHINKUMA<sup>2</sup>, Chikako YASUI<sup>1</sup>, Kikuo TSUCHIYA<sup>1</sup> and Hiroshi SHIMIZU<sup>2</sup>  
Departments of Dermatology, <sup>1</sup>Sapporo City General Hospital and <sup>2</sup>Hokkaido University Graduate School of Medicine, Sapporo, Japan

**Linear IgA/IgG bullous dermatosis (LAGBD) is an autoimmune blistering disease characterized by the local accumulation of IgA- and IgG-class anti-basement membrane autoantibodies. It typically presents as a generalized pruritic vesiculobullous eruption. No cases of localized LAGBD have yet been reported. We report a case of a 78-year-old man with LAGBD localized to the perianal area. The patient complained of suffering from persistent ulcers around the anus for more than 3 years. Physical examination revealed several blisters and ulcers up to 2-cm in diameter around the anus. No lesions were found elsewhere on the body. Histological analysis of a skin biopsy revealed subepidermal blistering, while direct immunofluorescence showed the linear deposition of IgA and IgG antibodies at the dermoepidermal junction. Indirect immunofluorescence of normal human skin whose layers had been separated using 1M NaCl showed the binding of both IgA and IgG to the epidermal side. Immunoblotting demonstrated the presence of circulating IgA and IgG autoantibodies that bound to a 120-kDa protein. This is the first case of localized LAGBD whose skin lesions were restricted to the perianal region. Key words: Linear IgA/IgG bullous dermatosis; linear IgA bullous dermatosis; bullous disease; BP180; collagen XVII; immunoblotting.**

(Accepted July 20, 2010.)

Acta Derm Venereol 2010; 90: 621–624.

Dr Satoko Shimizu, Department of Dermatology, Sapporo City General Hospital, North 11, West 13, Chuo-Ku, Sapporo 060-0011, Japan. E-mail: rxel0376@nifty.com

Linear IgA bullous dermatosis (LABD) is an autoimmune blistering disease characterized by subepidermal blisters and linear deposition of IgA autoantibodies at the dermoepidermal junction (1). In LABD, IgA autoantibodies most commonly recognize a 120-kDa or 97-kDa soluble ectodomain of collagen XVII or BP180 (2). Recently, linear IgA/IgG bullous dermatosis (LAGBD) was designated a subepidermal blistering disease in which linear deposition of both IgA and IgG anti-basement membrane autoantibodies occurs. It comprises a heterogeneous group of diseases, with the majority of cases being treated as a subgroup of LABD (3). Clinical features of both LAGBD and LABD vary. They usually present as annular vesiculobullous lesions over the whole body. Several

cases of localized LABD have been described (4–7). In contrast, no cases of localized linear IgA/IgG bullous dermatosis (LAGBD) have yet been reported.

We herein describe a case of localized LAGBD in which the location of the lesions had been restricted for more than 3 years.

## CASE REPORT

A 78-year-old man visited us complaining of a 3-year history of a perianal skin lesions. Topical steroid cream had not improved his condition. His medical history included stomach cancer (stage 1) and he had been treated for almost 10 years with a range of medicines, included teprenone, ursodeoxycholic acid and trimebutine maleate.

Physical examination revealed several ulcers and blisters on a well-demarcated, 5-cm plaque around the anus (Fig. 1). No skin lesions had appeared elsewhere on his body during the previous more than 3 years and the oral and ocular mucosae were not affected. Pruritus was absent, but defecation was painful. The rectal mucosa was unaffected and anal function was normal. A full blood count and tests of liver and renal function revealed no significant abnormalities, although the patient's HbA1c level was slightly raised (6.0%; normal range 4.3–5.8%).

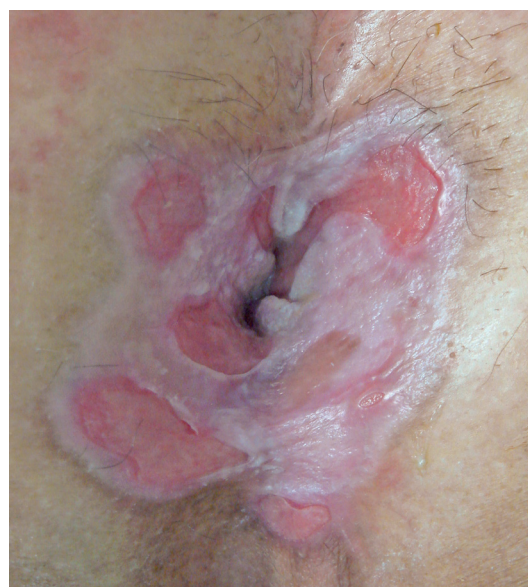

Fig. 1. Clinical manifestation. Ulcers on a well-demarcated plaque around the anus.

A biopsy was taken from the edge of the skin lesion. Histopathological analysis revealed subepidermal blistering and infiltration by lymphocytes, as well as neutrophils and eosinophils (Fig. 2a). Direct immunofluorescence (IF) analysis of lesional skin showed marked deposition of IgA (Fig. 2b), IgG (Fig. 2c) and C<sub>3</sub> at the dermo-epidermal junction. Indirect IF using 1M NaCl split human skin demonstrated whose layers had been separated with the binding of both IgA and IgG class autoantibodies to the epidermal side of the dermoepidermal junction. No dermal binding was observed. Epidermal extracts of normal human skin, supernatants of cultured HaCaT cells and recombinant proteins (NC16A and the C-terminal domain of BP180) were prepared as described previously (8–11) and used in immunoblot analysis of IgA and IgG class antibodies. While the patient's serum failed to react with 180- and 230-kDa antigens in epidermal extracts of normal human skin (Fig. 3a), it carried IgA and IgG class autoantibodies that bound to a 120-kDa protein in concentrated supernatants of cultured HaCaT cells (Fig. 3b). Immunoblotting with the recombinant NC16A domain of BP180 produced no specific binding (Fig. 3c). Further immunoblotting revealed that the patient's serum contained IgG, but not IgA, antibodies specific for the recombinant C-terminal domain of BP180 (BP915) (Fig. 3d). Based on these observations, we diagnosed the patient with LAGBD. Within 2 weeks of starting oral prednisolone treatment (0.5 mg/kg per day), the formation of new lesions ceased. When, however, the prednisolone dose was tapered to 0.1 mg/kg daily, new lesions again began to form. We therefore administered dapsons and gradually tapered the prednisolone dose. No new lesions appeared during 6 months of treatment with dapsons (25 mg daily).

## DISCUSSION

LAGBD and LABD typically present as a generalized pruritic vesiculobullous eruption. Although 8 cases of localized LABD have been reported (4–7, 12–15), no cases of localized LAGBD have been described. We believe this to be the first case of localized LAGBD whose skin lesions were restricted to the perianal area.

LAGBD comprises a heterogeneous group of diseases characterized by subepidermal blistering and the specific binding of IgG and IgA antibodies to the epidermal basement membrane (3). Most patients carry autoantibodies against 97-/120-kDa antigens. Some, however, carry autoantibodies against a 230-kDa antigen, as well as additional, as yet uncharacterized epidermal antigens (3, 16). Some cases of LAGBD have been reported as LABD, even though they satisfy the criteria for diagnosis of LAGBD (17). Recent immunoserological studies detected circulating IgA and IgG autoantibodies specific for certain epitopes of BP180 in bullous pemphigoid and LABD patients (18, 19). These findings suggest that there may be considerable overlap between bullous pemphigoid, LABD and LAGBD. In only a few cases of LAGBD have clinical characteristics been described in detail. Most of these displayed a vesiculobullous appearance similar to that of LABD, and were effectively controlled with low-dose prednisolone, dapsons or sulfapyridine (16). More cases are needed to clarify the clinical differences between these disease categories.

The present case carried circulating IgA and IgG antibodies that bound to the 120-kDa soluble ectodomain of BP180. IgG class antibodies also reacted with BP915, the recombinant C-terminal domain of BP180,

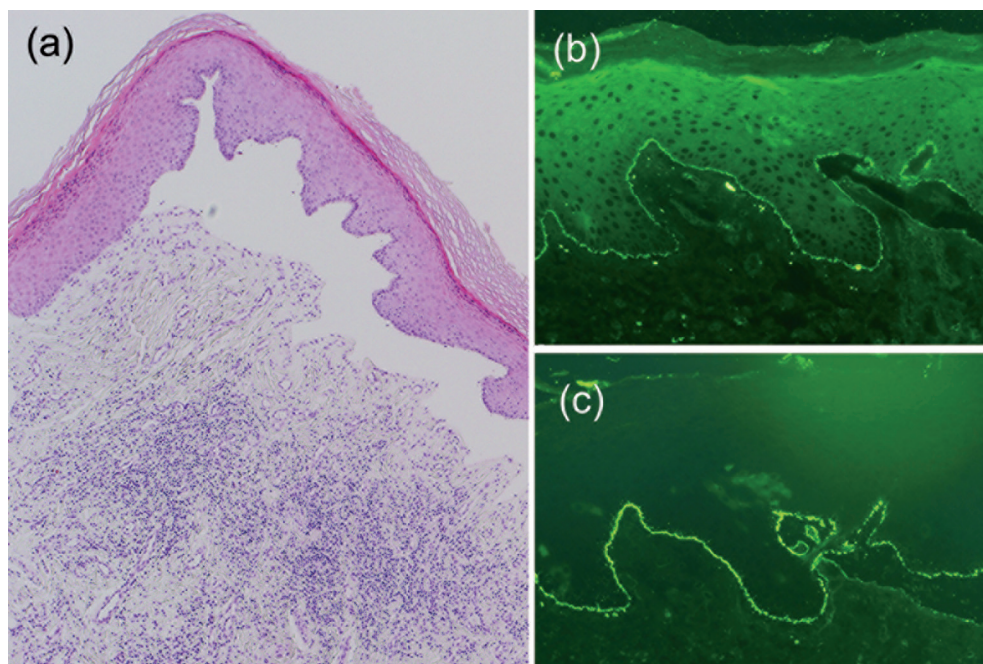


Fig. 2. (a) Biopsy of lesional skin revealed subepidermal blistering and lymphocytic infiltration. (Haematoxylin&Eosin, original magnification  $\times 100$ ). (b, c) Direct immunofluorescence analysis of a lesional skin biopsy. Linear deposition of IgA (b) and (c) IgG at the dermoepidermal junction.



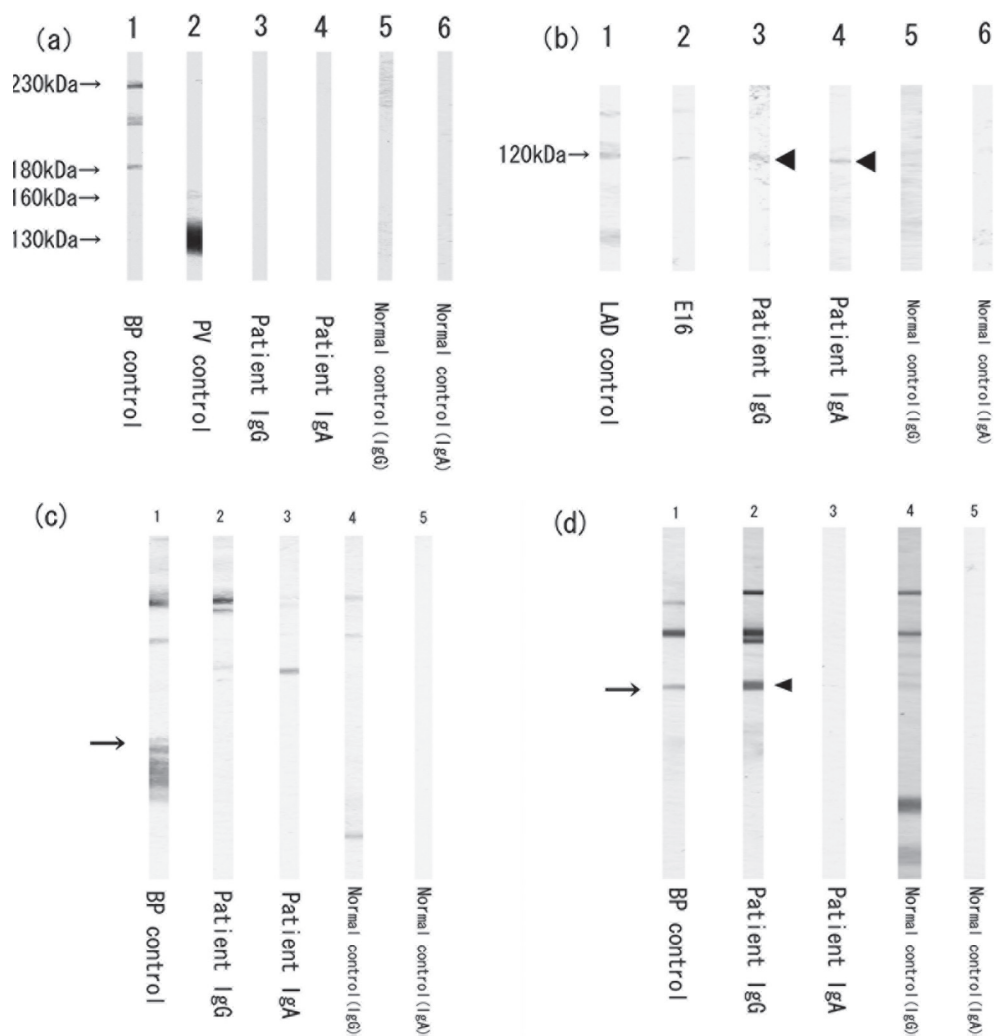


Fig. 3. (a) Immunoblotting using normal human epidermal extracts. Control bullous pemphigoid (BP) serum (lane 1) reacted with 180- and 230-kDa antigens. Control pemphigus vulgaris (PV) serum (lane 2) reacted with 130- and 160-kDa antigens. The patient's serum (lanes 3 and 4) and normal controls (lanes 5 and 6) showed no reactivity. (b) Immunoblotting using conditioned medium of cultured HaCaT cells. Control linear IgA bullous dermatosis (LABD) serum (lane 1), E16 (a goat polyclonal antibody raised against the C-terminus of BP180; Santa Cruz) (lane 2), and the patient's IgG and IgA antibodies (lanes 3 and 4, arrowheads) reacted with a 120-kDa antigen. Normal control samples (lanes 5 and 6) showed no reactivity with the 120-kDa antigen. (c) Reactivity with the NC16A domain of BP180 (arrow) (lane 1). Patient IgA and IgG (lanes 2 and 3) and normal control (lanes 4 and 5) showed no reactivity in immunoblotting analyses. (d) Reactivity with BP915 (recombinant C-terminal domain of BP180). A bullous pemphigoid control (lane 1) and the patient's IgG (arrowhead) (lane 2) showed reactivity (lane 1, 2) in immunoblotting analyses. The patient's IgA (lane 3) and normal controls (lanes 4 and 5) showed no reactivity.

which is the protein that is primarily targeted in mucous membrane pemphigoid (MMP) (11). In a study by Georgi et al. (17) BP915 was bound by IgA in 44% of lamina lucida-type LABD serum samples tested and by IgG in 33% of such samples (17). The authors concluded that the C-terminus of BP180 represents the primary target on the BP180 ectodomain for both IgA and IgG antibodies in the serum of LABD patients (17). Healing with scarring is characteristic of MMP but it is also found in some lamina lucida-type LABD patients (17, 20). This clinical overlap may well be explained by overlap in the antigenic sites on the BP180 ectodomain targeted by autoantibodies.

In summary, we have described an unusual case of LAGBD localized to the perianal region for more than 3 years that reveals the heterogeneous nature of LAGBD. LAGBD should be considered when diagnosing the cause of perianal blistering.

#### ACKNOWLEDGEMENT

We thank Ms Yuko Hayakawa for her technical assistance.

The authors declare no conflict of interest.

#### REFERENCES

- Leonard JN, Haffenden GP, Ring NP, McMinn RM, Sidgwick A, Mowbray JF, et al. Linear IgA disease in adults. *Br J Dermatol* 1982; 107: 301–316.
- Zone JJ, Taylor TB, Meyer LJ, Petersen MJ. The 97 kDa linear IgA bullous disease antigen is identical to a portion of the extracellular domain of the 180 kDa bullous pemphigoid antigen, BPAg2. *J Invest Dermatol* 1998; 110: 207–210.
- Zone JJ, Pazderka Smith E, Powell D, Taylor TB, Smith JB, Meyer LJ. Antigenic specificity of antibodies from patients with linear basement membrane deposition of IgA. *Dermatology* 1994; 189 Suppl 1: 64–66.
- Condon C, Cotter P, Lyons JF. Localized linear IgA disease and platelet abnormalities. *Br J Dermatol* 1994; 131: 139–141.
- He C, Xu H, Xiao T, Geng L, Chen HD. Localized linear IgA dermatosis induced by UV light-treatment for herpes zoster. *Int J Dermatol* 2007; 46: 500–502.
- Yoneda K, Yokoi I, Demitsu T, Matsuda Y, Matsuoka Y, Miyamoto I, et al. Localized linear IgA disease showing contact dermatitis-like eruption. *Eur J Dermatol* 2007; 17: 339–340.
- Shimanovich I, Rose C, Sitaru C, Brocker EB, Zillikens D. Localized linear IgA disease induced by ampicillin/sulbactam. *J Am Acad Dermatol* 2004; 51: 95–98.
- Dmochowski M, Hashimoto T, Bhogal BS, Black MM, Zone

- JJ, Nishikawa T. Immunoblotting studies of linear IgA disease. *J Dermatol Sci* 1993; 6: 194–200.
9. Schacke H, Schumann H, Hammami-Hausli N, Raghunath M, Bruckner-Tuderman L. Two forms of collagen XVII in keratinocytes. A full-length transmembrane protein and a soluble ectodomain. *J Biol Chem* 1998; 273: 25937–25943.
  10. Zillikens D, Rose PA, Balding SD, Liu Z, Olague-Marchan M, Diaz LA, et al. Tight clustering of extracellular BP180 epitopes recognized by bullous pemphigoid autoantibodies. *J Invest Dermatol* 1997; 109: 573–579.
  11. Nie Z, Hashimoto T. IgA antibodies of cicatricial pemphigoid sera specifically react with C-terminus of BP180. *J Invest Dermatol* 1999; 112: 254–255.
  12. Cauza K, Hinterhuber G, Sterniczky B, Brugger K, Pieczkowski F, Karlhofer F, et al. Unusual clinical manifestation of linear IgA dermatosis: a report of two cases. *J Am Acad Dermatol* 2004; 51: S112–117.
  13. Benbenisty KM, Bowman PH, Davis LS. Localized linear IgA disease responding to colchicine. *Int J Dermatol* 2002; 41: 56–58.
  14. Walsh SN, Kerchner K, Sanguenza OP. Localized palmar vancomycin-induced linear IgA bullous dermatosis occurring at supratherapeutic levels. *Arch Dermatol* 2009; 145: 603–604.
  15. Gamo R, Aguilar A, Gonzalez-Valle O, Houmani M, Martin L, Gallego MA. Localized linear IgA disease associated with monoclonal gammopathy of undetermined significance. *J Eur Acad Dermatol Venereol* 2007; 21: 544–545.
  16. Chan LS, Traczyk T, Taylor TB, Eramo LR, Woodley DT, Zone JJ. Linear IgA bullous dermatosis. Characterization of a subset of patients with concurrent IgA and IgG anti-basement membrane autoantibodies. *Arch Dermatol* 1995; 131: 1432–1437.
  17. Georgi M, Scheckenbach C, Kromminga A, Partscht K, Messer G, Brocker EB, et al. Mapping of epitopes on the BP180 ectodomain targeted by IgA and IgG autoantibodies in patients with the lamina lucida-type of linear IgA disease. *Arch Dermatol Res* 2001; 293: 109–114.
  18. Kromminga A, Scheckenbach C, Georgi M, Hagel C, Arndt R, Christophers E, et al. Patients with bullous pemphigoid and linear IgA disease show a dual IgA and IgG autoimmune response to BP180. *J Autoimmun* 2000; 15: 293–300.
  19. Horiguchi Y, Ikoma A, Sakai R, Masatsugu A, Ohta M, Hashimoto T. Linear IgA dermatosis: report of an infantile case and analysis of 213 cases in Japan. *J Dermatol* 2008; 35: 737–743.
  20. Wojnarowska F, Marsden RA, Bhogal B, Black MM. Chronic bullous disease of childhood, childhood cicatricial pemphigoid, and linear IgA disease of adults. A comparative study demonstrating clinical and immunopathologic overlap. *J Am Acad Dermatol* 1988; 19: 792–805.