

## QUIZ SECTION

### Hyperpigmented Forearms and Nail: A Quiz

Dimitrios Kalabalikis<sup>1</sup>, Aikaterini Patsatsi<sup>1\*</sup>, Myrto-Georgia Trakatelli<sup>1</sup>, Paraskevi Pitsari<sup>1</sup>, Ioannis Efstratiou<sup>2</sup> and Dimitrios Sotiriadis<sup>1</sup>

<sup>1</sup>2<sup>nd</sup> Dermatologic Clinic, Aristotle University of Thessaloniki and <sup>2</sup>Department of Pathology, Papageorgiou Hospital, Plagiari PO Box 461, GR-57500 Thessaloniki, Greece. \*E-mail: katerinapatsatsi@gmail.com

A 75-year-old woman with a history of hydroxychloroquine-treated cutaneous lupus erythematosus presented with a bilateral sharply demarcated macular hyperpigmentation on both forearms (Fig. 1) and a partial melanonychia of the right thumb nail. This pigmentation disorder developed gradually over a 6-month period. No retinal pigmentation and no systemic disorder were revealed. Dermoscopy of the nail plate and nail bed showed pigment deposition.

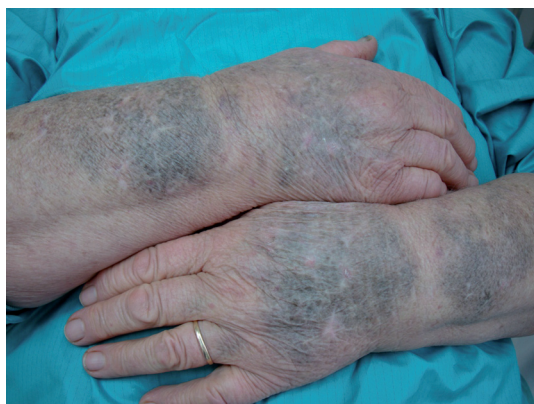

Fig. 1. Macular hyperpigmentation on both forearms and partial melanonychia of the right thumb nail.

Histological examination of a skin biopsy showed basal hyperpigmentation of the epidermis and a diffuse deposition of hemosiderin and melanin in the dermis. Abundant hemosiderin deposits were clearly indicated by iron staining (Fig. 2).

*What is your diagnosis? See next page for answer.*

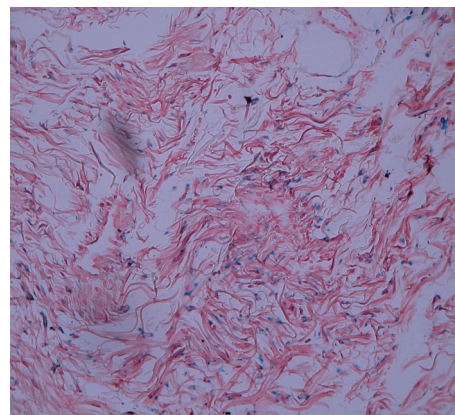


Fig. 2. Abundant hemosiderin deposits (iron stain, X40).

doi: 10.2340/00015555-0889

## ANSWERS TO QUIZ

### Hyperpigmented Forearms and Nail: Comment

*Acta Derm Venereol* 2010; 90: XX–XX (contd).

### **Diagnosis: Hydroxychloroquine-induced skin and nail pigmentation**

All of the findings were consistent with the diagnosis of a drug-induced pigmentation.

Hydroxychloroquine at a dose of 200 mg twice per day was administered 8 years previously for cutaneous lupus erythematosus. The patient was not followed up for years and she continued taking the antimalarial medication without any medical advice.

Although mucocutaneous bluish grey hyperpigmentation induced by antimalarials was first reported in 1963 by Tuffanelli et al. (1), hydroxychloroquine-induced skin pigmentation has been described in only a few papers in the recent literature (2–6). It usually presents as a macular pigmentation with symmetrical distribution on the forearms, thighs or shin. Nail involvement is extremely rare. Sun exposure does not seem to affect the site of deposition of the pigment granules, as there may be involvement of the oral mucosa (3).

In all reported cases the main histological feature was the presence of melanin and hemosiderin deposits in the dermis. The staining pattern of hydroxychloroquine-induced

hyperpigmentation of the dermis varies in different case reports. Pigment granules may be of both melanin and hemosiderin, or of hemosiderin or melanin alone (6).

Lesions are usually dose-dependent and regress slowly after cessation of the causative medication (3).

### REFERENCES

1. Tuffanelli D, Abraham RK, Dubois EI. Pigmentation from antimalarial therapy. Its possible relationship to the ocular lesions. *Arch Dermatol* 1963; 88: 419–426.
2. Amichai B, Gat A, Grunwald MH. Cutaneous hyperpigmentation during therapy with hydroxychloroquine. *J Clin Rheumatol* 2007; 13: 113.
3. Rood MJ, Vermeer MH, Huizinga TW. Hyperpigmentation of the skin due to hydroxychloroquine. *Scand J Rheumatol* 2008; 37: 158.
4. Reynaert S, Setterfield J, Black MM. Hydroxychloroquine-induced pigmentation in two patients with systemic lupus erythematosus. *J Eur Acad Dermatol Venereol* 2006; 20: 487–488.
5. Millard TP, Kirk A, Ratnavel R. Cutaneous hyperpigmentation during therapy with hydroxychloroquine. *Clin Exp Dermatol* 2004; 29: 92–93.
6. Puri PK, Lountzis NI, Tyler W, Ferringer T. Hydroxychloroquine-induced hyperpigmentation: the staining pattern. *J Cutan Pathol* 2008; 35: 1134–1137.