

Naevus Lipomatosus Cutaneus Superficialis of Hoffmann-Zurhelle with Angiokeratoma of Fordyce

Nawaf Al-Mutairi, Arun Joshi and Osama Nour-Eldin

Department of Dermatology, Farwaniya Hospital, PO Box 280, Kuwait. E-mail: nalmut@usa.net

Accepted June 22, 2005.

Sir,

Naevus lipomatosus cutaneus superficialis (NLCS) of Hoffmann-Zurhelle is a rare disorder that is characterized by groups of mature fat cells situated within the dermis (1). It is also known as pedunculated lipofibroma (2). It is a naevoid fatty growth within the papillary and reticular dermis. Two clinical types are distinguished: the classical type, consisting of multiple lesions occurring in a zonal or segmental distribution, and the solitary papule or nodule (3). We report here a patient with classical NLCS and angiokeratoma of Fordyce, partially treated with cryotherapy.

CASE REPORT

A 43-year-old man had multiple asymptomatic skin-coloured lesions on his left gluteal region for 25 years, and multiple asymptomatic dusky red vascular papules on his scrotum for the last 10 years. Both types of lesions had increased slowly in numbers and size. He had no systemic complaints. There was no history of similar lesions in the family. The patient had undergone surgical excision of some of the gluteal lesions 15 years earlier. Cutaneous examination revealed multiple, skin-coloured, soft to firm, lobulated and smooth surfaced papules and plaques on his left gluteal region, 0.5–2.0 cm in size (Fig. 1). An irregular large atrophic scar from previous surgery was present on the adjacent perianal skin. In addition, he had multiple, 2–3 mm, firm vascular papules on the scrotum (Fig. 2). Clinical diagnoses

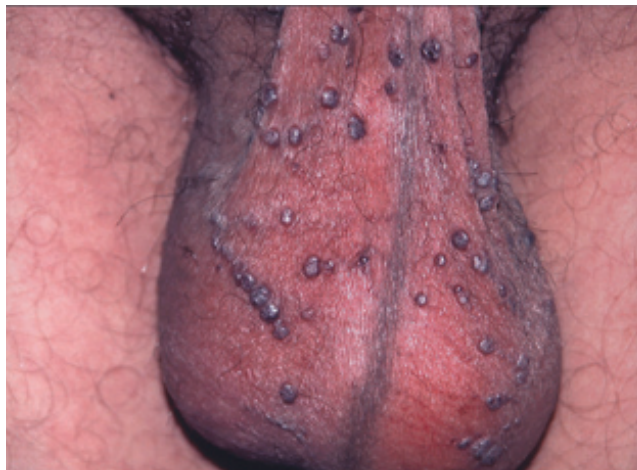

Fig. 2. Vascular papules of angiokeratoma of Fordyce on the scrotum of the same patient.

of NLCS for the gluteal lesions and angiokeratoma of Fordyce for the scrotal lesions were made. His routine baseline investigations (complete blood count, clinical chemistry, urinalysis, chest X-ray) were normal. Excision biopsy of one of the lesions on the gluteal region showed mild irregular acanthosis, and groups of fat cells embedded within the collagen bundles of the papillary, mid- and lower dermis (Fig. 3). Focal dermal perivascular mononuclear infiltrate was also noted. The findings were consistent with the diagnosis of NLCS. The patient did not consent to biopsy of the scrotal lesions and refused surgical excision or electrocautery

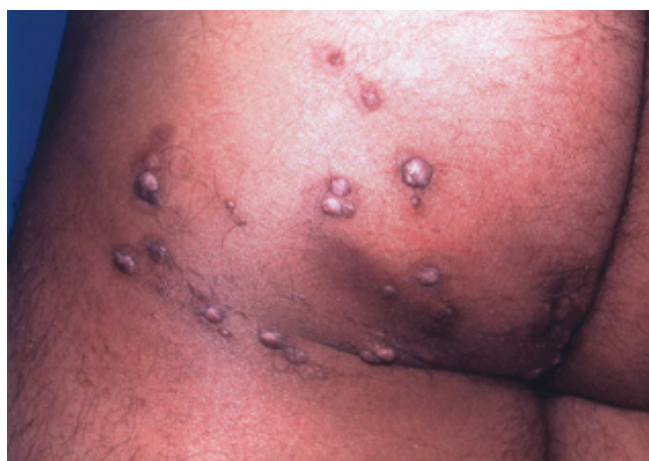

Fig. 1. Skin-coloured, soft to firm papules and plaques of naevus lipomatosus cutaneus superficialis on the left gluteal region.

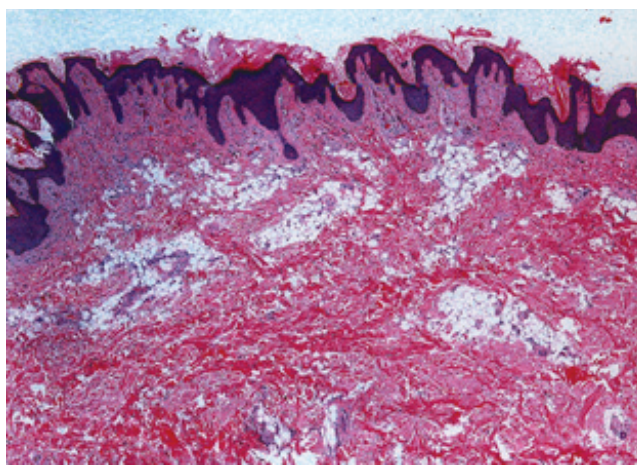


Fig. 3. Mature fat cells in the papillary, mid- and lower dermis in a lesion of naevus lipomatosus cutaneus superficialis (H&E, ×10).

for the gluteal lesions. Instead the lesions were treated with liquid nitrogen cryotherapy by spray method at 2-weeks intervals. There was considerable reduction in the size of the individual lesions after two to three sittings for each of the treated lesions. However, all the lesions could not be treated as the patient returned to his native country and was lost to follow-up. No treatment was attempted for the scrotal lesions.

DISCUSSION

NLCS can affect any part of the body; however, the lesions commonly occur in the sacral, abdominal or pelvic regions (4). Rarely lesions have been reported on sites such as face (5) and clitoris (6). There is no definite explanation for the marked predilection of the classical type of NLCS for the pelvic girdle area (5). The lesions are slowly growing, pedunculated tumours (2), and can reach a large size if left untreated (1). The largest size reported so far has been 20×30 cm (1). Segmental neurofibromatosis is an important clinical differential diagnosis of the zonal type of NLCS (7), whereas the solitary type can be difficult to distinguish from a skin tag with fatty herniation. A skin biopsy, therefore is essential to confirm the diagnosis. Our case seems to fit with the classic type of NLCS. There is marked variability in the amount of ectopic fat found in the lesions of NLCS. Associated abnormalities of the connective tissue, the vessels and the skin appendages can be found (3). Association of NLCS with connective tissue naevi (8) and haemangiomas (9) has been

reported. The treatment of choice is surgical excision; however, as our patient did not want to undergo surgery, cryotherapy of individual lesions was done with partial but satisfactory response. This patient also had scrotal angiokeratomas of Fordyce, an association of NLCS which has not been reported before.

REFERENCES

1. Knuttel R, Silver EA. A cerebriform mass on the right buttock. *Dermatol Surg* 2003; 29: 780–781.
2. Ozturkcan S, Terzioglu A, Akyol M, Altinor S, Yildiz E. Pedunculated lipofibroma. *J Dermatol* 2000; 27: 288–290.
3. Jones EW, Marks R, Pongsehirun D. Naevus superficialis lipomatosus. A clinicopathological report of twenty cases. *Br J Dermatol* 1975; 93: 121–133.
4. Bergonse FN, Cymbalista NC, Nico MM, Santi CG, Goleman B, Goleman R, et al. Giant nevus lipomatosus cutaneus superficialis: case report and review of the literature. *J Dermatol* 2000; 27: 16–19.
5. Park HJ, Park CJ, Yi JY, Kim TY, Kim CW. Nevus lipomatosus superficialis on the face. *Int J Dermatol* 1997; 36: 435–437.
6. Hattori R, Kubo T, Yano K, Tanemura A, Yamaguchi Y, Itami S, et al. Nevus lipomatosus cutaneus superficialis of the clitoris. *Dermatol Surg* 2003; 29: 1071–1072.
7. Armstrong DK, Walsh MY, Bingham A, McMillan C. Naevus lipomatosus cutaneus superficialis. *Australas J Dermatol* 1997; 38: 88–90.
8. Orteu CH, Hughes JR, Rustin MH. Naevus lipomatosus cutaneus superficialis: overlap with connective tissue naevi. *Acta Derm Venereol* 1996; 76: 243–245.
9. Hann SK, Yang DS, Lee SH. Giant nevus lipomatosus superficialis associated with cavernous hemangioma. *J Dermatol* 1988; 15: 543–545.