

CLINICAL REPORT

Cutaneous Manifestations in Patients with Microscopic Polyangiitis: Two Case Reports and a Minireview

Tamihiro KAWAKAMI¹, Yoshinao SOMA¹, Chihiro SAITO¹, Hitoshi OGAWA², Yuko NAGAHUCHI², Takahiro OKAZAKI², Shoichi OZAKI² and Masako MIZOGUCHI¹

Departments of ¹Dermatology and ²Rheumatology and Allergy, St Marianna University School of Medicine, Kawasaki, Kanagawa, Japan

Microscopic polyangiitis is a systemic small vessel vasculitis, which often has cutaneous and musculoskeletal features. Microscopic polyangiitis is a member of the family of anti-neutrophil cytoplasmic auto-antibody (ANCA)-associated vasculitides and is strongly associated with anti-myeloperoxidase (MPO)-ANCA. Titres of MPO-ANCA may reflect disease activity and play a pathogenic role. Patients with microscopic polyangiitis usually present with erythematous macules on the extremities as the first cutaneous manifestation. Skin biopsy specimens from the erythema reveal small-sized vessels that are infiltrated with neutrophils, consistent with leukocytoclastic vasculitis, in the deep dermis to the subcutaneous fat tissue. The cutaneous involvement is present at an early stage of microscopic polyangiitis with other non-specific symptoms, such as arthralgias and myalgias. The initial cutaneous manifestations are important in early diagnosis of possible ANCA-associated vasculitides with elevated ANCA titres. Key words: cutaneous manifestation; microscopic polyangiitis; anti-myeloperoxidase; auto-antibodies; ANCA-associated vasculitides.

(Accepted October 5, 2005.)

Acta Derm Venereol 2006; 86: 144–147.

Tamihiro Kawakami, MD, PhD, St. Marianna University School of Medicine, Department of Dermatology, 2-16-1 Sugao, Miyamae-ku, Kawasaki, Kanagawa 216-8511, Japan. E-mail: tami@marianna-u.ac.jp

Polyarteritis nodosa (PAN) and microscopic polyangiitis (MPA) are primary systemic necrotizing vasculitides (1, 2). PAN is a necrotizing angiitis involving medium-sized arteries that is characterized by predominant peripheral nervous system, skin, muscle, kidney and gastrointestinal tract involvement. The clinical characteristics of MPA have been clearly established by Davson et al. (3), but the disease spectrum of MPA may be broader than currently recognized. Formerly considered as a single entity, PAN and MPA were subsequently segregated by the Chapel Hill Consensus Conference (CHCC) nomenclature, in particular with regard to differences in the size of the predominantly involved vessels and clinical presentation (1). Furthermore, it was widely recognized that the presence of anti-neutrophil cytoplasmic auto-antibody (ANCA)

is helpful for diagnosing vasculitis. The underlying pathogenic mechanisms appear to be different, involving immune complexes in PAN and ANCA in MPA. MPA is defined as necrotizing vasculitis with few or no immune deposits, affecting small vessels (capillaries, arterioles or venules) in which necrotizing glomerulonephritis is very common and pulmonary capillaritis often occurs. On the other hand, PAN, according to the CHCC reclassification, is defined as medium-sized vasculitis without ANCA and is extremely rare (4).

The concept of ANCA-associated vasculitides, as a histological and clinical disease spectrum, was introduced by Jennette & Falk (5). MPA, Wegener's granulomatosis and Churg-Strauss syndrome all involve leukocytoclastic vasculitis of small-size vessels characteristically associated with ANCA, and are collectively referred to as ANCA-associated vasculitides (6). These vasculitides are thought to share a common pathogenesis that is modulated to provide distinct clinical and pathological variants. ANCA titre closely correlates with disease activity and patients who are persistently ANCA-positive during remission are prone to developing relapses (7, 8). ANCA has been recognized as a useful marker for diagnosing small vessels vasculitis and has been classified into two subsets by indirect immunofluorescent microscopy. One displays a perinuclear pattern (P-ANCA), which mainly reacts with myeloperoxidase (MPO), and the other displays a cytoplasmic staining pattern (C-ANCA). Circulating ANCA against MPO-ANCA is often used as a serological marker for ANCA-associated vasculitides, particularly in MPA (9, 10).

To exemplify the clinical features of MPA, we describe two patients with MPO-ANCA who presented with renal impairment. We found cutaneous lesions in both patients, based on small vessel vasculitis found in their skin biopsy specimens. Our patients satisfied the definition of MPA, as recently defined by the CHCC.

CASE REPORTS

Patient 1

A 76-year-old man visited our hospital complaining of general fatigue and slight fever. He presented with a 1-week history of skin lesions with slight swelling in the extremities. These lesions started as simple red papules, and their size and number had gra-

dually increased (Fig. 1A). The laboratory findings were as follows: white blood cell count of $18,300/\mu\text{l}$ (normal $4000\text{--}9000/\mu\text{l}$), red blood cell count of $3.83 \times 10^6/\mu\text{l}$ ($4.5\text{--}5.6 \times 10^6/\mu\text{l}$) and platelet count of $649 \times 10^3/\mu\text{l}$ ($180\text{--}370 \times 10^3/\mu\text{l}$). Non-specific indicators of inflammation were elevated, including erythrocyte sedimentation rate (ESR 128 mm in the first hour) and C-reactive protein (97 mg/l ; $< 12\text{ mg/l}$). Urinalysis revealed haematuria and proteinuria, with a slightly elevated serum creatinine ($121\text{ }\mu\text{mol/l}$; $50\text{--}90\text{ }\mu\text{mol/l}$). Enzyme-linked immunosorbent assay revealed that myeloperoxidase antibody (MPO-ANCA) was 358 EU and antiproteinase-3 antibody (PR3-ANCA) was negative. A skin biopsy specimen was obtained from the lower extremity erythema eruption. Microscopic examination showed mild infiltrations around the small blood vessels in the dermis. Perivascular infiltrates with neutrophils and red blood cells, intravascular hyalinized material evocative of fibrin thrombi were identified in the upper subcutaneous fat tissue, which is consistent with leukocytoclastic vasculitis. Direct IF was negative for immunoreactants and complement components. A renal biopsy specimen demonstrated a focal and segmental necrotizing glomerulonephritis with crescents.

Patient 2

A 71-year-old woman was admitted to hospital with a 5-week history of fever. She also had a 4-week history of cutaneous manifestation. The patient had had a high-grade fever that had persisted for several weeks, accompanied by a cough that developed one week before admission. The patient reported having pain and swelling in her lower extremities for approximately one month with a rapid increase in the intensity of her symptoms just prior to admission. She complained of numbness and paraesthesiae of the feet and lower legs. The erythematous macules were distributed over the legs and dorsa of the feet (Fig. 1B). Laboratory investigations demonstrated a white blood cell count of $11,700/\mu\text{l}$ reduced red blood cell count of $2.87 \times 10^6/\mu\text{l}$ ($3.8\text{--}4.8 \times 10^6/\mu\text{l}$) and platelet count of $355 \times 10^3/\mu\text{l}$. In addition, she had an ESR of 95 mm and C-reactive protein of 212 mg/l. Her serum creatinine was $93.7\text{ }\mu\text{mol/l}$ ($40\text{--}80\text{ }\mu\text{mol/l}$) with a creatinine clearance rate of 17 ml/min. Urinalysis showed haematuria, proteinuria and granular casts. The total serum protein count was 6.4 mg/dl, with albumin at 2.7 mg/dl. MPO-ANCA was positive to a titre of 130 EU; PR3-ANCA was negative.

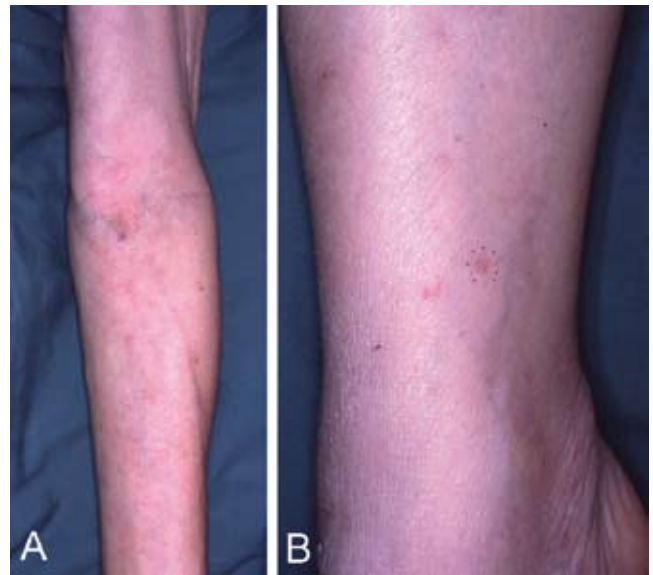


Fig. 1. (A) Left forearm of patient 1 shows erythematous macules and livedo reticularis. (B) Erythematous macules on right wrist in patient 2. The biopsy site is marked.

Chest examination showed coarse crackles on her lung. A pulmonary fibrosis with several cysts was diagnosed by lung computed tomography. She developed a sensory mononeuropathy affecting her extremities, confirmed by nerve conduction studies. Microscopic examination of the erythema on her left leg revealed a typical small-vessel leukocytoclastic vasculitis (Fig. 2A and B). Direct IF was negative.

DISCUSSION

Heightened awareness of the early manifestations of ANCA-associated vasculitides can facilitate expeditious institution of therapy, minimizing irreversible tissue destruction. The serum ANCA titre may also

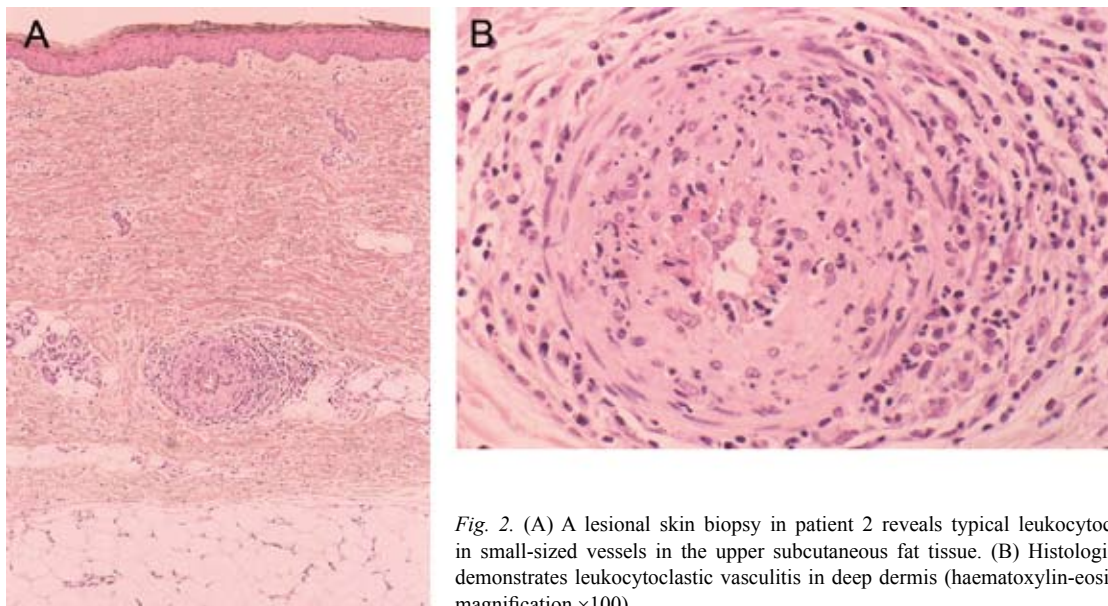


Fig. 2. (A) A lesional skin biopsy in patient 2 reveals typical leukocytoclastic vasculitis in small-sized vessels in the upper subcutaneous fat tissue. (B) Histological examination demonstrates leukocytoclastic vasculitis in deep dermis (haematoxylin-eosin stain; original magnification $\times 100$).

play an important part in disease diagnosis. However, laboratory investigations, other than measurement of ANCA, have been found to be of little diagnostic value (11). In the clinical evaluation of patients with suspected vasculitis, it is essential to obtain representative biopsy specimens to confirm the diagnosis. A diagnosis of vasculitis requires the presence of leukocytoclastic vasculitis, such as fibrinoid degeneration, nuclear dust, neutrophilic infiltration and erythrocyte extravasation. The skin lesions in patient 1 demonstrated mainly erythematous macules and livedo reticularis. These cutaneous symptoms provided a basis to start treatment earlier than previously thought.

Non-cutaneous involvement

Small vessel vasculitic changes in ANCA-associated vasculitides, including MPA, are found when any organ is biopsied. The lungs may be involved in some patients, often leading to alveolar haemorrhage, and subsequently a high rate of mortality (12–14). In patients with lung involvement, transbronchial or percutaneous biopsies often are informative regarding the presence of histopathological granulomatous vasculitis. In such cases, open lung biopsy is clearly indicated, but regularly not feasible because of the inherent risk of this procedure in vulnerable patients with debilitating disease. Therefore, longstanding lung infiltrates or cavitation are now considered to be surrogate parameters for granulomatous inflammation of the lungs (15). MPA is commonly regarded as a serious condition that places the survival of the kidneys and the patient at risk. The kidneys are always affected by focal segmental necrotizing glomerulonephritis with crescents (13). Even unselected studies show a high prevalence of serious systemic involvement (16). Renal involvement has been regarded as the initial manifestation of MPA in some studies, and therefore could reflect a recruitment bias from the internal medicine department. In the context of isolated renal lesions, the possibility of localized vasculitis, characterized by an indolent but chronic evolution that may precede systemic vasculitis must be kept in mind. Because of the segmentary nature of the vasculitis process, it is often difficult in practice to obtain representative histopathological findings in a renal biopsy.

Cutaneous involvement

We believe that the incidence and variety of cutaneous manifestations in MPA have been underestimated. Until recently, MPA has been recognized and described primarily by nephrologists, and therefore the results of studies may have been biased toward one part of the disease spectrum (12). Agard et al. (17) found skin involvement, consisting of purpura in MPA, to be the

first sign in 13% of their patients. This incidence is higher than the 4% reported by Cupps & Fauci (18). In dermatological journals, cutaneous manifestations are frequently reported, with palpable purpura occurring in 30–40% of cases (12–14). We suggest that a full awareness of the cutaneous manifestations, together with the histopathological features, can facilitate early diagnosis and the initiation of appropriate treatment.

Therapy

The standard regimen for MPA is based on a combination of corticosteroids and cyclophosphamide (19). Corticosteroids were the first applied treatment and were found to improve 5-year survival rates (20). Beneficial effects were also observed within the introduction of combined therapy with corticosteroids and cyclophosphamide, particularly in patients with severe disease. Some investigators suggested that an intermittent pulse-therapy may be as efficacious as oral cyclophosphamide at inducing remission while generating fewer side-effects (19). Our patients received oral prednisolone, and started on immunosuppressive therapy with pulse cyclophosphamide. Patient 1 led to a marked improvement in symptoms and was symptom-free within 2 months. The renal insufficiency in patient 2 remained stable, although all the cutaneous lesions disappeared immediately. Despite intensive supportive therapy, the patient died 2 months after admission.

Prognosis

Although MPA was diagnosed in patient 2 soon after hospitalization, she had a poor prognosis because it took about 1 month from cutaneous manifestation until admission which could have contributed to a poor prognosis. In patients with high ANCA titre, it is essential that sufficient cutaneous histopathological examinations are performed at an early stage. More experimental work in combination with clinical and histopathological observations is required to further understand the role of these manifestations in disease progression.

REFERENCES

1. Jennette JC, Falk RJ, Andrassy K, Bacon PA, Churg J, Gross WL, et al. Nomenclature of systemic vasculitides. Proposal of an international consensus conference. *Arthritis Rheum* 1994; 37: 187–192.
2. Savage CO, Harper L, Adu D. Primary systemic vasculitis. *Lancet* 1997; 349: 553–558.
3. Davson J, Ball J, Platt R. The kidney in periarthritis nodosa. *Q J Med* 1948; 17: 175–202.
4. Watts RA, Jolliffe VA, Carruthers DM, Lockwood M, Scott DG. Effect of classification on the incidence of polyarteritis nodosa and microscopic polyangiitis. *Arthritis Rheum* 1996; 39: 1208–1212.
5. Jennette JC, Falk RJ. Antineutrophil cytoplasmic autoanti-

- bodies and associated diseases: a review. *Am J Kidney Dis* 1990; 15: 517–529.
6. Jennette JC, Falk RJ. Small-vessel vasculitis. *N Engl J Med* 1997; 337: 1512–1523.
 7. Gaskin G, Savage CO, Ryan JJ, Jones S, Rees AJ, Lockwood CM, et al. Anti-neutrophil cytoplasmic antibodies and disease activity during long-term follow-up of 70 patients with systemic vasculitis. *Nephrol Dial Transplant* 1991; 6: 689–694.
 8. Irvine AD, Bruce IN, Walsh MY, Bingham EA. Microscopic polyangiitis. Delineation of a cutaneous-limited variant associated with antimyeloperoxidase autoantibody. *Arch Dermatol* 1997; 133: 474–477.
 9. Falk RJ, Jennette JC. Anti-neutrophil cytoplasmic autoantibodies with specificity for myeloperoxidase in patients with systemic vasculitis and idiopathic necrotizing and crescentic glomerulonephritis. *N Engl J Med* 1988; 318: 1651–1657.
 10. Yoshida M. Antineutrophil cytoplasmic antibody (ANCA) associated vasculitis: from molecular analysis to bedside. *Intern Med* 2002; 41: 47–49.
 11. Garrett PJ, Dewhurst AG, Morgan LS, Mason JC, Dathan JR. Renal disease associated with circulating antineutrophil cytoplasm activity. *Q J Med* 1992; 85: 731–749.
 12. Savage CO, Winearls CG, Evans DJ, Rees AJ, Lockwood CM. Microscopic polyarteritis: presentation, pathology and prognosis. *Q J Med* 1985; 56: 467–483.
 13. Gaskin G, Pusey C. Immunology of systemic vasculitis. *Ann Med Intern* 1992; 143: 57–62.
 14. Andrassy K, Koderisch J, Rufer M, Erb A, Waldherr R, Ritz E. Detection and clinical implication of anti-neutrophil cytoplasm antibodies in Wegener's granulomatosis and rapidly progressive glomerulonephritis. *Clin Nephrol* 1989; 32: 159–167.
 15. Sørensen SF, Slot O, Tvede N, Petersen J. A prospective study of vasculitis patients collected in a five-year period: evaluation of the Chapel Hill nomenclature. *Ann Rheum Dis* 2000; 59: 478–482.
 16. Bacon PA, Savage C, Adu D. Microscopic polyarteritis. In: Ansell BM, Bacon PA, Lie JT, Yazici H, eds. *The vasculitides: science and practice*. New York, NY: Chapman & Hall, 1996: 135–144.
 17. Agard C, Mouthon L, Mahr A, Guillevin L. Microscopic polyangiitis and polyarteritis nodosa: how and when do they start? *Arthritis Rheum* 2003; 49: 709–715.
 18. Cupps TR, Fauci AS. The vasculitides. *Major Probl Intern Med* 1981; 21: 1–211.
 19. Guillevin L, Cohen P, Mahr A, Arène JP, Mouthon L, Puéchal X, et al. Treatment of polyarteritis nodosa and microscopic polyangiitis with poor prognosis factors. *Arthritis Rheum* 2003; 49: 93–100.
 20. Langford CA. Treatment of polyarteritis nodosa, microscopic polyangiitis, and Churg-Strauss syndrome: where do we stand? *Arthritis Rheum* 2001; 44: 508–512.