

## Linear Melorheostotic Scleroderma Without Melorheostosis

Ikuko Nakajima<sup>1</sup>, Ryuhei Okuyama<sup>2\*</sup>, Hachiro Tagami<sup>2</sup>, Setsuya Aiba<sup>2</sup> and Yoko Kuramoto<sup>1</sup>

Departments of Dermatology, <sup>1</sup>Furukawa City Hospital, Furukawa, and <sup>2</sup>Tohoku University Graduate School of Medicine, Seiryō-machi 1-1, Aoba-ku, Sendai, 980-8574, Japan. \*E-mail: ryuhei@gonryo.med.tohoku.ac.jp

Accepted August 24, 2005

Sir,

Linear melorheostotic scleroderma (LMS) is a rare sclerodermatous skin change of unknown aetiology, usually associated with a hyperostotic disorder of the underlying long bones known as melorheostosis (1, 2). There are a few reports of hypertrichosis on the indurated skin in LMS (1–5). We describe here a 1-year-old Japanese girl showing linear skin sclerosis associated with hypertrichosis in the absence of bone change. This is the third reported case of LMS without melorheostosis.

### CASE REPORT

A 1-year-old girl was brought to our hospital by her parents who worried about the hardening of the skin of her right buttock and right lower extremity that started months before. An extensive linear skin hardening with a woody consistency was present on the right buttock and lateral aspect of the right thigh (Fig. 1), which was not associated with leg length discrepancy or muscle atrophy. The skin was free of inflammation or hyperpigmentation, but there was focal hypertrichosis. The involved skin was taut and unyield-

ing, but caused no limitation of motion of the right leg. The findings of laboratory evaluation including complete blood count, liver function tests, urinalysis, rheumatoid factor, antinuclear antibody, anti-scl-70 antibody, anti-centromere antibody and anti-mitochondrial antibody were all within normal limits or negative. There were no abnormalities in her bones or joints, subcutis, muscles or elsewhere on X-ray examinations and magnetic resonance imaging. Histologically, there was marked dermal thickening from prominent downward proliferation of collagen bundles (Fig. 2). Elastica-Masson stain showed normal collagen and elastic fibres. There was no epidermal or adnexal change. From the clinical and histological findings, we made a diagnosis of LMS without bone involvement.

### DISCUSSION

Melorheostosis is a rare sclerosing dysplasia wherein the affected bone demonstrates a cortical or endosteal hyperostosis, characterized roentgenographically by the appearance of dripping candle wax (6–8). Since its original description in 1922 by Leri & Joanny, more

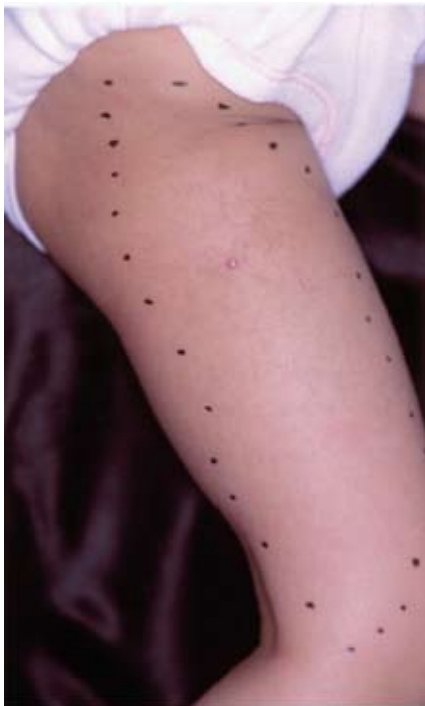

Fig. 1. An extensive linear skin lesion in right thigh and buttock.

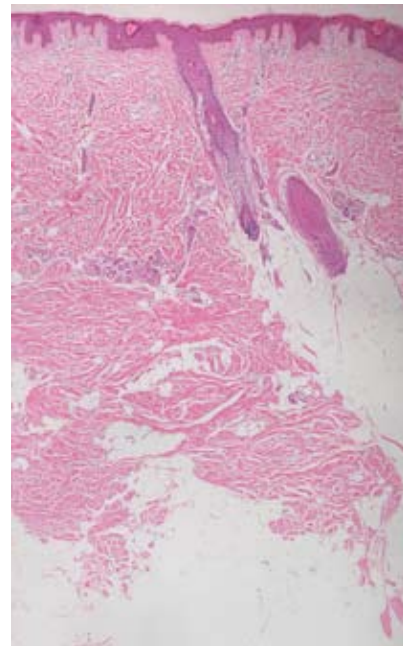


Fig. 2. Haematoxylin eosin staining of skin lesions. Increase of normal-appearing collagen bundles are apparent in the dermis and subcutaneous fat. There is no involvement of the epidermis and adnexa (×50).

than 250 cases have been reported. In 1936, Dillehunt & Chuinard (6) described a case in which a lesion defined as "linear scleroderma" was associated with melorheostosis. In one study, scleroderma-like skin changes and melorheostosis were reported to coexist in approximately 5% of 131 cases (8). In 1972, proposing a more appropriate term "linear melorheostotic scleroderma", Wagers et al. (1) described the clinical and histological features that distinguish the cutaneous changes of LMS from those of linear scleroderma. The increased collagen bundles show a normal appearance in LMS, which is distinct from the abnormal appearance noted in linear scleroderma. Namely, in scleroderma closely aggregated, coarse collagen bundles occupy the reticular dermis, together with hyalinized collagen bundles that replace the subcutaneous fat (9). Furthermore, the skin appendages are normal in LMS while they are atrophic in linear scleroderma. In addition, hypertrichosis does not usually occur in linear scleroderma. In the case described here, the clinical and histological features are highly suggestive of LMS, allowing us to make this diagnosis even though bone lesions were not found. Moreover, we excluded the possibility of eosinophilic fasciitis on the basis of the lack of eosinophilic infiltrate in the skin lesion or eosinophilia in the peripheral blood. Most of all, the latter condition is rare at this age.

The pathogenesis of LMS is unknown. Wagers et al. (1) proposed the possibility that the skin lesions were similar to the bone lesions in terms of the pathomechanism. As for its pathogenesis, inflammation (8) and vascular abnormality (10) have been proposed. Muller & Henderson (11) postulated that the sclerosing changes in the skin of LMS should be derived from a primary mesenchymal defect that occasionally spills over into the skeletal tissues. However, many others favour the notion of a common developmental error both in the cutaneous and skeletal lesions (2, 11, 12). Fimiani et al. (4) suggested the possibility that LMS is an integral part of a hamartoma that may affect one or more tissues, which was supported by the coexistence of hypertrichosis with LMS, as noted in the present case. Hypertrichosis in LMS lesions is infrequent, but has been reported in five cases (1–5).

Two cases of LMS without melorheostosis as seen in the present case have been reported (4, 5). There are three possible explanations for LMS that are not

accompanied by bone alteration (4). First, there may be a difference in the onset of the pathogenic changes between the skin and bone. In fact, in a few previous cases melorheostosis became evident only several years after the appearance of the skin lesion. Secondly, it is possible that some cases of LMS without melorheostosis have been diagnosed as linear scleroderma. Thirdly, available instruments may overlook slight bone alterations in the early stage of melorheostosis. Although bone scintigraphy is often available to detect slight bone alterations (2, 13), the parents of the present patient refused further study. No prophylaxis or therapy is effective to prevent the progression of melorheostosis, but we are closely following this patient.

## REFERENCES

1. Wagers LT, Young AW Jr, Ryan SF. Linear melorheostotic scleroderma. *Br J Dermatol* 1972; 86: 297–301.
2. Miyachi Y, Horio T, Yamada A, Ueo T. Linear melorheostotic scleroderma with hypertrichosis. *Arch Dermatol* 1979; 115: 1233–1234.
3. Moreno Alvarez MJ, Lazaro MA, Espada G, Barcelo HA, Maldonado Cocco A. Linear scleroderma and melorheostosis: case presentation and literature review. *Clin Rheumatol* 1996; 15: 389–393.
4. Fimiani M, Rubegni P, De Aloe G, Andreassi L. Linear melorheostotic scleroderma with hypertrichosis sine melorheostosis. *Br J Dermatol* 1999; 141: 771–772.
5. Juhn BJ, Cho YH, Lee MH. Linear scleroderma associated with hypertrichosis in the absence of melorheostosis. *Acta Derm Venereol* 2000; 80: 62–63.
6. Dillehunt RB, Chuinard EG. Melorheostosis Leri. *J Bone Joint Surg* 1936; 18: 991–996.
7. Campbell CS. Melorheostosis of the upper limb; report of a case. *J Bone Joint Surg Br* 1955; 37-B: 471–473.
8. Morris JM, Samilson RL, Corley CL. Melorheostosis. Review of the literature and report of an interesting case with a nineteen-year follow-up. *J Bone Joint Surg Am* 1963; 45: 1191–1206.
9. Eubanks LE, McBurney EI, Galen W, Reed R. Linear scleroderma in children. *Int J Dermatol* 1996; 35: 330–336.
10. Campbell CJ, Papademetriou T, Bonfiglio M. Melorheostosis. A report of the clinical, roentgenographic, and pathological findings in fourteen cases. *J Bone Joint Surg Am* 1968; 50: 1281–1304.
11. Muller SA, Henderson ED. Melorheostosis with linear scleroderma. *Arch Dermatol* 1963; 88: 142–145.
12. Soffa DJ, Sire DJ, Dodson JH. Melorheostosis with linear sclerodermatous skin changes. *Radiology* 1975; 114: 577–578.
13. Siegel A, Williams H. Linear scleroderma and melorheostosis. *Br J Radiol* 1992; 65: 266–268.