

CLINICAL REPORT

A Fatal Case of Malignant Atrophic Papulosis (Degos' Disease) in a Man with Factor V Leiden Mutation and Lupus Anticoagulant

Thomas HOHWY¹, Martin GLÜMER JENSEN², Anders TØTTRUP², Torben STEINICHE³ and Karsten FOGH¹
¹Department of Dermatology, ²Surgery and ³Pathology, Aarhus University Hospital, Denmark

Malignant atrophic papulosis (Degos' disease) is a very rare condition characterized by atrophic papular skin lesions and variable association of systemic involvement. We describe a 33-year-old man who presented with a widespread skin eruption consistent with malignant atrophic papulosis. During the course of the disease he even developed penile ulcerations, a symptom that has been reported only a few times previously. He subsequently died of multiple perforations of the small bowel 2.5 years after onset of the disease. Laboratory investigations revealed a mutation of factor V Leiden and the presence of lupus anticoagulant, but no anti-cardiolipin antibodies. The patient was treated with narrow-band ultraviolet (UV)B, prednisolone and, later, aspirin, pentoxifyllin and warfarin. Despite this very intensive anticoagulant and anti-platelet therapy, the treatment had no effect on the skin lesions and could not prevent systemic involvement. Key words: malignant atrophic papulosis; intestinal involvement; fatal outcome; Köhlmeier; Degos.

(Accepted December 12, 2005)

Acta Derm Venereol 2006; 86: 245–247.

Thomas Hohwy, Department of Dermatology, Aarhus University Hospital, P. P. Oerumsgade 11, DK-8000 Aarhus C, Denmark. E-mail: thomashohwy@hotmail.com

Malignant atrophic papulosis (Degos' disease) is an extremely rare disease with only approximately 150 cases reported in the international literature. Köhlmeier (1) reported the first case in 1941 and a year later Degos et al. (2) reported another case as a distinctive entity. It is a frequently fatal occlusive vasculopathy of unknown aetiology. It affects mainly the skin, gastrointestinal tract and central nervous system. There is a 3:1 male predominance (3) and onset is usually in the second through fourth decade (4). The skin lesions are asymptomatic and begin as pink dome-shaped papules, which subsequently turn into umbilicated atrophic porcelain-white lesions with a peripheral teleangiectatic rim. Most patients have approximately 30 lesions, although some may develop more than 100. They can develop at any site, although the face, palms and soles are usually spared. In approximately 50% of cases histologically identical lesions involve the gastrointestinal submucosa, often resulting in bowel perforation and peritonitis, making this the most common cause of death from Degos' disease. Cerebral vessels are

involved in 20% of cases (5), leading to haemorrhagic or ischaemic stroke. Post-mortem studies have revealed involvement of many organs, including kidney, pleura, pericardium, lung and eye (6). When systemic involvement occurs the disease is usually fatal within 3 years of the onset of systemic disease (3). We describe here a patient who died of multiple small bowel perforations 2 years and 6 months after onset of a widespread cutaneous eruption with pathognomonic skin lesions.

CASE REPORT

A 31-year-old man presented with a 6-month history of an asymptomatic rash on the limbs and trunk (Fig. 1). It consisted of multiple atrophic porcelain-white scars surrounded by a slightly raised erythematous telangiectatic rim (Fig. 2). He was otherwise systemically well and in good health. He had no significant medical or family history and was not taking any medications. Physical examination was otherwise without pathological findings and the mucous membranes were not involved. Thorough neurological examination was

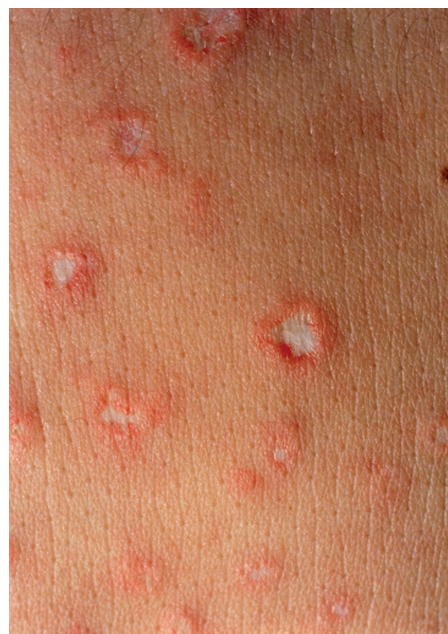

Fig. 1. Typical skin lesion of Degos' disease with an umbilicated atrophic porcelain-white centre and a rim of erythema.

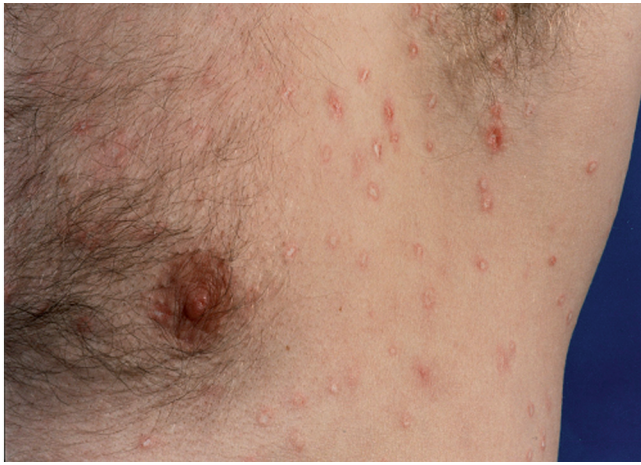

Fig. 2. Typical skin lesions occurring all over the body.

also without pathological findings. Laboratory data showed the presence of lupus anticoagulant and a mutation in the factor V gene (factor V Leiden). Basic coagulation parameters (prothrombin time, activated partial thromboplastin time, D-dimer, anti-thrombin, plasma fibrinogen and platelets) were within the normal range. The following examinations showed normal or negative findings: full blood count, electrolytes, liver and renal function tests, glucose, C-reactive protein, antinuclear antibodies, rheumatoid factor, Wassermann reaction, procollagen N-terminal propeptide, serum immunoglobulins, chest X-ray, CT-scan of the brain and ultrasound of the abdomen. Initially, before the diagnosis of Degos' disease was made, he was treated with narrow-band ultraviolet (UV) B in all 26 treatments with no effect. He was then treated with 15 mg of prednisolone per day and 7 days later he was admitted to the hospital with acute abdominal pain. He underwent surgery and a small perforation of the small bowel was found. The involved part of the small bowel was resected and the appendix was removed. He recovered quickly from surgery and the treatment was altered to aspirin 100 mg daily, pentoxifyllin 400 mg 3 times daily and warfarin. He remained well for 6 months after surgery. The cutaneous eruption remained stable except from development of ulcerating papules on the penis. These papules later became infected, and were treated successfully with systemic antibiotics. He then began to complain of fatigue and experienced weight loss of 15 kg over a period of 2 months. He was admitted due to abdominal pain. He underwent surgery and the entire bowel was found to be affected by vasculitis, particularly the small bowel. Ileo-caecal resection was performed due to a perforation of the caecum. Histological examination of sections from the bowel showed full-thickness ischaemic necrosis of the small intestinal wall, with dilatation of several layers of the vessel walls, and in a few vessels small thrombotic occlusions were noticed (Fig.

3). Whether these occlusions were the primary events or secondary to the necrotic ulcerations could not be determined.

Three days later he developed increasing abdominal pain and signs of septicaemia, and during yet another operation, a perforation of the small bowel was found and treated surgically. The condition of the patient was rapidly deteriorating, and a second-look operation revealed massive ischaemic changes in both the colon and the small bowel together with peritonitis and widespread vasculitic elements. Further therapeutic measures were in vain, and the patient died after 24 h. Autopsy was not performed.

DISCUSSION

The diagnosis was made primarily by clinical appearance. Our patient had more than a hundred lesions on the skin including ulcerations of the penis. Penile ulceration in Degos' disease has been described only a few times previously (7). The only abnormal laboratory finding in this case was the presence of lupus anticoagulant and a mutation in the factor V gene (factor V Leiden). To our knowledge this is the first case of Degos' disease with a mutation in factor V Leiden, but the prevalence of a mutation in coagulation factor V Leiden is approximately 7% in the local community, so this observation could be a random finding. Therefore the relevance of this finding remains uncertain. Individual patients can exhibit a variety of coagulation abnormalities, although these findings are inconsistent. In one published series of 15 cases, 4 patients had raised serum fibrinogen levels, 3 had a prolonged euglobulin lysis time, and 1 had increased platelet adhesiveness (8). Anti-cardiolipin antibodies have been shown in other cases (4). We found presence of lupus anticoagulant in our patient. Anti-phospholipid antibodies (cardiolipin antibodies, β 12-glycoprotein I and lupus anticoagulant) are present with a higher prevalence in autoimmune

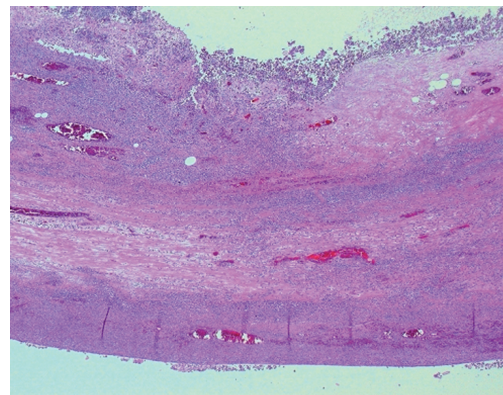


Fig. 3. Histological section from the bowel, showing full-thickness ischaemic necrosis of the small intestinal wall, with dilatation of several layers of the vessel walls and, in a few vessels, small thrombotic occlusions.

disorders, and is often seen in acute illness. In this case, the presence of lupus anticoagulant might be secondary to the disease or represent yet another random finding of unknown clinical significance. Based on the current knowledge, it is most likely that Degos' disease represents a heterogeneous group of disorders.

There is no effective treatment for Degos' disease. The combination of aspirin and pentoxifyllin 400 mg 3 times a day was reported to be beneficial in one case (9), but in our case this treatment did not result in any improvement. Our patient developed his first bowel perforation after 7 days on prednisolone, which raises the question of whether this drug precipitated the perforation. However, this seems unlikely in light of the short duration of treatment and the relatively low dosage of prednisolone given. One report indicates worsening of the skin lesions during immunosuppression with prednisolone, azathioprine and cyclosporine (10), but in another case cyclosporine treatment seemed to be beneficial on the skin lesions (7).

The aetiology of the disease remains unclear. An underlying abnormality of coagulation function has been postulated, and various abnormalities have been found, as mentioned above. However, the clinical response to anticoagulants and anti-platelet therapy has proven variable. One author states that thrombosis is likely to be a secondary event and anti-thrombotic treatment might only slow the natural progression of the disease (7). In our case intensive anticoagulant and anti-platelet therapy had no effect on the skin lesions and could not prevent systemic involvement. In this respect, it is also worth noting that we found no signs of haemorrhage clinically or on histological examinations, despite intensive anticoagulant therapy. This case illustrates the previously described course of Degos' disease with

the typical cutaneous lesions preceding systemic involvement and death from intestinal perforation. More research is needed to determine the aetiology of the disease and the possible association with coagulation abnormalities, and further research is needed to find better treatment options.

REFERENCES

1. Köhlmeier W. Multiple Hautnekrosen bei Thrombangiitis obliterans. *Arch Dermatol Syphilol* 1941; 181: 783–792.
2. Degos R, Delort J, Tricot R. Dermite papulosquameuse atrophiante. *Bull Soc Fr Dermatol Syphiligr* 1942; 49: 148–150.
3. Valverde FMG, Pina FM, Ruiz JA, Ramos MJG, Barbera FM, Prieto PL, et al. Presentation of Degos syndrome as acute small-bowel perforation. *Arch Surg* 2003; 138: 57–58.
4. Borgenrieder T, Kuske M, Landthaler M, Stolz W. Benign Degos' disease developing during pregnancy and followed for 10 years. *Acta Derm Venereol* 2002; 82: 284–287.
5. Petit WA, Soso MJ, Higman HH. Degos' disease: neurologic complications and cerebral angiography. *Neurology* 1982; 32: 1305–1309.
6. Howsden SM, Hodge SJ, Herndon JH, Freeman RG. Malignant atrophic papulosis of Degos. *Arch Dermatol* 1976; 112: 1582–1588.
7. Thomsen KF, Highet AS. Penile ulceration in fatal malignant atrophic papulosis. *Br J Dermatol* 2000; 143: 1320.
8. Assier H, Chosidow O, Piette JC, Boffa MC, Youinou P, Thomas L, et al. Absence of antiphospholipid and anti-endothelial cell antibodies in malignant atrophic papulosis: a study of 15 cases. *J Am Acad Dermatol* 1995; 33: 831–833.
9. Victor C, Schultz-Ehrenburg U. Malignant atrophic papulosis: diagnosis, therapy and course. *Hautartz* 2001; 52: 734–737.
10. Powell J, Bordea C, Wojnarowska F, Farrell AM, Morris PJ. Benign familial Degos' disease worsening during immunosuppression. *Br J Dermatol* 1999; 141: 524–527.