

Multiple Panniculitis Caused by *Actinobacillus* and *Actinomyces* Infection

Esben Techau Jørgensen

Department of Dermatology, Länssjukhuset, SE-391 85 Kalmar, Sweden. E-mail: esbenj@ltkalmars.se

Accepted April 18, 2006.

Sir,

Actinobacillus actinomycetemcomitans and *Actinomyces* spp. are commensal in the human mouth. They are in combination a rare cause of a variety of infections such as odontological infections, pneumonia, endocarditis, severe eye infection, and have been reported in traumatic skin ulcers (1–4). Multiple lesions of the skin caused by *Actinobacillus* and *Actinomyces* in combination without internal foci, has to the best of my knowledge not been described in the literature.

CASE REPORT

A 54-year-old woman, a smoker since 13 years of age and treated for chronic obstructive lung disease with budesonide and terbutaline, developed pneumonia-like symptoms after a dental extraction in December 2003; this was successfully treated with doxycycline.

In January 2004, the patient started to develop disseminated cutaneous infiltrates on a toe, the dorsum of one hand, arms, thighs, abdomen, neck and over one heel, a total of 11 lesions. The lesions started with a red, warm infiltrate (Fig. 1), later to become ulcerated leaving 3–5 cm diameter oozing ulcerations (Fig. 2)

The patient received treatment with clindamycin for 4 weeks with no effect. X-ray of the lungs and heart was normal. A skeletal scintigram showed no abnormalities. Bacterial swabs from ulcers were repeatedly negative. The sedimentation rate was 40 mm/h.

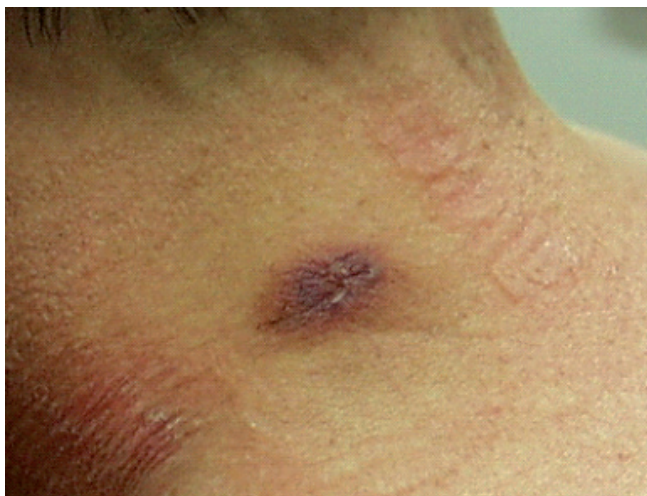

Fig. 1. New infiltrate on the back of the neck.

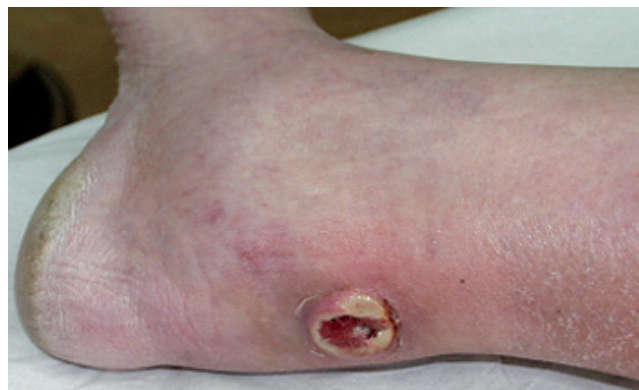

Fig. 2. Two-week-old infiltrate on the heel.

On referral to our clinic on 26 February 2004, 3 new lesions had developed within the last week. A biopsy was taken from a lesion on the thigh. This showed an intense inflammatory process with panniculitis and a congregation of *Actinomyces*-like bacterial structures in the infiltrate (Fig. 3).

On 28 April 2004 the patient was referred to the department of infectious disease, with the question as to whether this could be disseminated actinomycosis. After ruling out this possibility, the patient was referred to the department of rheumatology. On suspicion of idiopathic panniculitis the patient was treated with prednisone

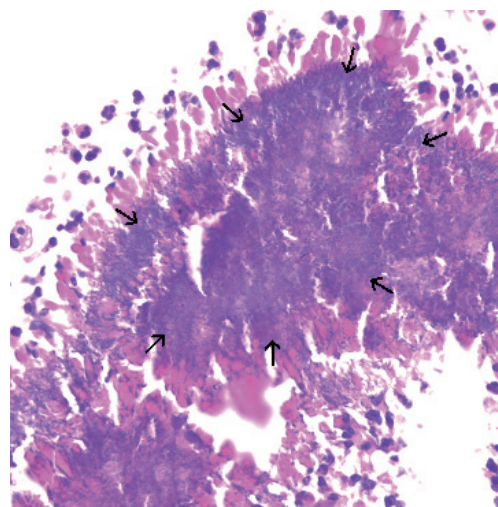


Fig. 3. Biopsy showing *Actinomyces*-like structures (arrows) in haematoxylin-eosin (H&E) stain.

40 mg/day and later with colchicine, also without effect. The patient was at the same time given penicillin, on suspicion of actinomycosis; this had no effect on the lesions, but was continued for 2 months anyway.

On 10 June 2004, the patient was referred back to our clinic, and a sample taken using an anaerobic technique from a new lesion revealed *A. actinomycetemcomitans*. The strain was resistant to penicillin, but sensitive to ciprofloxacin. The patient was prescribed ciprofloxacin 500 mg twice daily. The lesions in the skin immediately started to improve, and the ulcerations healed as expected. After 4 weeks all lesions were cleared. B-neutrophils had fallen from 12.8 to 3.5 $10^9/l$ (ref 1.80–6.7 10^9), P-CRP had fallen from 66 mg/l to 6 mg/l (normal < 5 mg/l). The treatment with ciprofloxacin was stopped, and the patient has been free of lesion since, 18 months after the last treatment.

DISCUSSION

Repeated attempts to isolate *Actinomyces* failed in this patient, despite prolonged culture for 3 weeks in anaerobic conditions. This is not uncommon. Efforts were made to try to demonstrate *Actinobacillus* in the biopsy material, but this was not possible; no other

infiltrate than that first identified was found in the biopsy material. *A. actinomycetemcomitans* is a small Gram-negative rod and was not possible to identify in the biopsy material when it was reinvestigated after the bacteria had been identified in culture. Although only *Actinomyces*-like organisms were seen in the biopsy, the lack of response to penicillin and the immediate response to ciprofloxacin suggests that the main cause of disease in this case is the isolated strain of *A. actinomycetemcomitans*, perhaps in combination with the unidentified *Actinomyces* species.

REFERENCES

1. Binder MI, Chua J, Kaiser PK, Mehta N, Isada CM. *Actinobacillus actinomycetemcomitans* Endogenous Endophthalmitis. *Scan J Infect Dis* 2003; 35: 133–136.
2. Dommann SN, Widmer M, Dommann-Scherrer C, Bernasconi E, Burg G. *Actinobacillus actinomycetemcomitans* isolated from a mycetoma of the forearm. *Hautarzt* 1994; 45: 402–405.
3. Kuijper EJ, Wiggerts HO, Jonker GJ, Schaal KP, de Gans J. Disseminated actinomycosis due to *Actinomyces meyeri* and *Actinobacillus actinomycetemcomitans*. *Scand J Infect Dis* 1992; 24: 667–672.
4. Brown JR. Human actinomycosis. A study of 181 subjects. *Hum Pathol* 1973; 4: 319–330.